Chapter 07
Lecture Outline

See separate PowerPoint slides for all figures and tables pre-inserted into PowerPoint without notes.

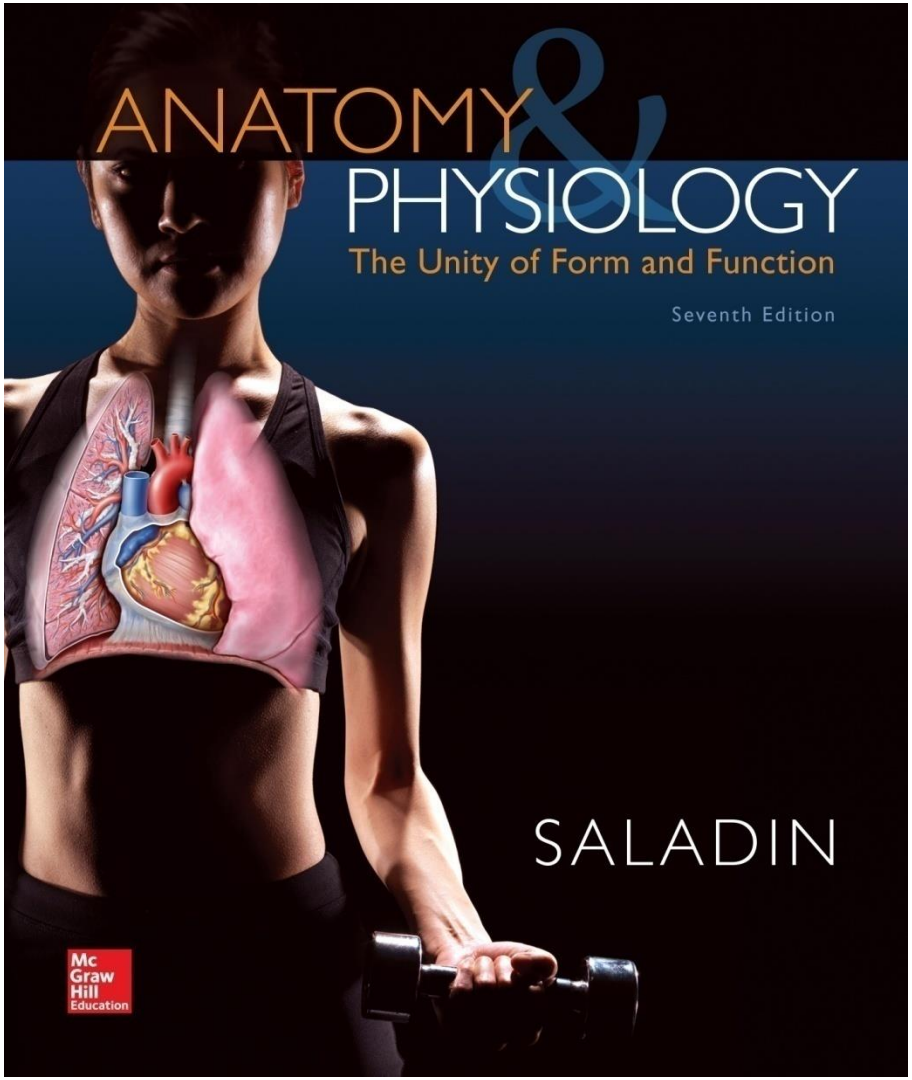

Introduction

- **In this chapter we will cover:**
  - Bone tissue composition
  - How bone functions, develops, and grows
  - How bone metabolism is regulated and some of its disorders

Introduction

- **Bones and teeth are the most durable remains of a once-living body**
- **Living skeleton is made of dynamic tissues, full of cells, permeated with nerves and blood vessels**
- **Continually remodels itself and interacts with other organ systems of the body**
- **Osteology** is the study of bone

Tissues and Organs of the Skeletal System

- **Expected Learning Outcomes**
  - Name the tissues and organs that compose the skeletal system.
  - State several functions of the skeletal system.
  - Distinguish between bones as a tissue and as an organ.
  - Describe the four types of bones classified by shape.
  - Describe the general features of a long bone and a flat bone.

Tissues and Organs of the Skeletal System

- **Skeletal system**—composed of bones, cartilages, and ligaments
  - **Cartilage**—forerunner of most bones
    - Covers many joint surfaces of mature bone
  - **Ligaments**—hold bones together at joints
  - **Tendons**—attach muscle to bone

Functions of the Skeleton

- **Support**—limb bones and vertebrae support body; jaw bones support teeth; some bones support viscera
- **Protection**—of brain, spinal cord, heart, lungs, and more
- **Movement**—limb movements, breathing, and other movements depend on bone
- **Electrolyte balance**—calcium and phosphate levels
- **Acid–base balance**—buffers blood against large pH changes by altering phosphate and carbonate salt levels
- **Blood formation**—red bone marrow is the chief producer of blood cells

Bones and Osseous Tissue

- **Bone (osseous tissue)**—connective tissue with the matrix hardened by calcium phosphate and other minerals
- **Mineralization** or **calcification**—the hardening process of bone
- **Individual bones (organs) consist of bone tissue, bone marrow, cartilage, adipose tissue, nervous tissue, and fibrous connective tissue**

General Features of Bones

- **Flat bones**
  - Thin, curved plates
  - Protect soft organs
- **Long bones**
  - Longer than wide
  - Rigid levers acted upon by muscles; crucial for movement
- **Short bones**
  - Approximately equal in length and width
  - Glide across one another in multiple directions
- **Irregular bones**
  - Elaborate shapes that do not fit into other categories

General Features of Bones

- **Compact bone**—dense outer shell of bone
- **Spongy (cancellous) bone**—loosely organized bone tissue
  - Found in center of ends and center of shafts of long bones and in middle of nearly all others
  - Covered by more durable compact bone
- **Skeleton three-fourths compact and one-fourth spongy bone by weight**
- **Long bone features**
  - **Diaphysis**—shaft that provides leverage
    - **Medullary cavity (marrow cavity)**—space in the diaphysis of a long bone that contains bone marrow
  - **Epiphyses**—enlarged ends of a long bone
    - Strengthen joint and anchor ligaments and tendons

General Features of Bones

- **Articular cartilage**—layer of hyaline cartilage that covers joint surface; allows joint to move more freely
- **Nutrient foramina**—minute holes in bone surface that allows blood vessels to penetrate
- **Periosteum**—external sheath covering most of bone
  - **Outer fibrous layer** of collagen
    - Some fibers continuous with tendons
    - **Perforating fibers**—penetrate into bone matrix
  - **Inner osteogenic layer** of bone-forming cells
    - Important to bone growth and healing of fractures
- **Endosteum**—thin layer of reticular connective tissue lining marrow cavity
  - Has cells that dissolve osseous tissue and others that deposit it

General Features of Bones

- **Epiphyseal plate (growth plate)**—area of **hyaline cartilage** that separates epiphyses and diaphyses of children's bones
  - Enables growth in length
  - **Epiphyseal line—**in adults, a bony scar that marks where growth plate used to be

General Features of Bones

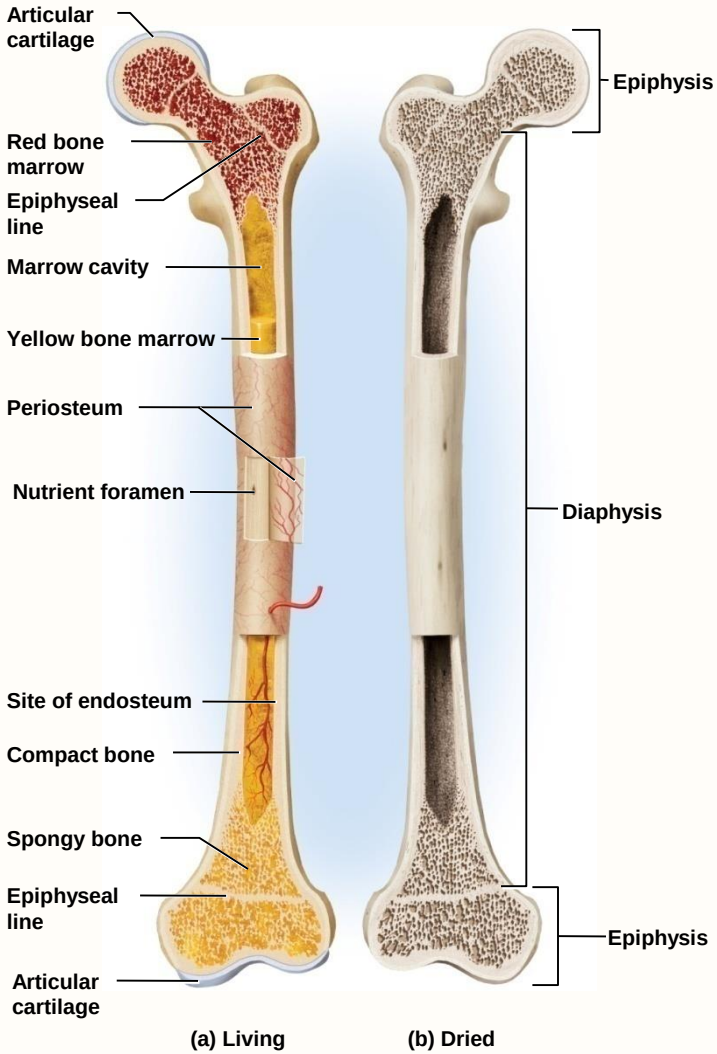

Figure 7.1

- **Long bone**
- **Epiphyses and diaphysis**
- **Compact and spongy bone**
- **Marrow cavity**
- **Articular cartilage**
- **Periosteum**

General Features of Bones

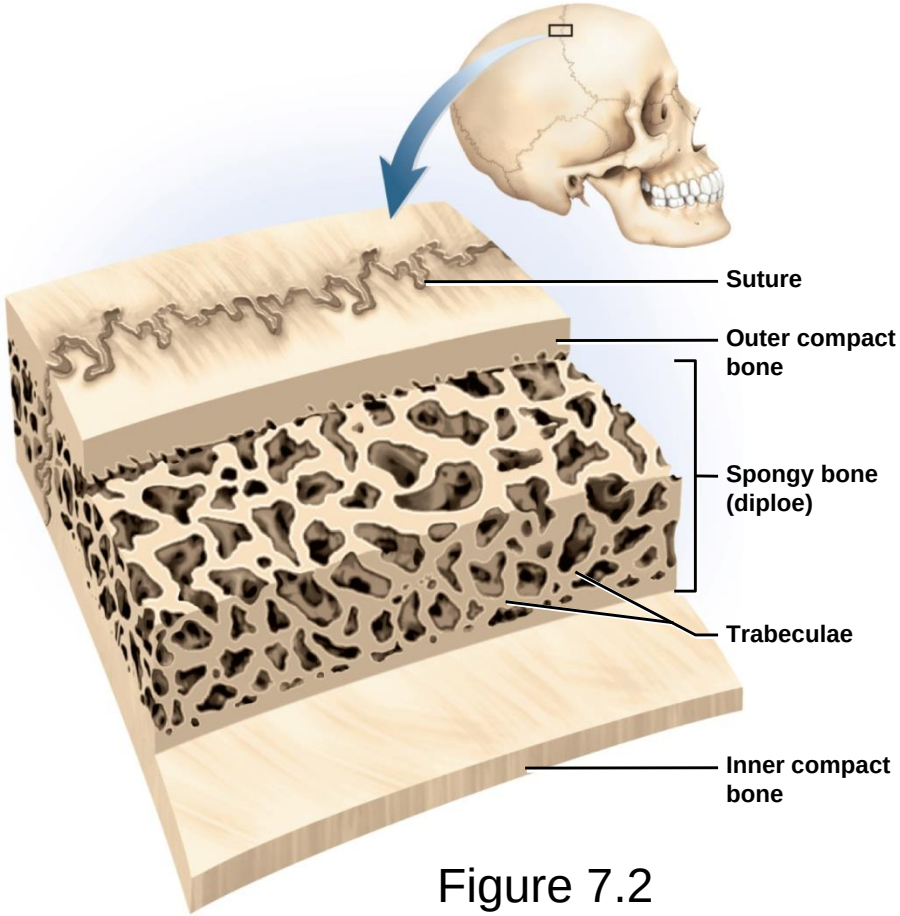

Figure 7.2

- **Flat bone**
- **Sandwich-like construction**
- **Two layers of compact bone enclosing a middle layer of spongy bone**
  - Both surfaces covered with periosteum
- **Diploe**—spongy middle layer
  - Absorbs shock
  - Marrow spaces lined with endosteum

Histology of Osseous Tissue

- **Expected Learning Outcomes**
  - List and describe the cells, fibers, and ground substance of bone tissue.
  - State the importance of each constituent of bone tissue.
  - Compare the histology of the two types of bone tissue.
  - Distinguish between the two types of bone marrow.

Bone Cells

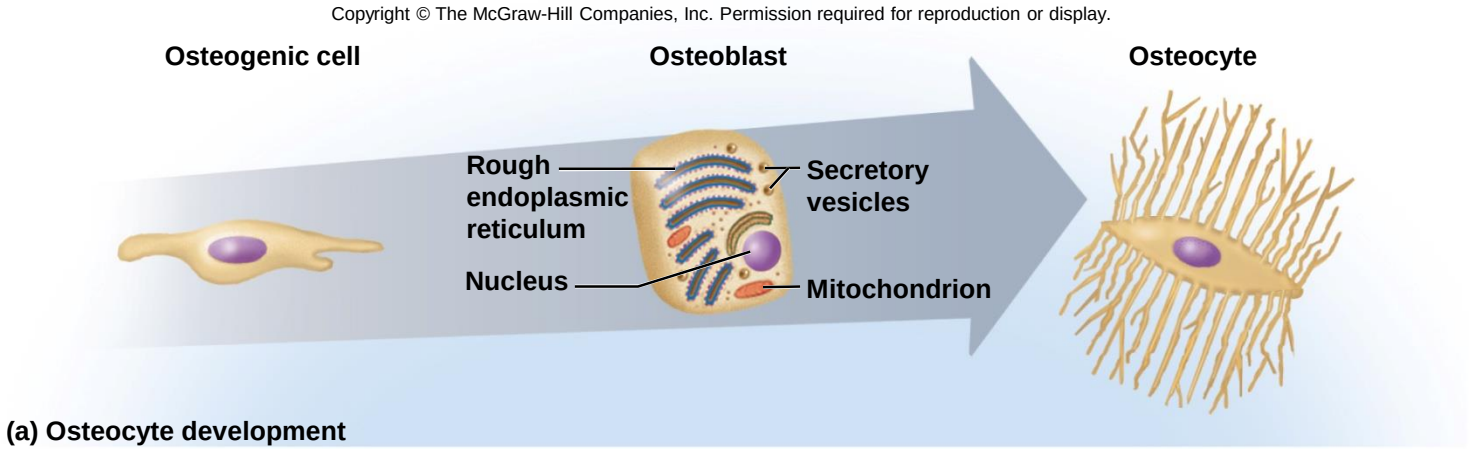

Figure 7.3a

- **Bone** is connective tissue that consists of cells, fibers, and ground substance

- **Four principal types** of bone cells
  - **Osteogenic cells; osteoblasts; osteocytes; osteoclasts**

Bone Cells

- **Osteogenic cells**—stem cells found in endosteum and inner layer of periosteum
  - Arise from embryonic mesenchymal cells
  - Multiply continuously and give rise to most other bone cell types
- **Osteoblasts**—bone-forming cells
  - Form single layer of cells under endosteum and periosteum
  - Nonmitotic
  - Synthesize soft organic matter of matrix which then hardens by mineral deposition
  - Stress stimulates osteogenic cells to multiply rapidly and increase the number of osteoblasts which reinforce bone
  - Secrete hormone **osteocalcin**
    - Stimulates insulin secretion of pancreas
    - Increases insulin sensitivity in adipocytes which limits the growth of adipose tissue

Bone Cells

- **Osteocytes**—former osteoblasts that have become trapped in the matrix they deposited
  - **Lacunae—**tiny cavities where osteocytes reside
  - **Canaliculi—**little channels that connect lacunae
  - Cytoplasmic processes of osteocytes reach into canaliculi and contact processes of neighboring cells
    - Gap junctions allow for passage of nutrients, wastes, signals
  - Some osteocytes reabsorb bone matrix while others deposit it
  - Act as strain sensors—when stressed, produce biochemical signals that regulate bone remodeling (shape and density changes that are adaptive)

Bone Cells

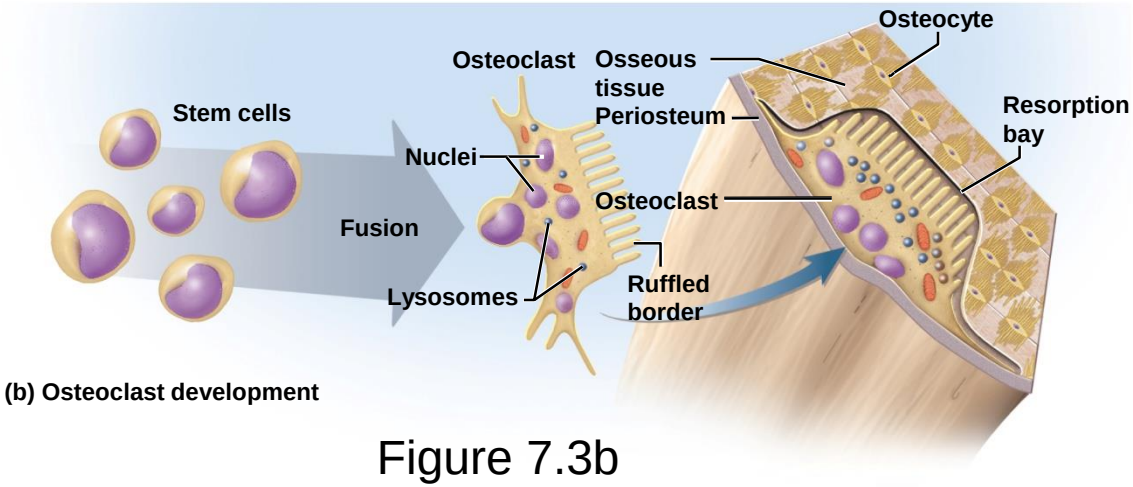

Figure 7.3b

- **Osteoclasts**—bone-dissolving cells found on bone surface
  - Osteoclasts develop from same bone marrow stem cells that give rise to blood cells (different origin from other bone cells)
  - Very large cells formed from fusion of several stem cells
    - Have multiple nuclei in each cell
  - **Ruffled border** (large surface area) faces bone
  - Cells often reside in **resorption bays** (pits in bone surface)
  - Dissolving bone is part of bone remodeling

The Matrix

- **Matrix of osseous tissue** is, by dry weight, about one-third organic and two-thirds inorganic matter
- **Organic matter**—synthesized by osteoblasts
  - Collagen, carbohydrate–protein complexes, such as glycosaminoglycans, proteoglycans, and glycoproteins
- **Inorganic matter**
  - 85% hydroxyapatite (crystallized calcium phosphate salt)
  - 10% calcium carbonate
  - Other minerals (fluoride, sodium, potassium, magnesium)

The Matrix

- Bone is a **composite material**—a combination of a ceramic and a polymer
  - Hydroxyapatite and other minerals are the ceramic and collagen (protein) is the polymer
  - Ceramic portion allows the bone to support body weight without sagging
    - Rickets is a disease caused by mineral deficiency and resulting in soft, deformed bones
  - Polymer (protein) gives some flexibility
    - Osteogenesis imperfecta (brittle bone disease) results from a defect in collagen deposition

Histology of Osseous Tissue

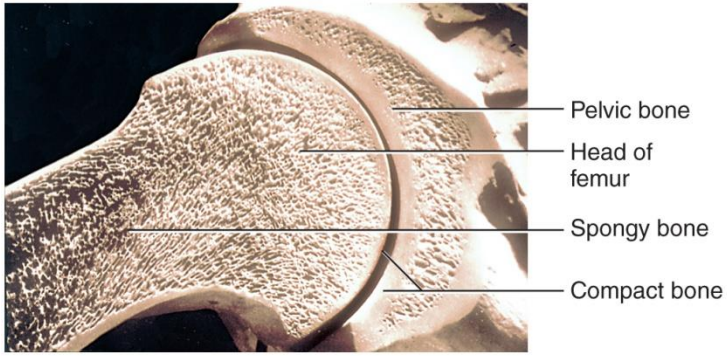

(a)

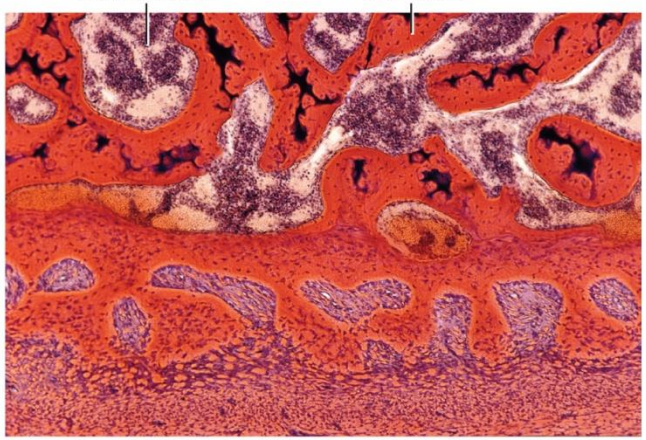

(c)

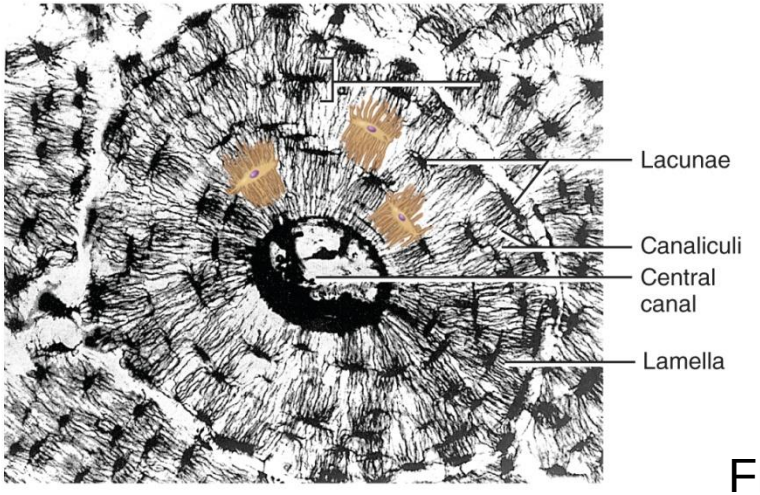

(d)

Figure 7.4a,c,d

a: ©D.W. Fawcett/Visuals Unlimited; c: ©Science VU/Visuals Unlimited; d: ©Donald Fawcett/Visuals Unlimited

Compact bone

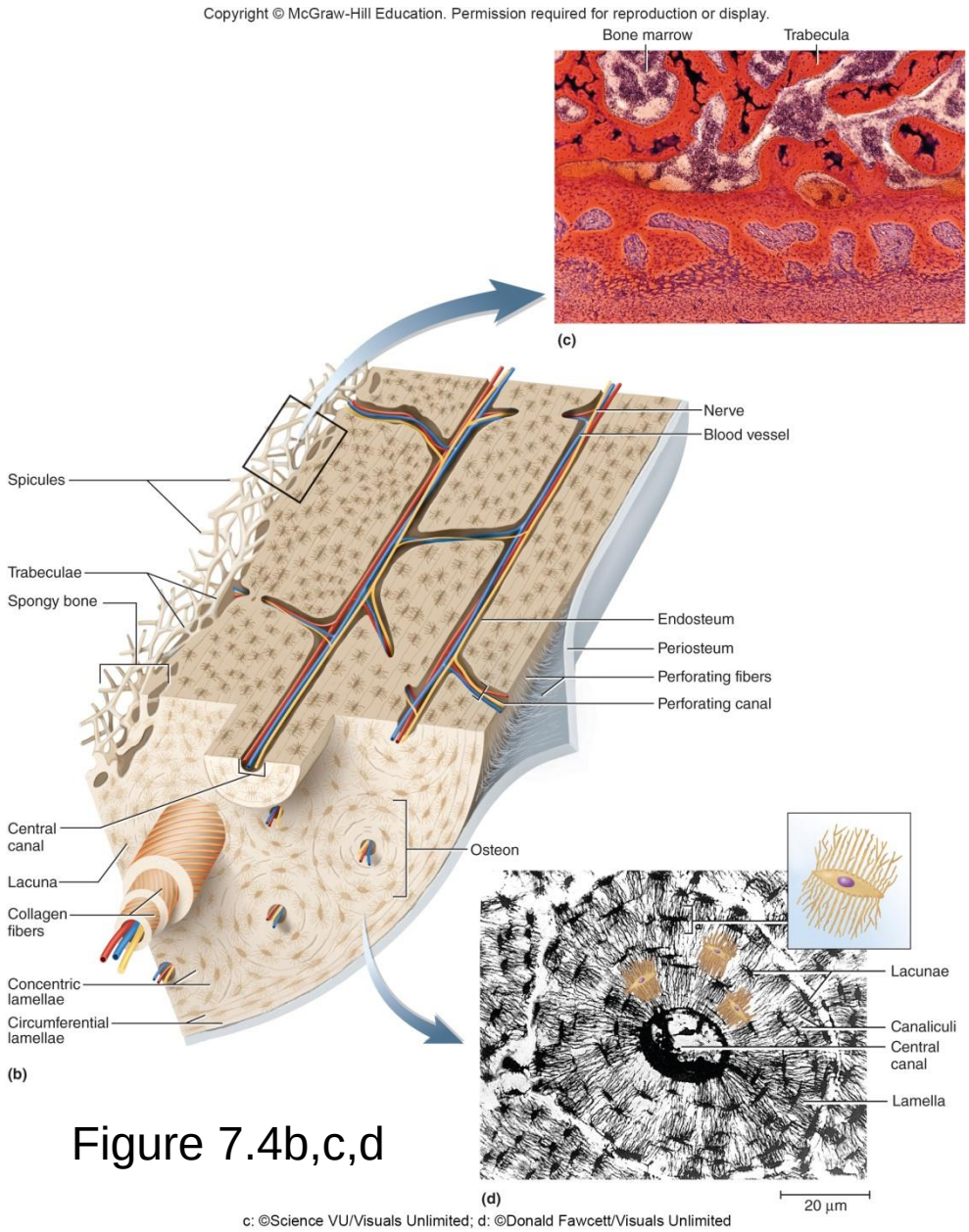

Figure 7.4b,c,d

c: ©Science VU/Visuals Unlimited; d: ©Donald Fawcett/Visuals Unlimited

- Histology of **compact bone** reveals **osteons (haversian systems)**
  - **Concentric lamellae** surround a **central (haversian) canal** running longitudinally
  - **Perforating (Volkmann) canals**—transverse or diagonal passages
  - **Circumferential lamellae** fill outer region of dense bone
  - **Interstitial lamellae** fill irregular regions between osteons

Spongy Bone

- **Spongy bone consists of:**
  - Lattice of bone covered with endosteum
    - Slivers of bone called **spicules**
    - Thin plates of bone called **trabeculae**
  - Spaces filled with **red bone marrow**
- **Few osteons and no central canals**
  - All osteocytes close to bone marrow
- **Provides strength with minimal weight**
  - Trabeculae develop along bone's **lines of stress**

Spongy Bone Structure in Relation to Mechanical Stress

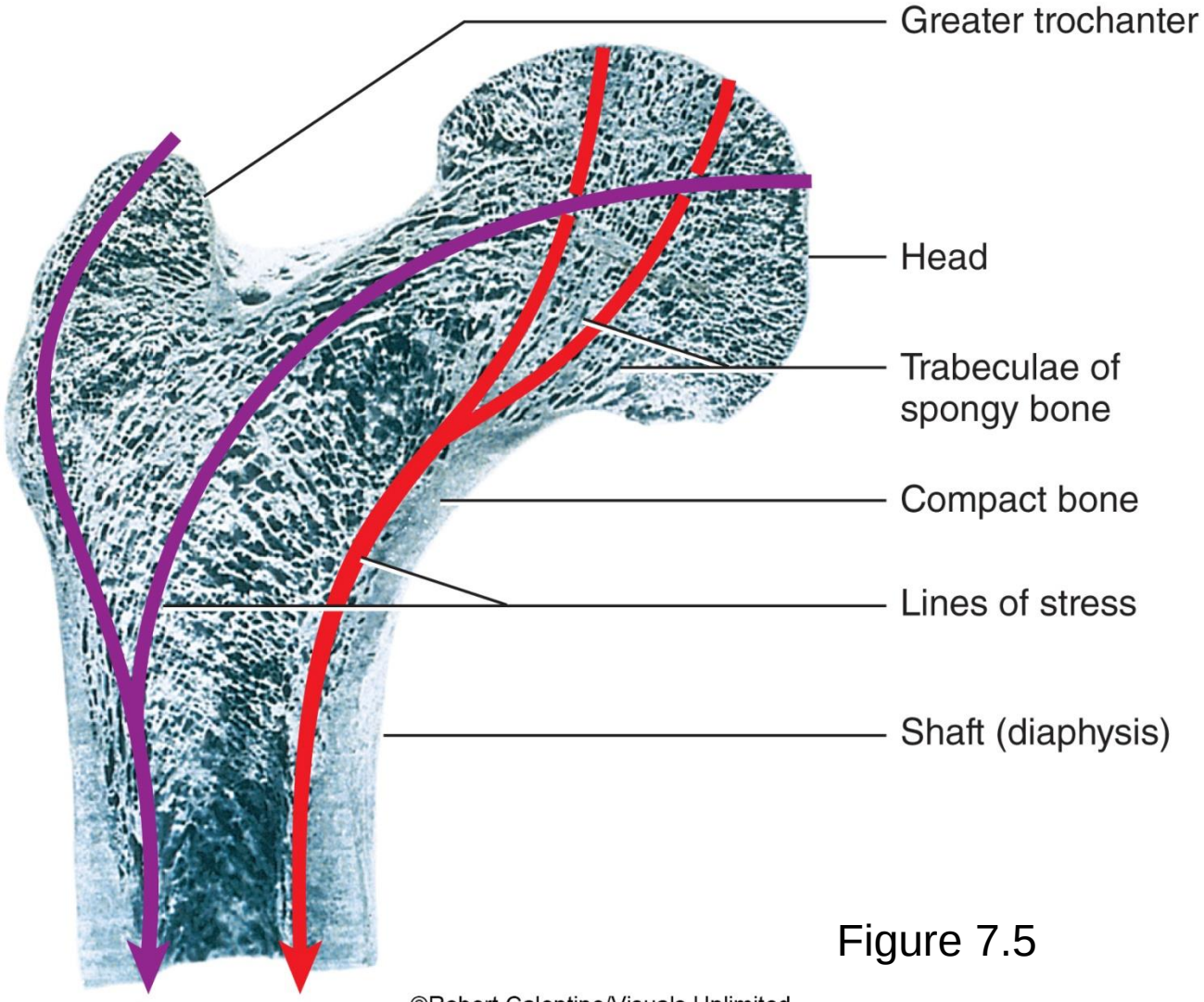

Figure 7.5

Bone Marrow

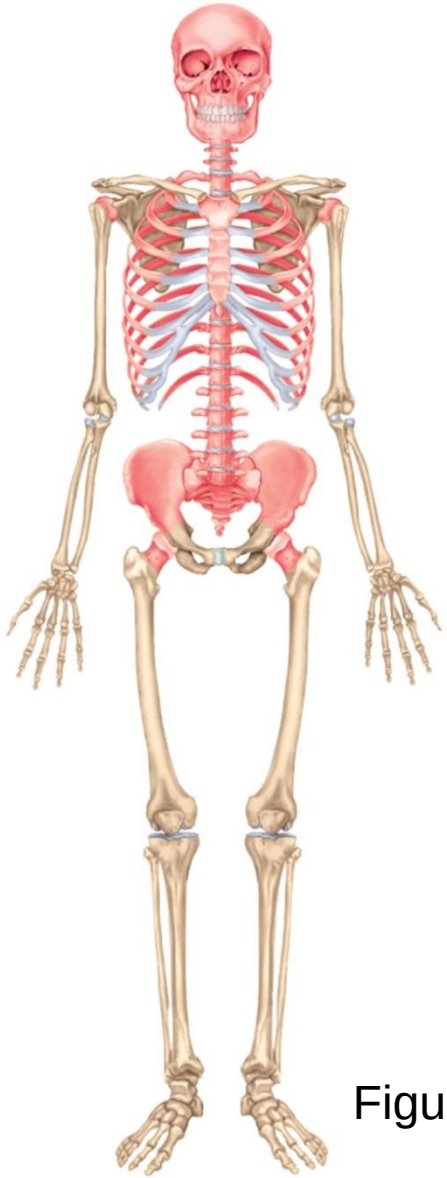

Figure 7.6

- **Bone marrow**—soft tissue occupying marrow cavities of long bones and small spaces of spongy bone
- **Red marrow (myeloid tissue)**
  - Contains **hemopoietic tissue**—produces blood cells
  - In nearly every bone in a child
  - In adults, found in skull, vertebrae, ribs, sternum, part of pelvic girdle, and proximal heads of humerus and femur
- **Yellow marrow** found in adults
  - Fatty marrow that does not produce blood
  - Can transform back to red marrow in the event of chronic anemia

Bone Development

- **Expected Learning Outcomes**
  - Describe two mechanisms of bone formation.
  - Explain how mature bone continues to grow and remodel itself.

Bone Development

- **Ossification** or **osteogenesis**—the formation of bone
- In the human fetus and infant, bone develops by **two methods**
  - **Intramembranous ossification**
  - **Endochondral ossification**

Intramembranous Ossification

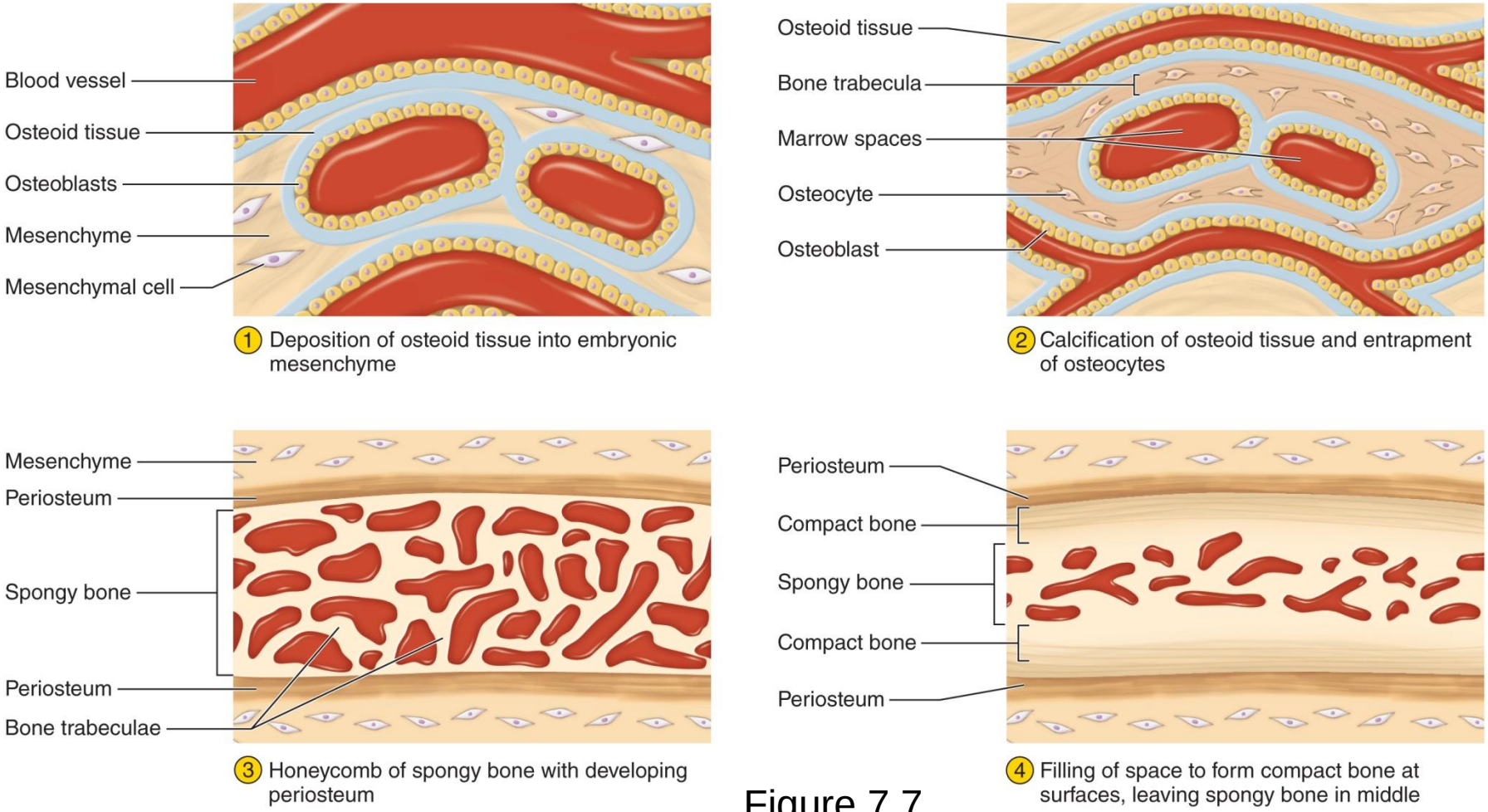

Figure 7.7

- **Produces flat bones of skull and clavicle in fetus**
- **Thickens long bones throughout life**

Intramembranous Ossification

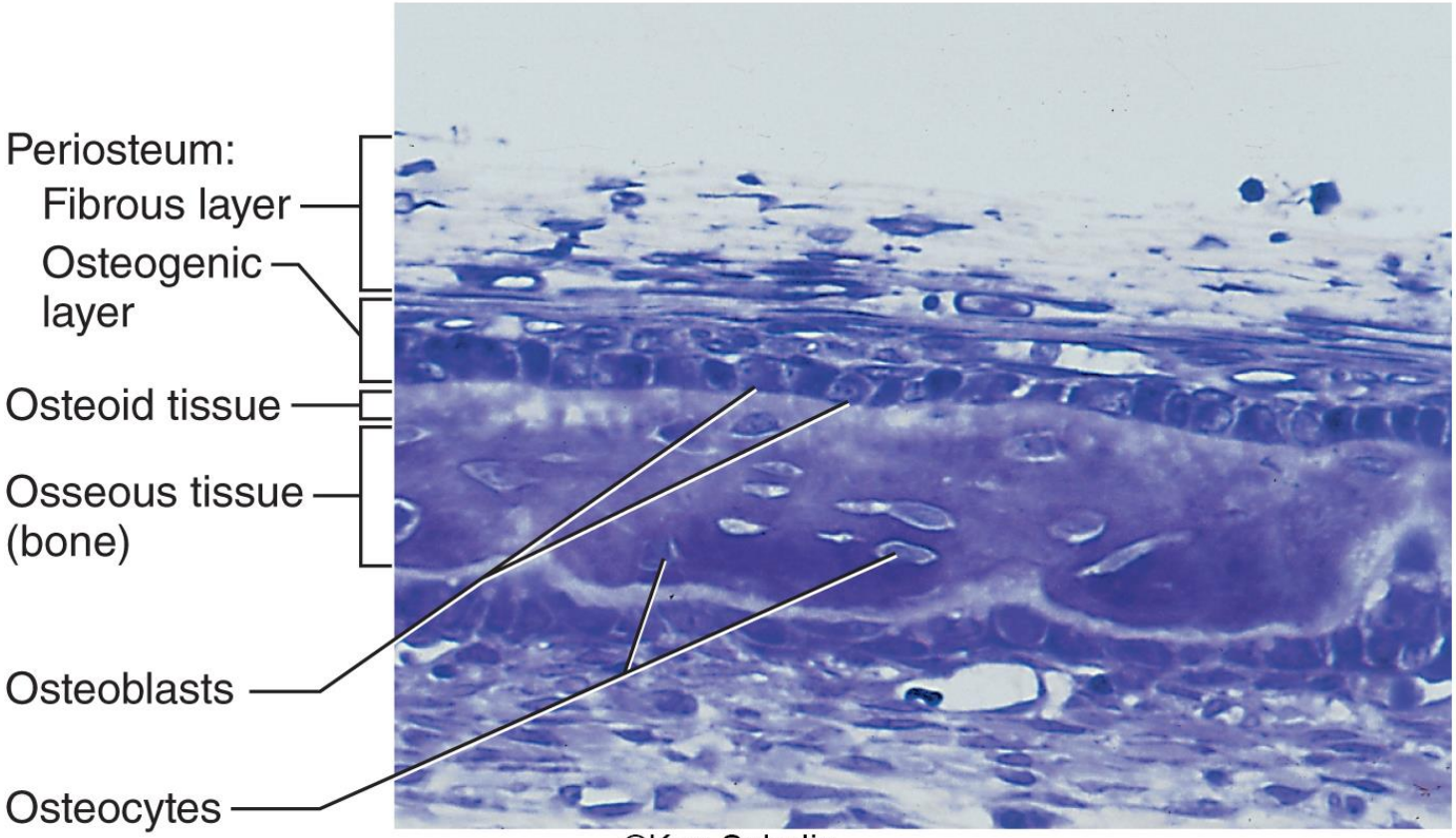

©Ken Saladin

Figure 7.8

- **Note the periosteum and osteoblasts**

Endochondral Ossification

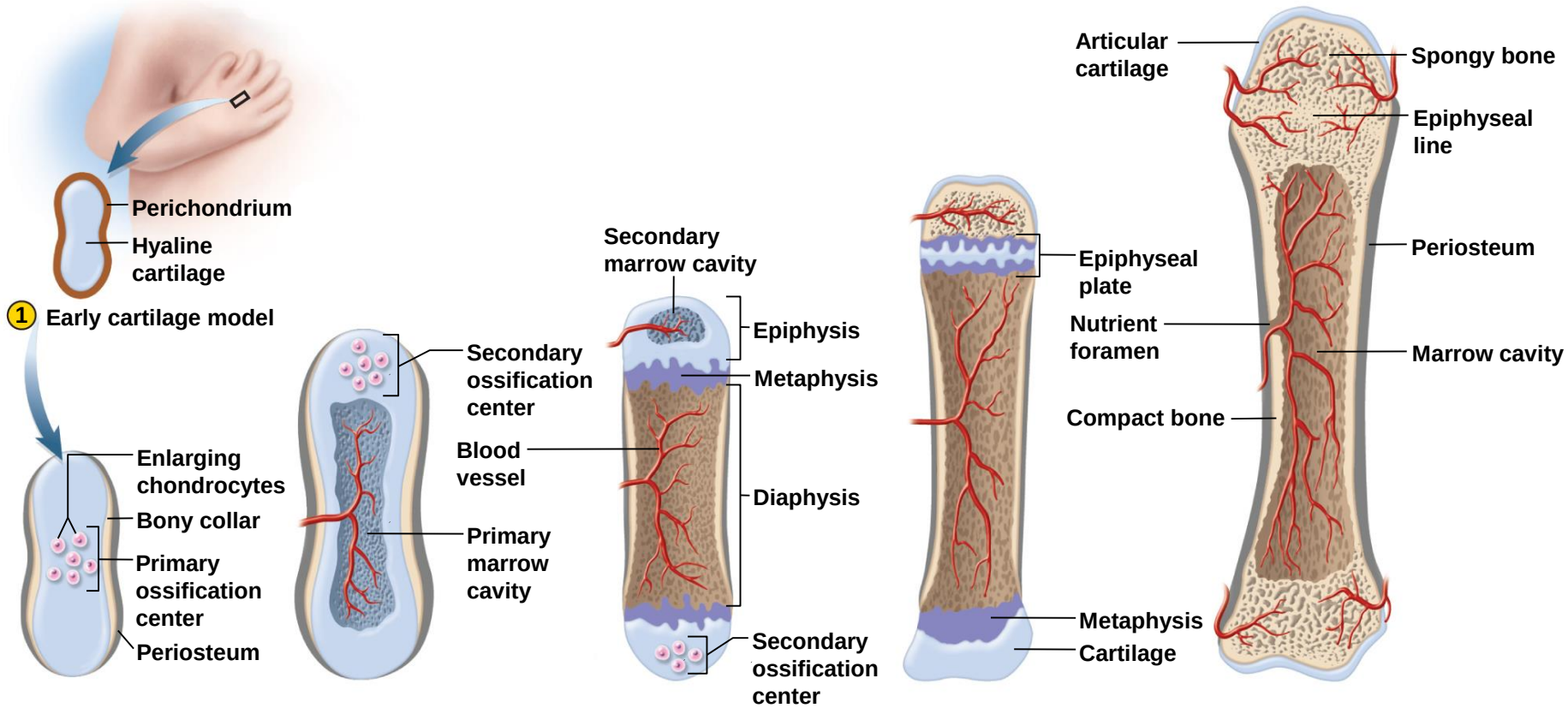

2 Formation of primary ossification center, bony collar, and periosteum

3 Vascular invasion, formation of primary marrow cavity, and appearance of secondary ossification center

4 Bone at birth, with enlarged primary marrow cavity and appearance of secondary marrow cavity in one epiphysis

5 Bone of child, with epiphyseal plate at distal end

6 Adult bone with a single marrow cavity and closed epiphyseal plate

Figure 7.9

Endochondral Ossification

- **During infancy and childhood, the epiphyses fill with spongy bone**
- Cartilage limited to the **articular cartilage** covering each joint surface, and to the **epiphyseal plate**
  - A thin wall of cartilage separating the primary and secondary marrow cavities
  - Epiphyseal plate persists through childhood and adolescence
  - Serves as a growth zone for bone elongation

Endochondral Ossification

- **By late teens to early 20s, all remaining cartilage in the epiphyseal plate is generally consumed**
  - Gap between epiphyses and diaphysis closes
  - Primary and secondary marrow cavities unite into a single cavity
  - Bone can no longer grow in length

The Fetal Skeleton at 12 Weeks

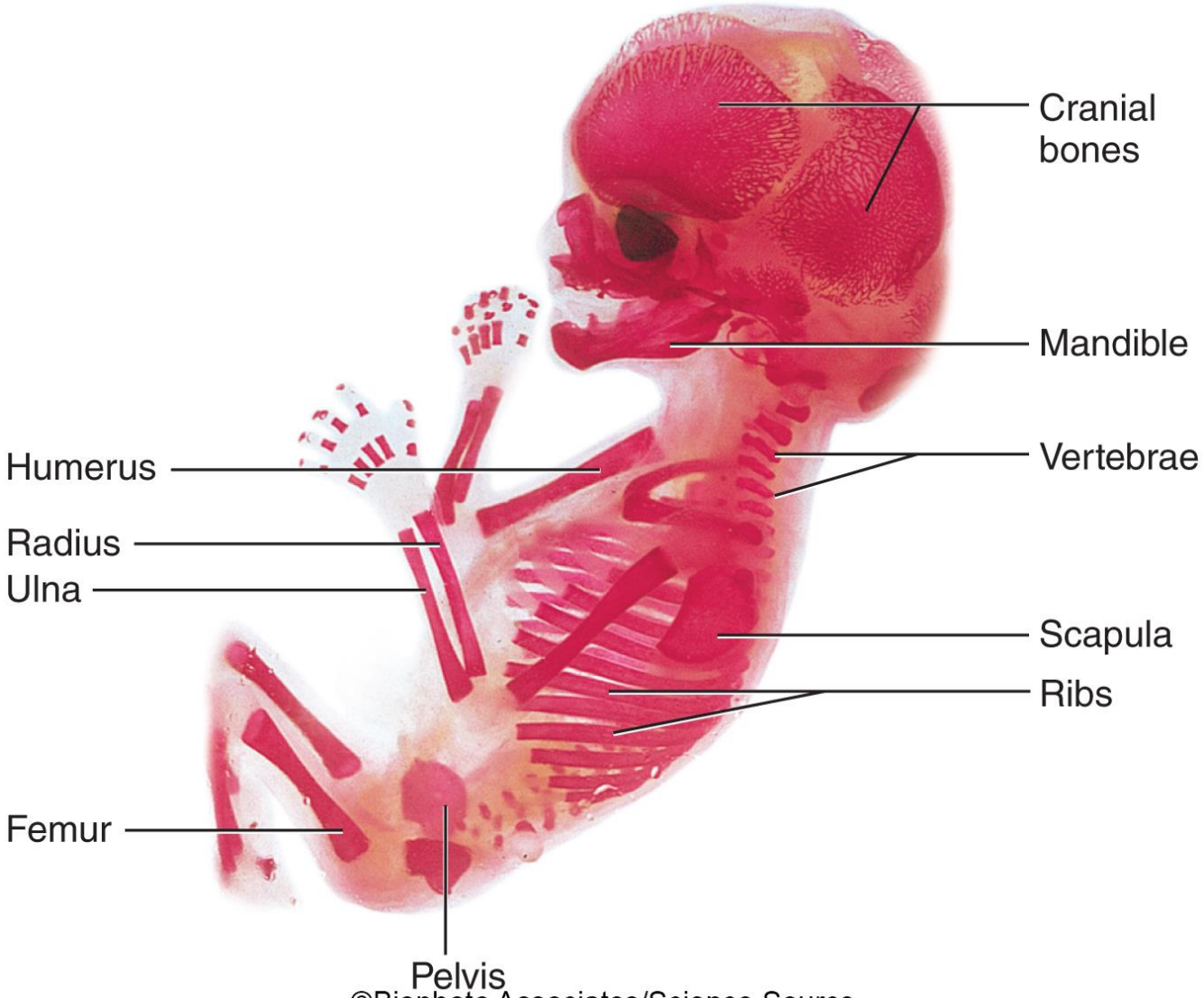

Figure 7.10

Bone Growth and Remodeling

- **Ossification** continues throughout life with the growth and remodeling of bones
- **Bones grow in two directions**
  - **Length**
  - **Width**

X-Ray of Child's Hand

Epiphyseal Plates

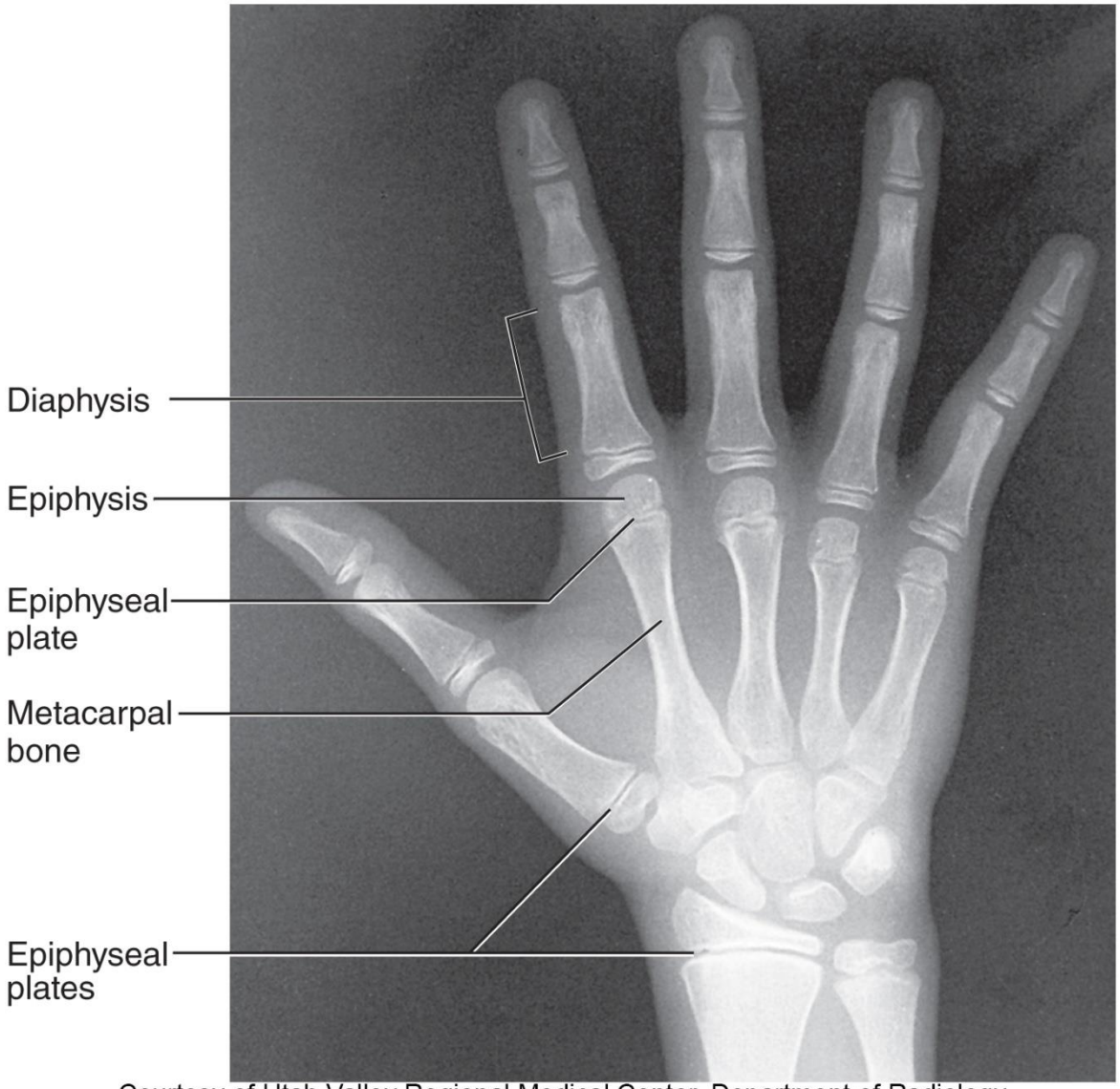

Figure 7.11

Courtesy of Utah Valley Regional Medical Center, Department of Radiology

Bone Elongation

- **Epiphyseal plate**—cartilage transitions to bone
  - Functions as **growth zone** where bone elongates
  - Has typical hyaline cartilage in the middle with transition zones on each side where cartilage is replaced by bone
  - **Metaphysis** is zone of transition facing the marrow cavity
- This is **interstitial growth**—growth from within
  - Bone elongation is a result of cartilage growth within the epiphyseal plate
  - Epiphyses close when cartilage is gone—**epiphyseal line** of spongy bone marks site of former epiphyseal plate
    - Lengthwise growth is finished
    - Occurs at different ages in different bones

Zones of the Metaphysis

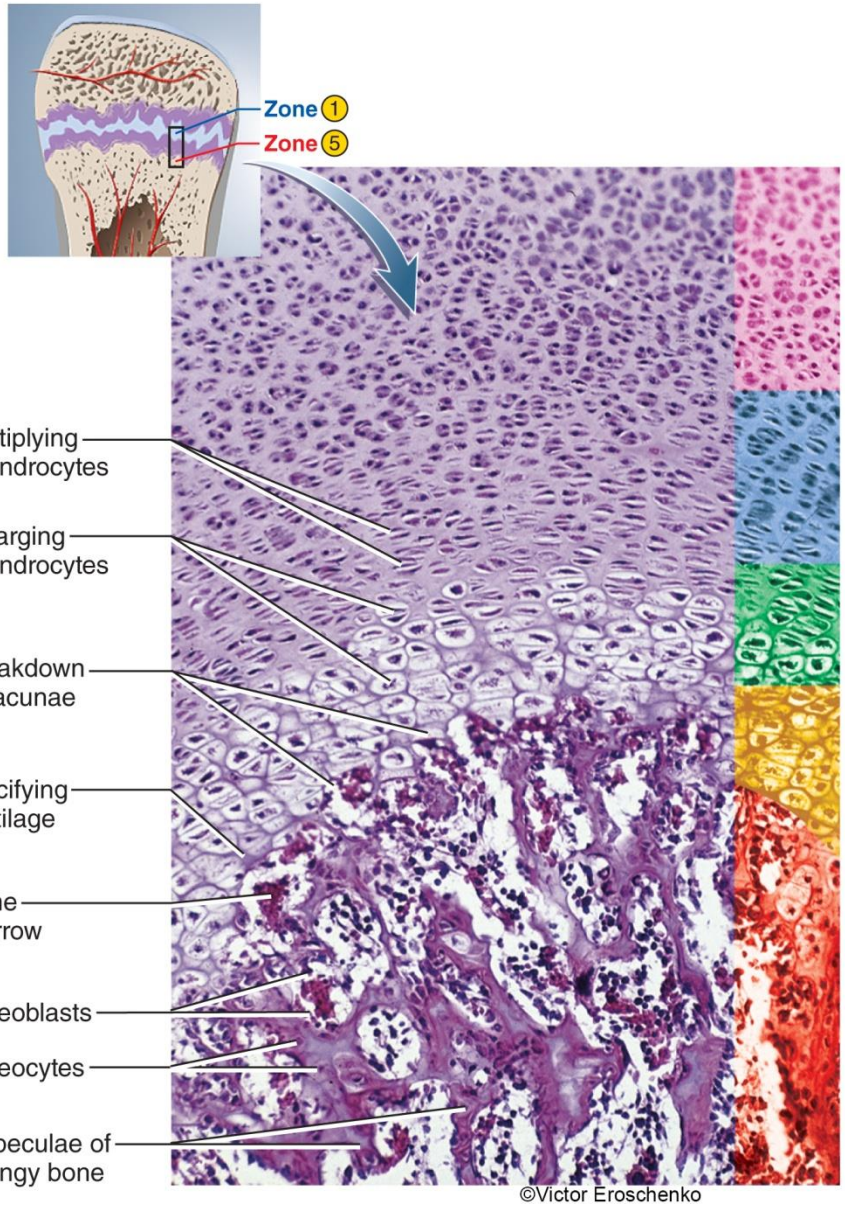

1. **Zone of reserve cartilage**
   Typical histology of resting hyaline cartilage
2. **Zone of cell proliferation**
   Chondrocytes multiplying and lining up in rows of small flattened lacunae
3. **Zone of cell hypertrophy**
   Cessation of mitosis; enlargement of chondrocytes and thinning of lacuna walls
4. **Zone of calcification**
   Temporary calcification of cartilage matrix between columns of lacunae
5. **Zone of bone deposition**
   Breakdown of lacuna walls, leaving open channels; death of chondrocytes; bone deposition by osteoblasts, forming trabeculae of spongy bone

Figure 7.12

Dwarfism

Figure 7.13

- **Achondroplastic dwarfism**
  - Long bones stop growing in childhood
    - Normal torso, short limbs
  - Failure of cartilage growth in metaphysis
  - Spontaneous mutation produces mutant dominant allele
- **Pituitary dwarfism**
  - Lack of growth hormone
  - Normal proportions with short stature

Bone Widening and Thickening

- **Appositional growth**—occurs at bone surface
  - Continual growth in diameter and thickness
  - Intramembranous ossification
  - Osteoblasts of inner periosteum deposit osteoid tissue
    - Become trapped as tissue calcifies
  - Lay down matrix in layers parallel to surface
    - Forms **circumferential lamellae**
    - Osteoclasts of endosteum enlarge marrow cavity

Bone Remodeling

- **Bone remodeling** (absorption and deposition) occurs throughout life—10% of skeleton per year
  - Repairs microfractures, releases minerals into blood, reshapes bones in response to use and disuse
  - **Wolff's law of bone:** architecture of bone determined by mechanical stresses placed on it
    - Remodeling is a collaborative and precise action of osteoblasts and osteoclasts
    - Bony processes grow larger in response to mechanical stress

Physiology of Osseous Tissue

- **Expected Learning Outcome**
  - Describe the processes by which minerals are added to and removed from bone tissue.
  - Describe the role of the bones in regulating blood calcium and phosphate levels.
  - Name several hormones that regulate bone physiology and describe their effects.

Physiology of Osseous Tissue

- **A mature bone remains a metabolically active organ**
  - Involved in its own maintenance of growth and remodeling
  - Exerts a profound influence over the rest of the body by exchanging minerals with tissue fluid
    - Disturbance of **calcium homeostasis** in skeleton disrupts function of other organ systems
      - Especially nervous and muscular

Mineral Deposition and Resorption

- **Mineral deposition (mineralization)**—process in which calcium, phosphate, and other ions are taken from blood and deposited in bone
  - **Osteoblasts** produce collagen fibers that spiral the length of the osteon
  - Fibers become encrusted with minerals
    - Hydroxyapatite crystals form at **solubility product**—critical level of calcium times phosphate concentration
    - First few crystals act as **seed crystals** that attract more calcium and phosphate from solution
  - **Abnormal calcification (ectopic ossification)**—formation of a **calculus** (calcified mass) in an otherwise soft organ such as a lung, brain, eye, muscle, tendon, or artery (arteriosclerosis)

Mineral Deposition and Resorption

- **Mineral resorption—**process of dissolving bone and releasing minerals into blood
  - Performed by **osteoclasts** at **ruffled border**
  - **Hydrogen pumps** in membranes secrete hydrogen into space between osteoclast and bone surface
  - **Chloride ions** follow by electrical attraction
  - **Hydrochloric acid** (pH 4) dissolves bone minerals
  - **Acid phosphatase** enzyme digests collagen
- **Orthodontic appliances (braces) reposition teeth through resorption and deposit**
  - Tooth moves because osteoclasts dissolve bone ahead of tooth; osteoblasts deposit bone behind the tooth

Calcium Homeostasis

- Calcium and phosphate are used for much more than bone structure
- Phosphate is a component of DNA, RNA, ATP, phospholipids, and pH buffers
- Calcium needed in neuron communication, muscle contraction, blood clotting, and exocytosis
- Minerals are deposited in the skeleton and withdrawn when they are needed for other purposes

Calcium Homeostasis

- **Total of about 1,100 g of calcium in adult body with 99% of it in bones**
  - Most exists as part of hydroxyapatite, but a little is in a form that is easily exchanged with the blood
  - About 18% of skeletal calcium is exchanged with blood each year
- **Normal calcium concentration in blood plasma is 9.2 to 10.4 mg/dL**
  - 45% as Ca^{2+} that can diffuse across capillary walls and affect other tissues
  - Rest in reserve, bound to plasma proteins

Calcium Homeostasis

- **Hypocalcemia**—deficient calcium in blood
  - Changes membrane potentials and causes overly excitable nervous system and tetany (muscle spasms)
    - **Laryngospasm** can cause suffocation
  - Caused by vitamin D deficiency, diarrhea, thyroid tumors, underactive parathyroid glands
  - Pregnancy and lactation increase risk of hypocalcemia
- **Hypercalcemia**—excessive calcium levels
  - Makes ion channels less responsive and thus nerve and muscle are less excitable
    - Can cause emotional disturbance, muscle weakness, sluggish reflexes, cardiac arrest
  - Hypercalcemia rarely occurs

Calcium Homeostasis

- **Calcium homeostasis** depends on a balance between dietary intake, urinary and fecal losses, and exchanges between osseous tissue
- **Calcium homeostasis is regulated by three hormones:**
  - **Calcitriol, calcitonin,** and **parathyroid hormone**

Calcitriol

- **Calcitriol**—most active form of vitamin D
- **Produced by actions of skin, liver, and kidneys**
  - **Epidermal keratinocytes** use UV radiation to convert **7-dehydrocholesterol** to **previtamin D_3;** warm sun on skin converts this to **vitamin D_3**
  - **Liver** adds hydroxyl group converting that to **calcidiol**
  - **Kidney** adds hydroxyl group converting that to **calcitriol**

Calcitriol

- **Calcitriol is a hormone that raises blood calcium level**
  - Mainly, it increases calcium absorption by small intestine
  - It also increases calcium resorption from the skeleton
    - Stimulates osteoblasts to release RANKL, a chemical that stimulates production of more osteoclasts
  - It weakly promotes kidney reabsorption of calcium ions, so less lost in urine

Calcitriol Synthesis and Action

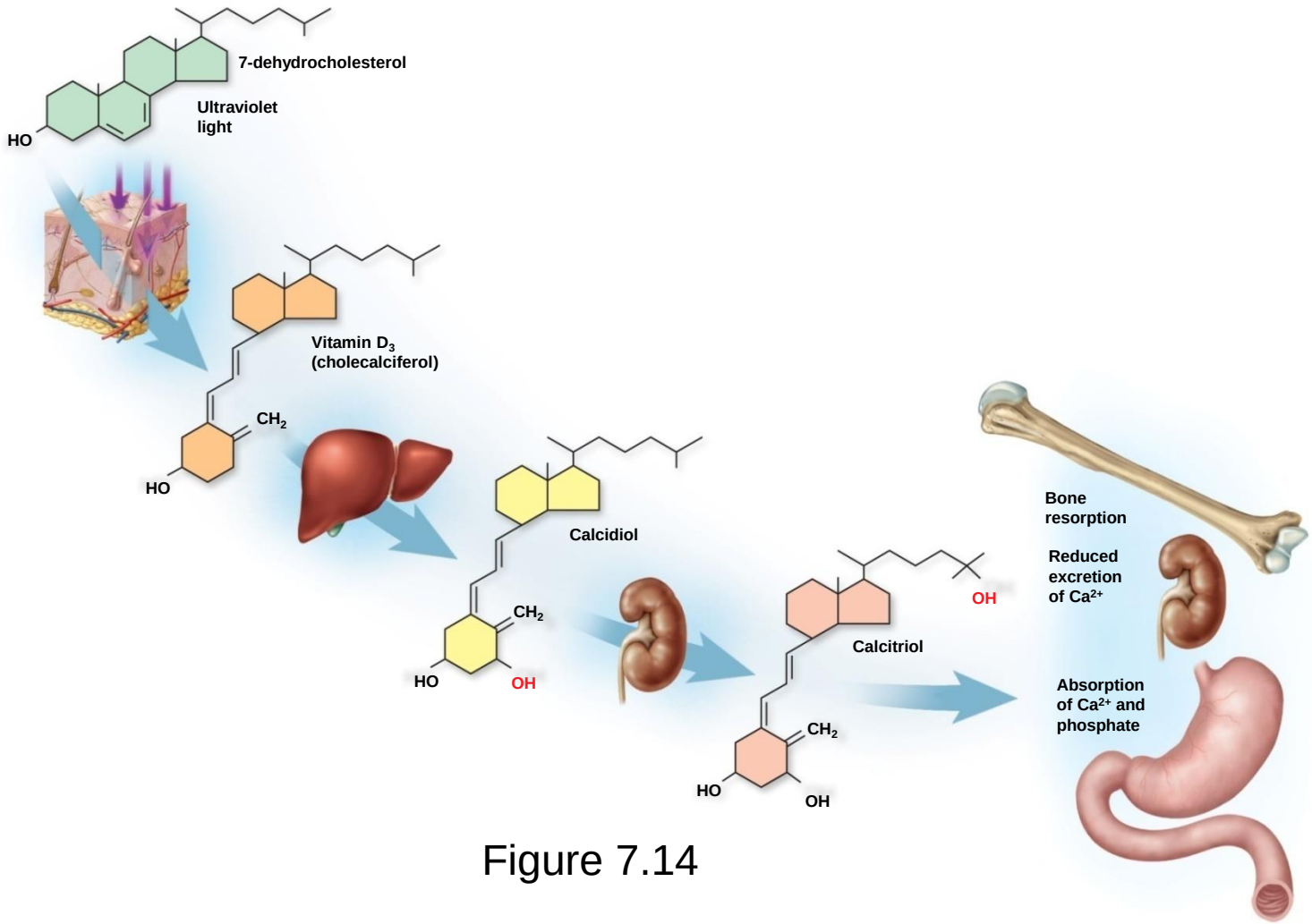

Figure 7.14

Calcitriol

- **Calcitriol is also necessary for bone deposition—helping provide adequate calcium and phosphate**
- Inadequate calcitriol results in abnormal softness of bones in children (**rickets**) and in adults (**osteomalacia**)

Calcium Homeostasis

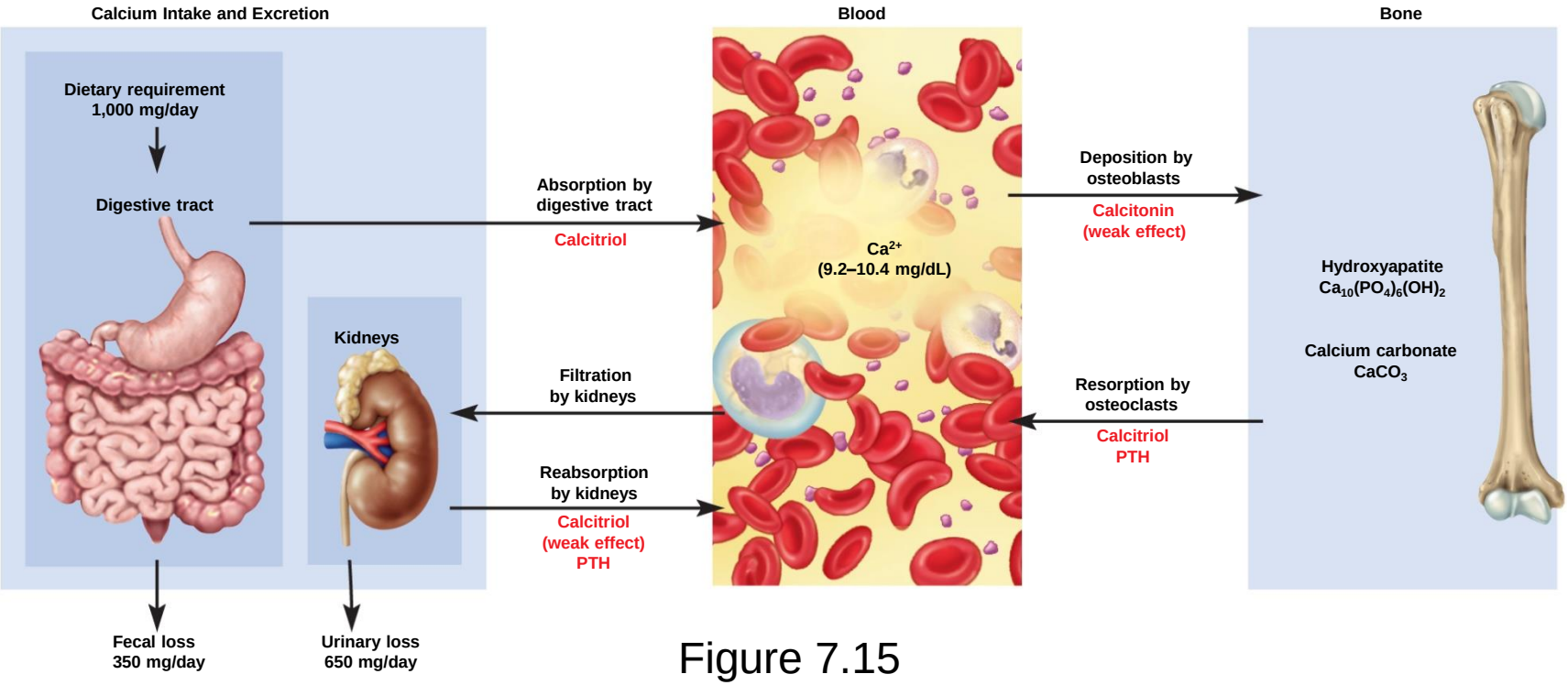

Figure 7.15

Calcitriol, calcitonin, and PTH maintain normal blood calcium concentration

Calcitonin

- **Calcitonin**—secreted by **C cells (clear cells)** of thyroid gland when blood calcium levels rise too high
- **Lowers blood calcium concentration in two ways:**
  - Inhibits osteoclasts thereby reducing bone resorption
  - Stimulates osteoblasts to deposit calcium into bone
- **Important in children, weak effect in adults**
  - Osteoclasts more active in children due to faster remodeling
- **May inhibit bone loss in pregnant and lactating women**

Parathyroid Hormone

- **Parathyroid hormone (PTH)**—secreted by parathyroid glands on posterior surface of thyroid
- **PTH released when calcium levels low in blood**
- **PTH raises calcium blood level by four mechanisms**
  - Stimulates osteoblasts to secrete RANKL, thereby increasing osteoclast population and bone resorption
  - Promotes calcium reabsorption by kidneys, so less lost in urine
  - Promotes the final step of calcitriol synthesis in the kidneys, enhancing calcium-raising effect of calcitriol
  - Inhibits collagen synthesis by osteoblasts, inhibiting bone deposition

Calcium Homeostasis

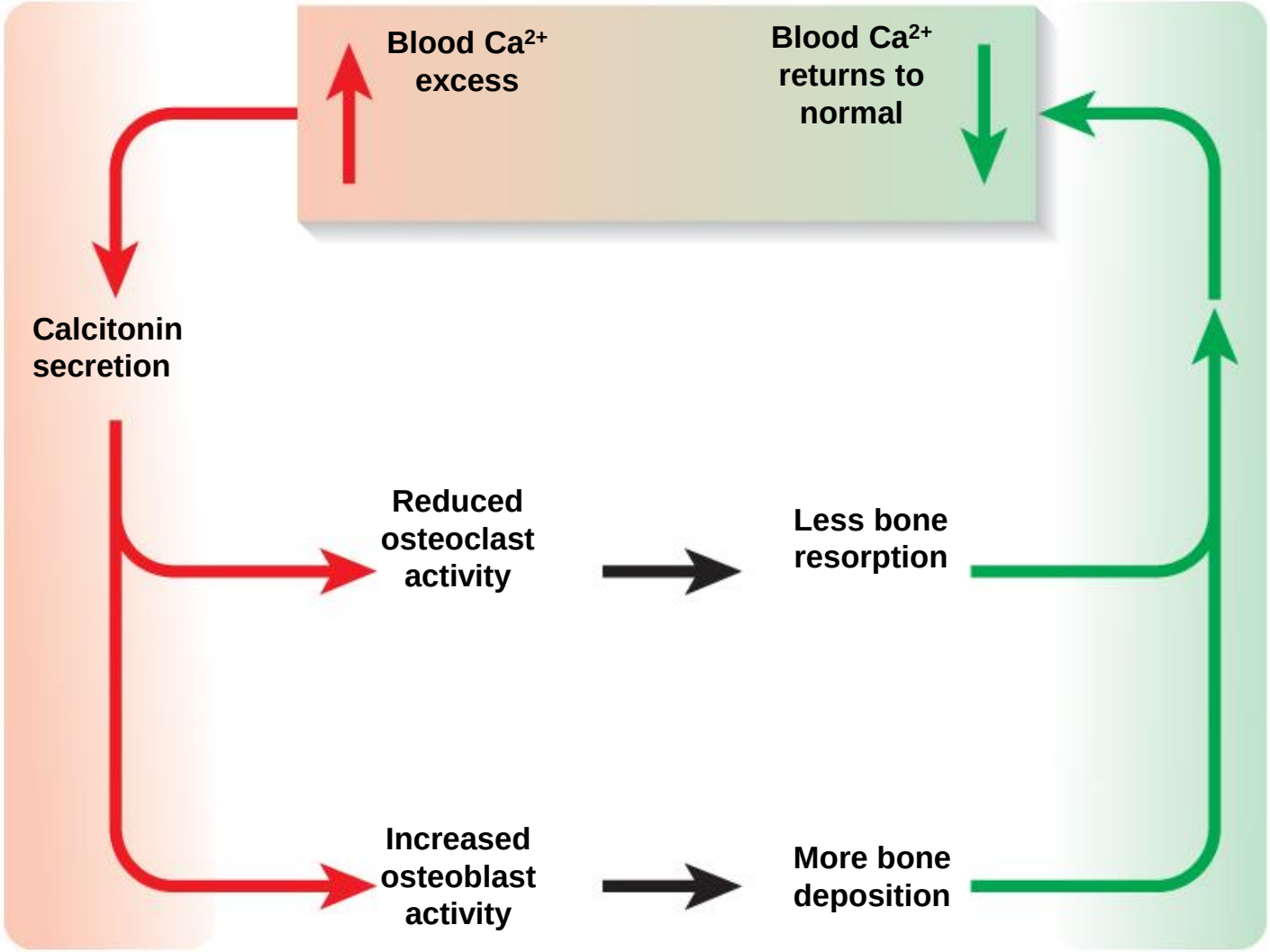

(a) Correction for hypercalcemia

Figure 7.16a

Calcium Homeostasis

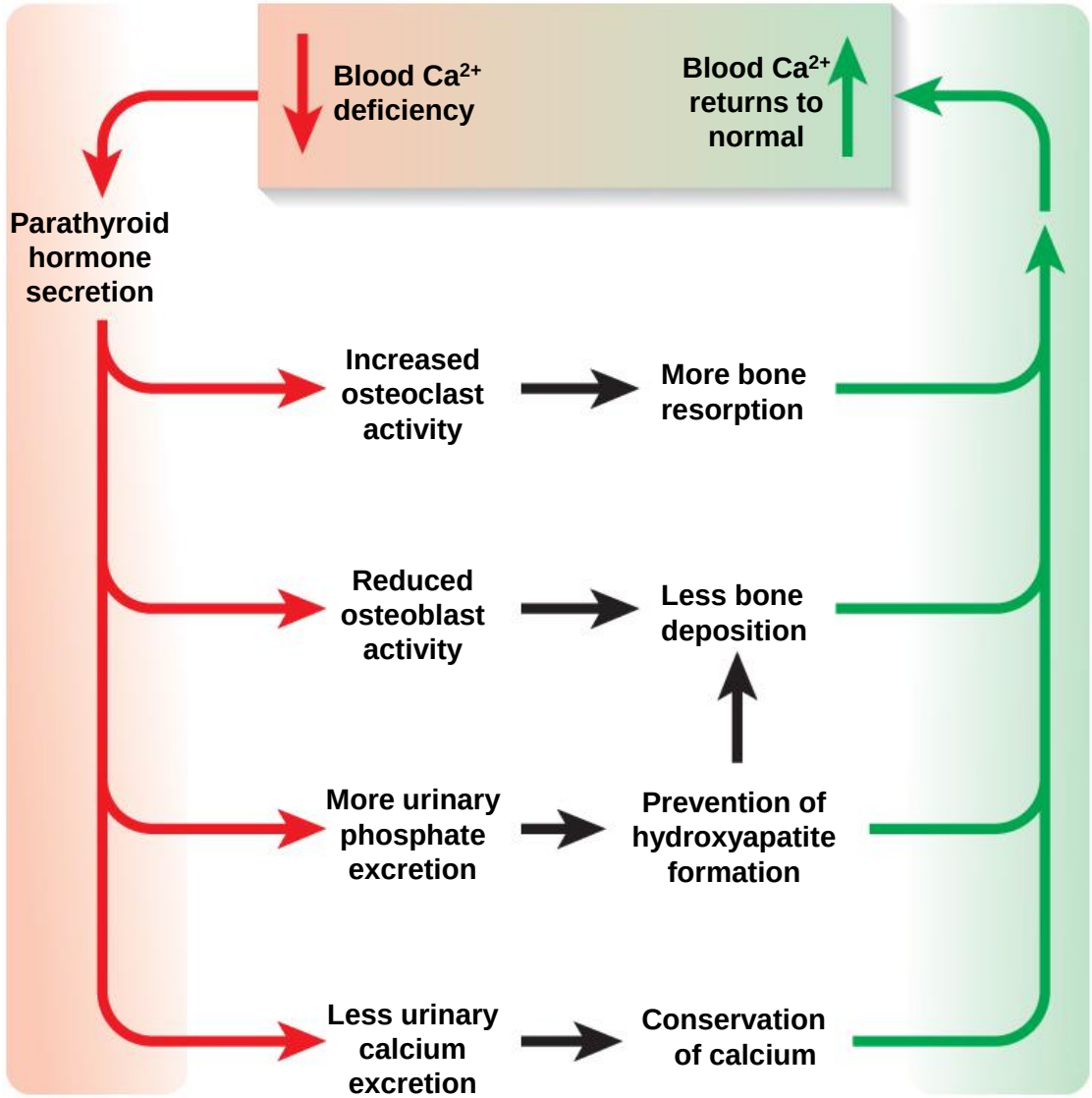

(b) Correction for hypocalcemia

Figure 7.16b

Phosphate Homeostasis

- **Average adult has 500 to 800 g phosphorus with 85% to 90% of it in the bones**
- Normal plasma concentration is **3.5 to 4.0 mg/dL**
- Occurs in **two main forms**
  - **HPO_4^{2-}** and **$H_2PO_4^-$** (monohydrogen and dihydrogen phosphate ions)
- **Phosphate levels are not regulated as tightly as calcium levels**
- **Calcitriol raises phosphate levels** by promoting its absorption by small intestine
- **PTH lowers blood phosphate levels** by promoting its urinary excretion

Other Factors Affecting Bone

- **At least 20 or more hormones, vitamins, and growth factors affect osseous tissue**
- **Bone growth especially rapid in puberty and adolescence**
  - Surges of growth hormone, estrogen, and testosterone occur and promote ossification
  - These hormones stimulate multiplication of osteogenic cells, matrix deposition by osteoblasts, and chondrocyte multiplication and hypertrophy in metaphyses

Other Factors Affecting Bone

(Continued)

- Girls grow faster than boys and reach full height earlier
  - Estrogen has stronger effect than testosterone on bone growth
- Males grow for a longer time and also taller

- **Anabolic steroids** cause growth to stop
  - Epiphyseal plate “closes” prematurely
  - Results in abnormally short adult stature

Bone Disorders

- **Expected Learning Outcomes**
  - Name and describe several bone diseases.
  - Name and describe the types of fractures.
  - Explain how a fracture is repaired.
  - Discuss some clinical treatments for fractures and other skeletal disorders.

Bone Disorders

- **Orthopedics**—branch of medicine dealing with prevention and correction of injuries and disorders of bones, joints, and muscles
  - Name implies its origin as field treating skeletal deformities in children
- **Includes the design of artificial joints and limbs and the treatment of athletic injuries**

Fractures and Their Repair

- **Stress fracture**—break caused by abnormal trauma to a bone (example: in a fall)
- **Pathological fracture**—break in a bone weakened by disease (such as bone cancer or osteoporosis)
  - Usually caused by a stress that would not break a healthy bone
- **Fractures** classified by structural characteristics
  - Direction of fracture line
  - Break in the skin
  - Multiple pieces
    - Example: comminuted—three or more pieces

Types of Bone Fractures

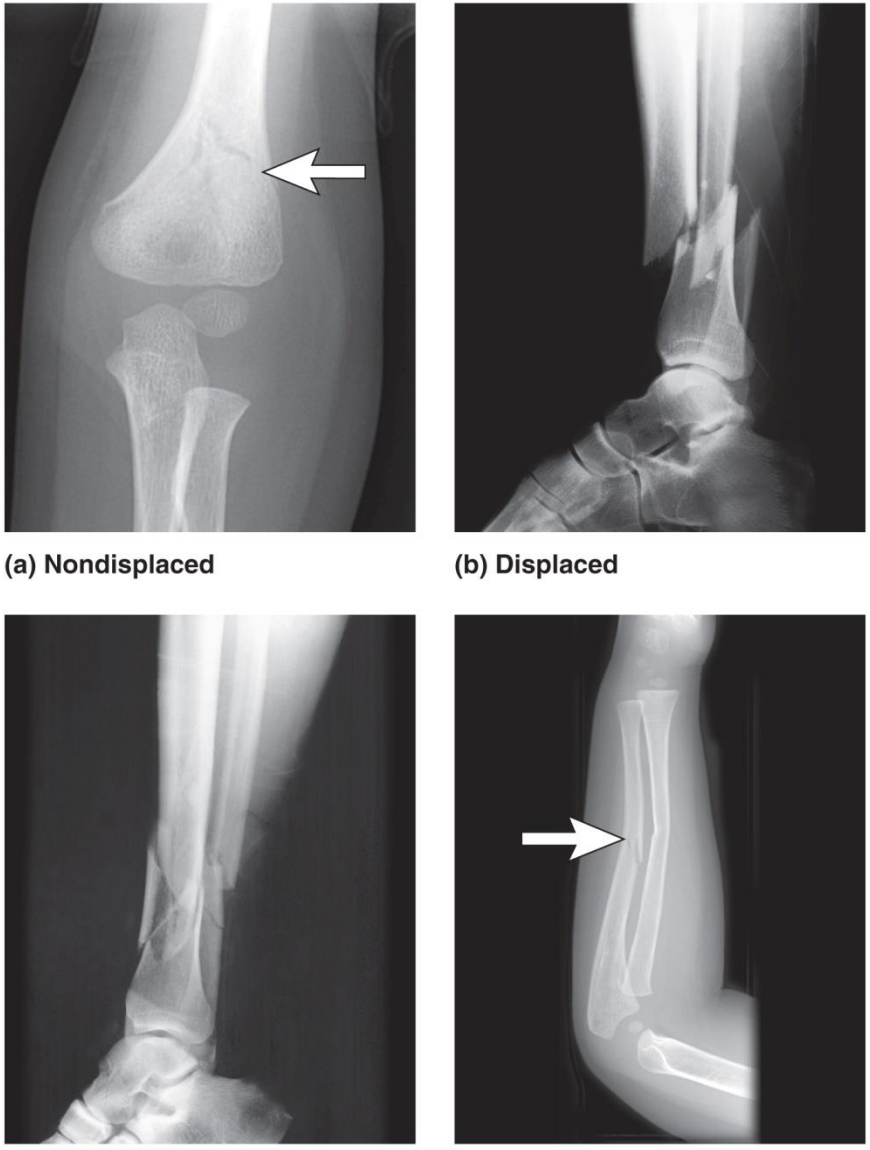

(a) Nondisplaced (b) Displaced

(c) Comminuted (d) Greenstick

a: ©Custom Medical Stock Photo, Inc.; b: ©Howard Kingsnorth/Getty Images;
c: © Lester V. Bergman/Corbis; d: ©Custom Medical Stock Photo, Inc.

Figure 7.17

Healing of Fractures

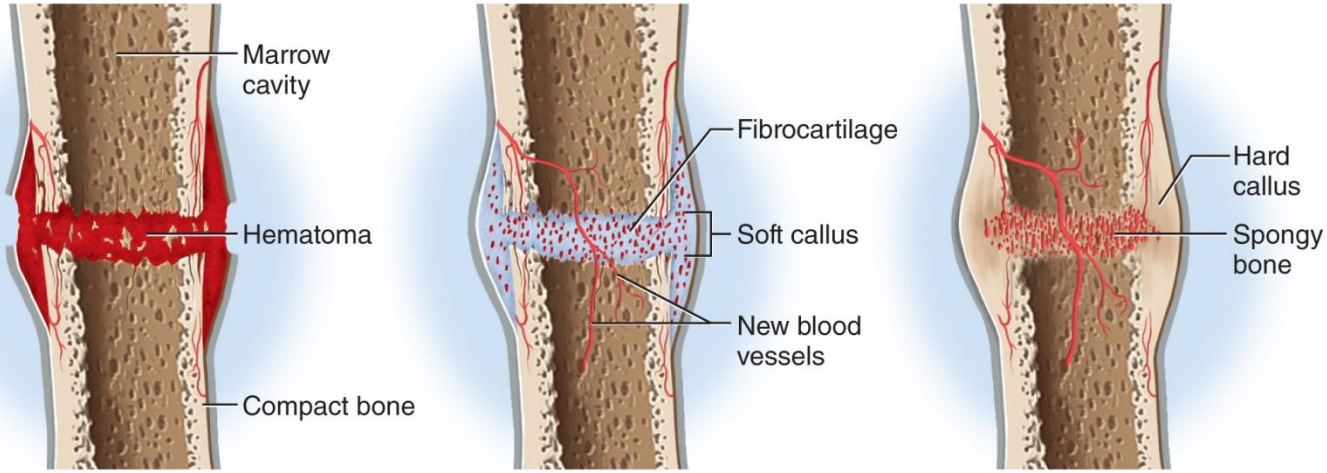

1 **Hematoma formation**
The hematoma is converted to granulation tissue by invasion of cells and blood capillaries.

2 **Soft callus formation**
Deposition of collagen and fibrocartilage converts granulation tissue to a soft callus.

3 **Hard callus formation**
Osteoblasts deposit a temporary bony collar around the fracture to unite the broken pieces while ossification occurs.

4 **Bone remodeling**
Small bone fragments are removed by osteoclasts, while osteoblasts deposit spongy bone and then convert it to compact bone.

Figure 7.18

The Treatment of Fractures

- **Closed reduction**—procedure in which bone fragments are manipulated into their normal positions without surgery
- **Open reduction**—involves surgical exposure of the bone and the use of plates, screws, or pins to realign the fragments
- **Cast**—normally used to stabilize and immobilize healing bone

The Treatment of Fractures

- Fractures of the femur in children often treated with **traction**
  - Aligns bone fragments by overriding force of the strong thigh muscles
- **Hip fractures in older adults are usually pinned and early walking is encouraged**
  - Fractures taking more than 2 months to heal may be treated with electrical stimulation which suppresses effects of parathyroid hormone

Open Reduction of an Ankle Fracture

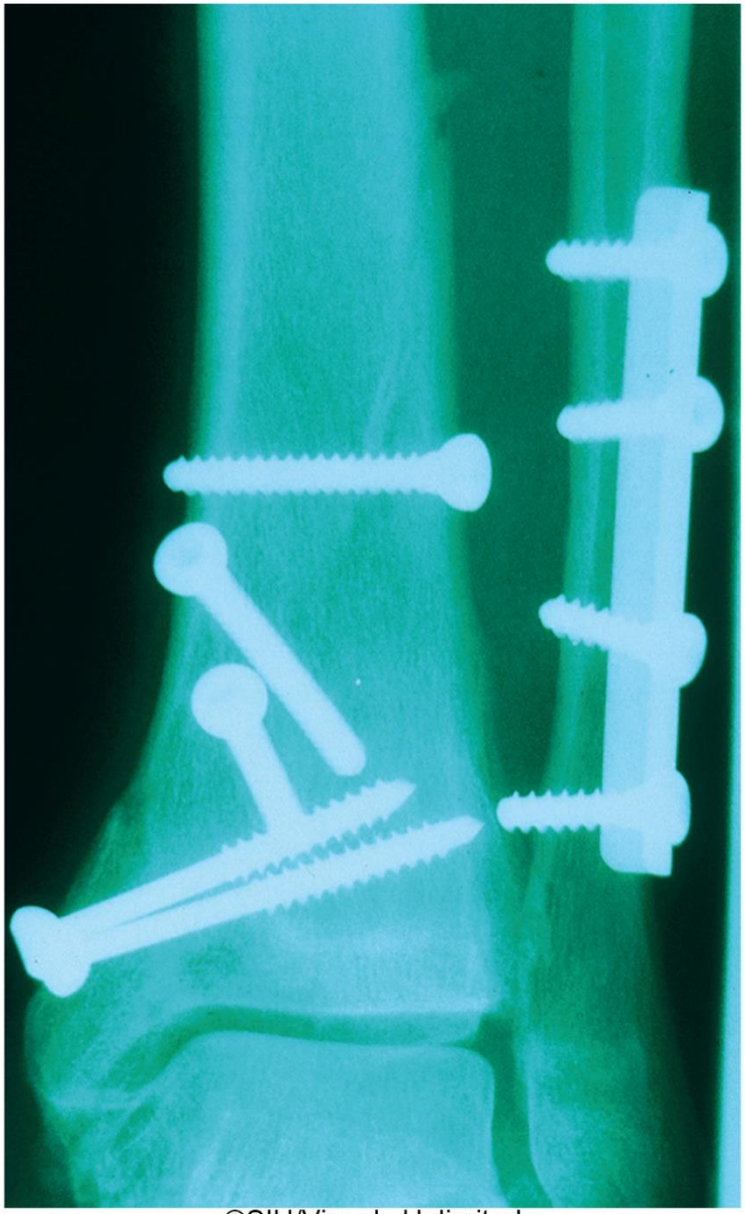

Figure 7.19

Other Bone Disorders

- **Osteoporosis**—the most common bone disease
  - Severe loss of bone density
- **Bones lose mass and become brittle due to loss of organic matrix and minerals**
  - Affects spongy bone the most since it is the most metabolically active
  - Subject to pathological fractures of hip, wrist, and vertebral column
  - **Kyphosis (widow's hump)**—deformity of spine due to vertebral bone loss
  - Complications of loss of mobility are pneumonia and thrombosis

Osteoporosis

- **Estrogen maintains bone density in both sexes; inhibits resorption by osteoclasts**

- **Postmenopausal white women at greatest risk**
  - Ovaries cease to secrete estrogen
  - White women begin to lose bone mass as early as age 35
    - By age 70, average loss is 30% of bone mass
  - Risk factors: race, age, gender, smoking, diabetes mellitus, diets poor which are poor in: calcium, protein, vitamins C and D

- **Osteoporosis also seen in young female athletes with low body fat causing them to stop ovulating and decrease estrogen secretion**

Osteoporosis

(Continued)

- **Treatments**
  - **Estrogen replacement therapy (ERT)** slows bone resorption, but increases risk of breast cancer, stroke, and heart disease
  - Drugs **Fosamax, Actonel** destroy osteoclasts
  - **PTH** slows bone loss if given as daily injection
    - **Forteo** (PTH derivative) increases density by 10% in 1 year
      - May promote bone cancer so use is limited to 2 years
  - Best treatment is **prevention:** exercise and a good bone-building diet between ages 25 and 40

Osteoporosis

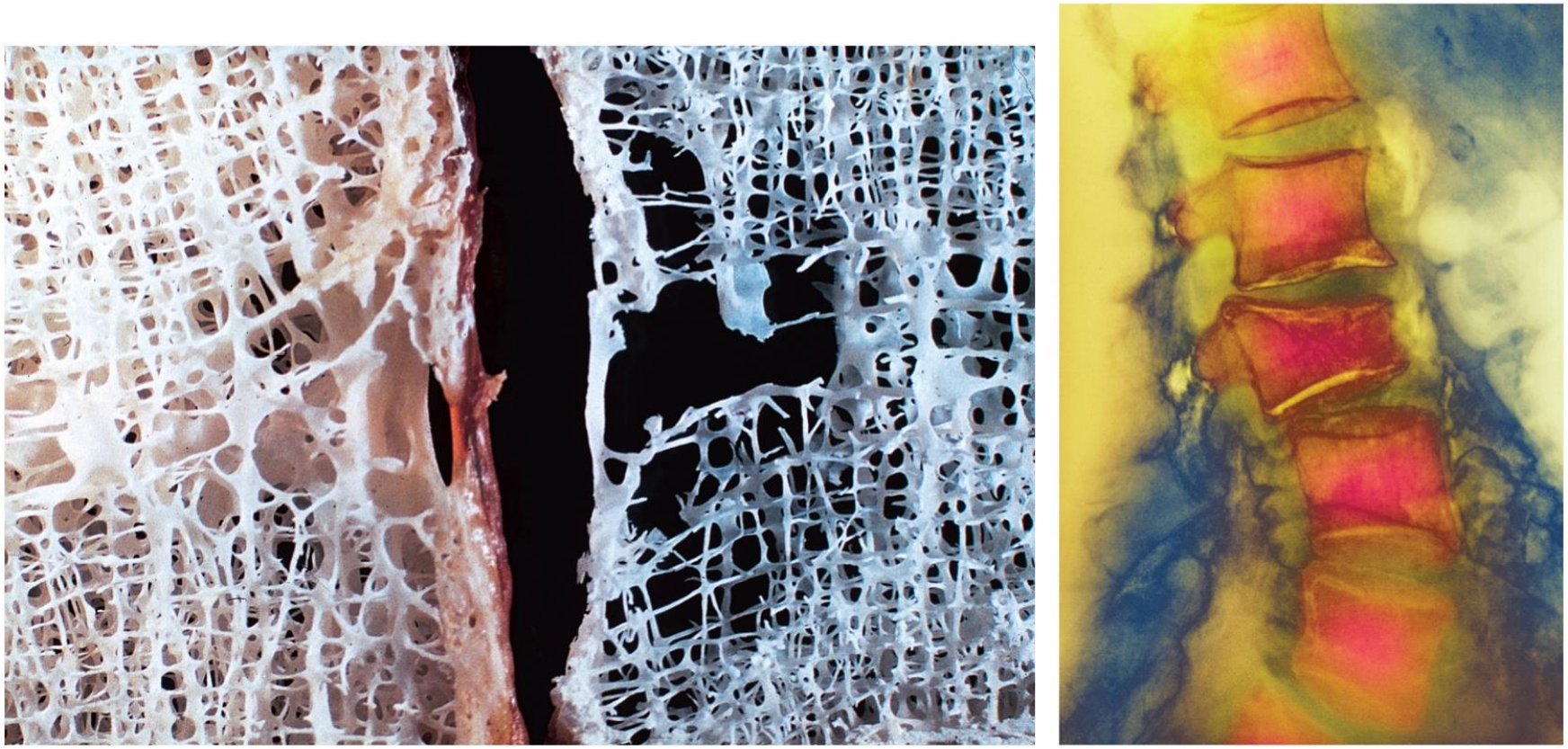

(a) (b)

a: ©Michael Klein/Peter Arnold, Inc./Getty Images; b: © Dr. P. Marzzi/Science Source

Figure 7.20 a,b