Chapter 27
Lecture Outline

See separate PowerPoint slides for all figures and tables pre-inserted into PowerPoint without notes.

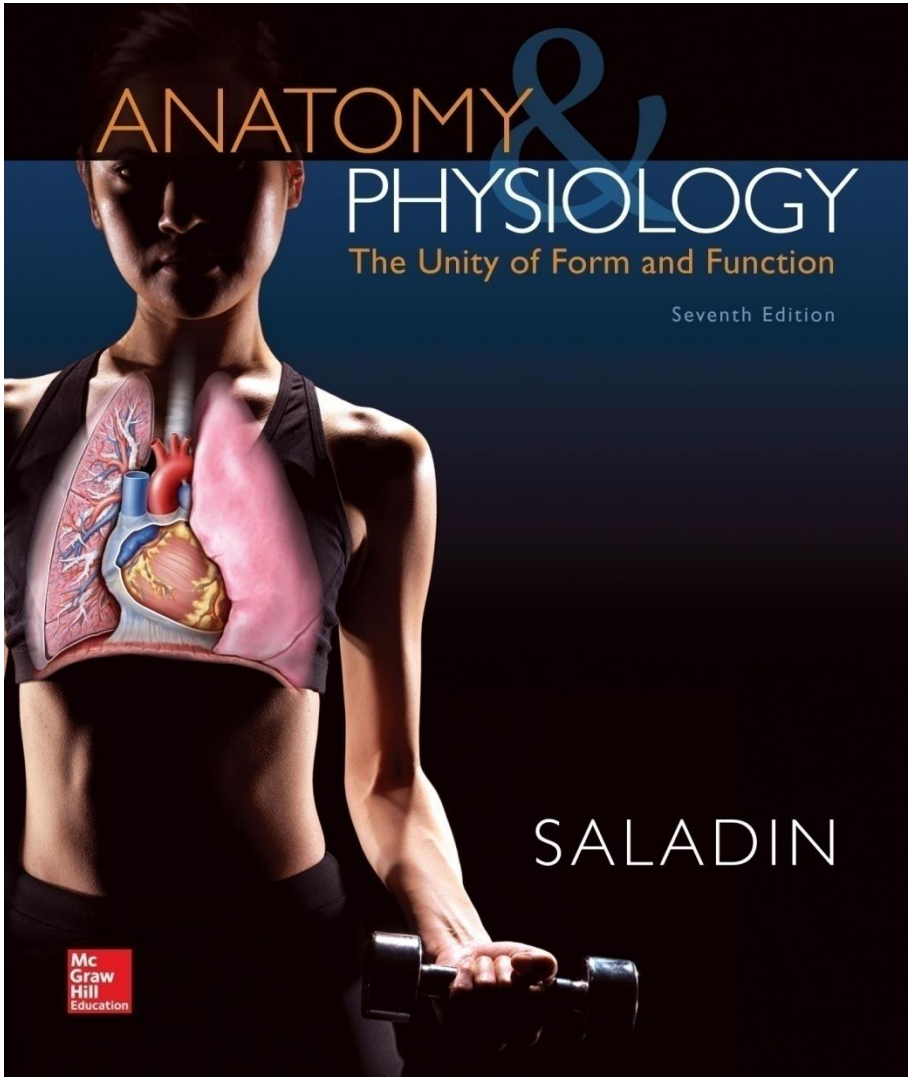

Introduction

- **Our genes live on in our offspring**
- **This chapter will focus on some general aspects of human reproductive biology and the role of the male in reproduction**

Sexual Reproduction and Development

- **Expected Learning Outcomes**
  - Identify the most fundamental biological distinction between male and female.
  - Define *primary sex organs, secondary sex organs,* and *secondary sex characteristics.*
  - Explain the role of the sex chromosomes in determining sex.

Sexual Reproduction and Development

(Continued)

- Explain how the Y chromosome determines the response of the fetal gonad to prenatal hormones.
- Identify which of the male and female external genitalia are homologous to each other.
- Describe the descent of the gonads and explain why it is important.

The Two Sexes

- Sexual reproduction is **biparental,** meaning offspring receives genes from two parents
  - Offspring is not genetically identical to either one
  - We will die, but our genes will live on in a different container—that is, our offspring
- **Gametes (sex cells)** produced by each parent
- **Zygote (fertilized egg)** has combination of both parents' genes

The Two Sexes

- Male and female **gametes (sex cells)** combine their genes to form a **zygote (fertilized egg)**
  - One gamete has **motility:** sperm (spermatozoon)
    - Parent producing sperm considered male
    - Parent with a Y chromosome is male
  - Other gamete **contains nutrients** for developing embryo: egg (ovum)
    - Parent producing eggs considered female
    - Anyone lacking a Y chromosome is female
    - In mammals, female is the parent that provides **a sheltered internal environment** and **prenatal nutrition of the embryo**

The Two Sexes

- **Male reproductive system** serves to produce sperm and introduce them into the female body
  - Males have a **copulatory organ (penis)** for introducing their gametes into the female reproductive tract
- **Female reproductive system** produces eggs, receives sperm, provides for gametes' union, harbors fetus, and nourishes offspring
  - Females have a **copulatory organ (vagina)** for receiving the sperm

Overview of the Reproductive System

- Reproductive system consists of **primary** and **secondary sex organs**
  - **Primary sex organs (gonads)**
    - Produce gametes (testes or ovaries)
  - **Secondary sex organs:** organs other than gonads that are necessary for reproduction
    - **Male—**system of ducts, glands; penis delivers sperm cells
    - **Female—**uterine tubes, uterus, and vagina receive sperm and harbor developing fetus

Overview of the Reproductive System

- **External genitalia—**located in the perineum
  - Externally visible (except accessory glands of female perineum)
- **Internal genitalia—**located in the pelvic cavity
  - Except testes and some associated ducts in the scrotum

Overview of the Reproductive System

- **Secondary sex characteristics**—features that distinguish the sexes and influence mate attraction
  - Develop at puberty
  - **Both sexes**
    - Pubic and axillary hair and their associated scent glands, and the pitch of the voice
  - **Male**
    - Facial hair, coarse and visible hair on the torso and limbs, relatively muscular physique
  - **Female**
    - Distribution of body fat, breast enlargement, and relatively hairless appearance of the skin

Androgen-Insensitivity Syndrome

- **Occasionally, a girl shows all the usual changes of puberty, but fails to menstruate**
  - Presence of testes in the abdomen
  - Karyotype of XY chromosomes
  - Testes produce normal male levels of testosterone
  - Target cells lack receptors for it
  - External genitalia develop female anatomy as if no testosterone were present
  - No uterus or menstruation

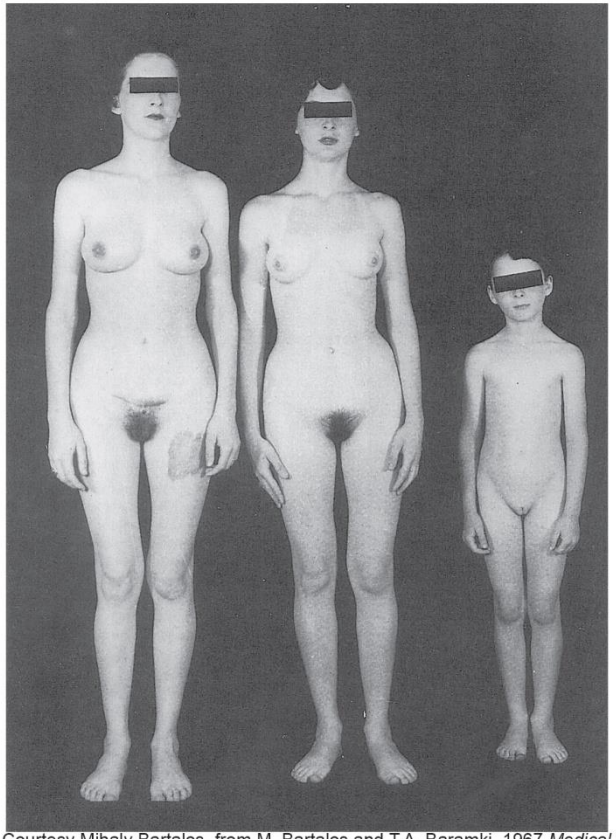

Courtesy Mihaly Bartalos, from M. Bartalos and T.A. Baramki, 1967 *Medical Cytogenetics*, Williams & Wilkins

Figure 27.1

Chromosomal Sex Determination

- **Our cells contain 23 pairs of chromosomes**
  - 22 pairs of autosomes
  - 1 pair of sex chromosomes (XY males; XX females)
    - Males produce half Y-carrying sperm and half X-carrying sperm
    - All eggs carry the X chromosome

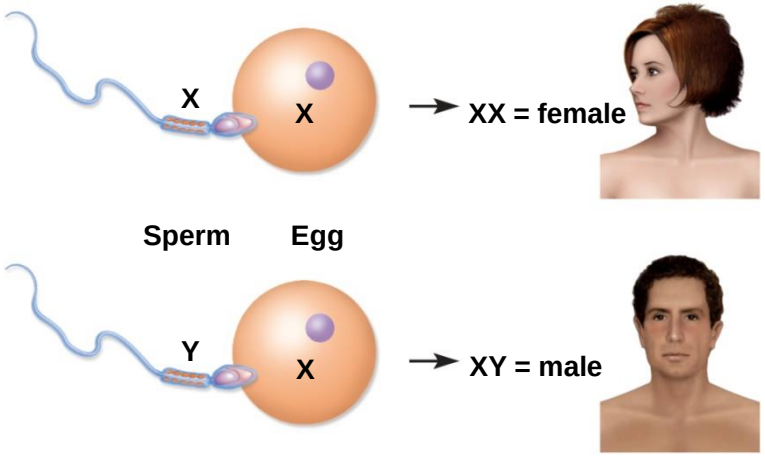

Figure 27.2

Chromosomal Sex Determination

- **Sex of child determined by type of sperm that fertilizes mother's egg**
  - X-carrying sperm fertilizes the egg: female
  - Y-carrying sperm fertilizes the egg: male

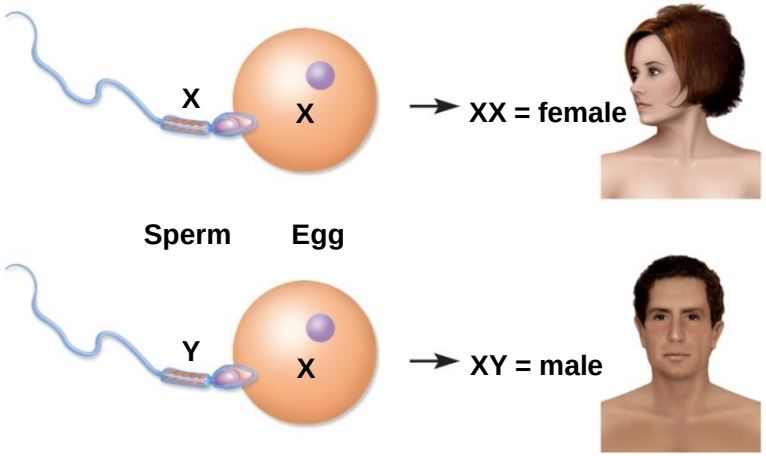

Figure 27.2

Prenatal Hormones and Sexual Differentiation

- Initially, a fetus is **sexually undifferentiated**
- **Gonads begin to develop at 5 or 6 weeks as gonadal ridges**
- **Two sets of ducts adjacent to each gonadal ridge**
  - In males, **mesonephric (wolffian) ducts** develop into reproductive tract; paramesonephric ducts degenerate
  - In females, **paramesonephric (müllerian) ducts** develop into reproductive tract; mesonephric ducts degenerate

Prenatal Hormones and Sexual Differentiation

- **SRY gene (sex-determining region of Y chromosome)** found only in males
  - SRY codes for a protein, **testes-determining factor (TDF),** that initiates development of testes
  - Testes begin to secrete testosterone at **8 to 9 weeks**
    - Stimulates mesonephric ducts to develop into male tracts
  - At same time, the testes secrete **müllerian-inhibiting factor** causing degeneration of the paramesonephric ducts

Prenatal Hormones and Sexual Differentiation

- **Estrogen levels** are always high in pregnancy
  - If estrogen was the hormone that directed female development, all fetuses would be feminized from mothers hormone

- Female development of a fetus occurs whenever there is an **absence of androgen hormones**
  - Not because estrogen is present

Development of Reproductive Tracts

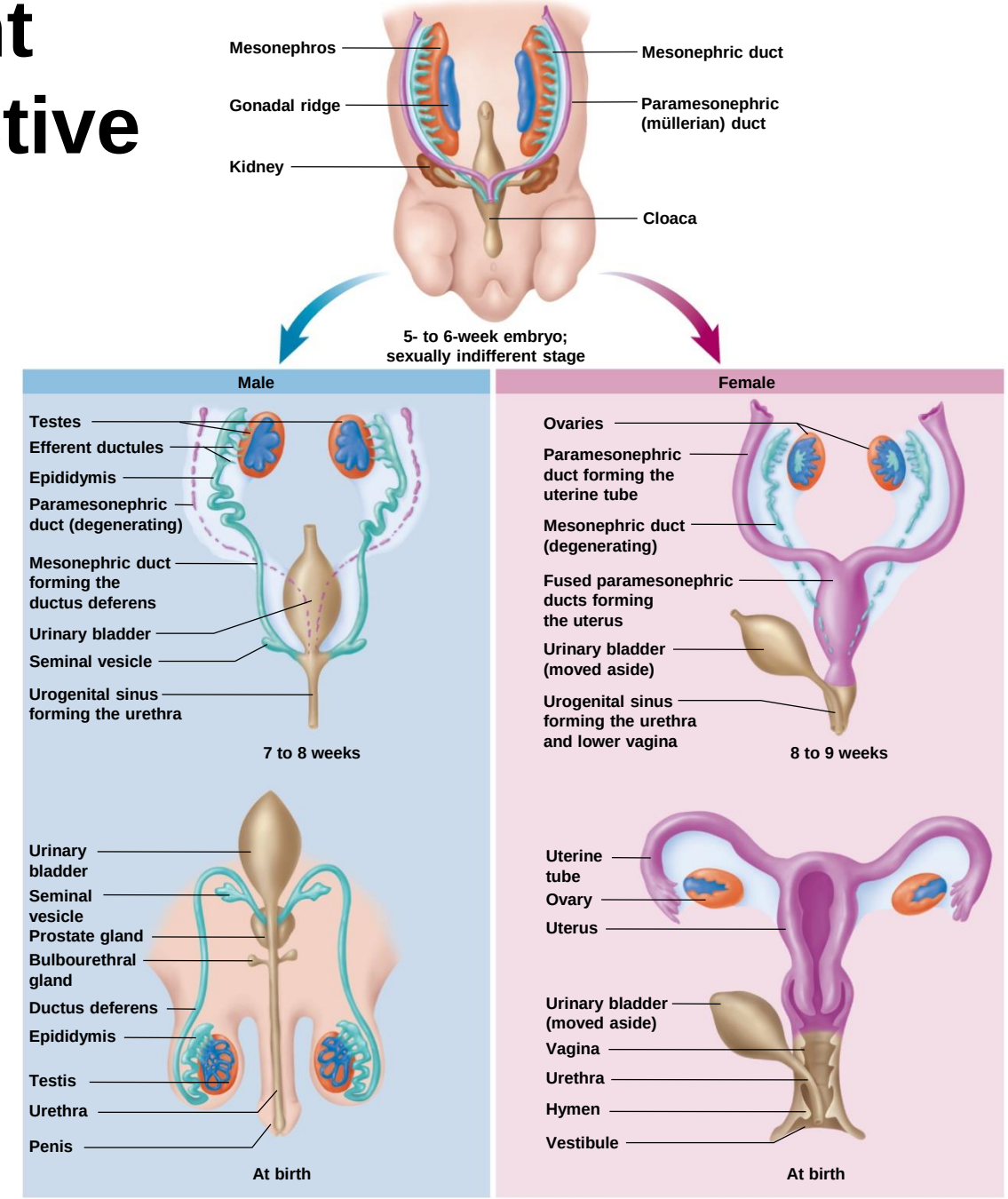

Figure 27.3

Development of the External Genitalia

- **Similar development of external genitalia of both sexes**
  - **Genital tubercle** becomes the head (glans) of the penis or glans clitoris
  - Pair of **urogenital folds** encloses male urethra helping to form the penis or forms the labia minora
  - Pair of **labioscrotal folds** becomes either scrotum or labia majora

Development of the External Genitalia

(Continued)

- **By week 12, either male or female genitalia are distinctly formed**
- Male and female organs that develop from the same embryonic structure are **homologous**
  - Penis is homologous to the clitoris
  - Scrotum is homologous to the labia majora

Development of External Genitalia

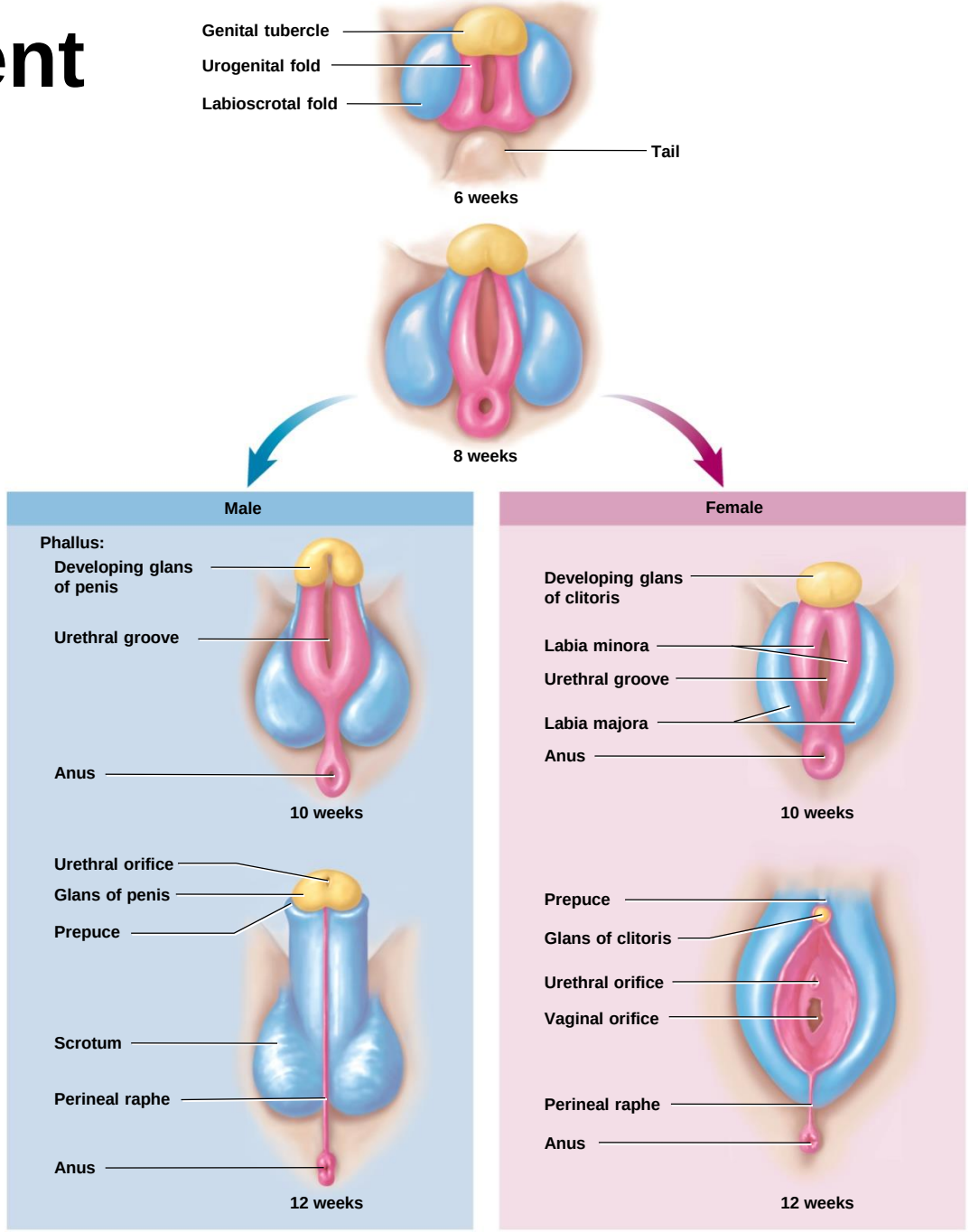

Figure 27.4

Descent of the Gonads

- **Gonads initially develop high in the abdominal cavity and then migrate into the pelvic cavity (ovaries) or scrotum (testes)**
  - **Gubernaculum**—embryonic connective tissue cord extending from gonad to pelvic cavity floor
    - In the male, it passes between the internal and external abdominal oblique muscles into the scrotal swelling
  - **Vaginal process:** fold of peritoneum that extends into the scrotum
  - **Inguinal canal:** pathway of low resistance through the groin created by gubernaculum and vaginal process
    - Most common site of hernia in males

Descent of the Gonads

- Descent of the testes begins as early as **6 weeks**
  - In **seventh month,** testes pass through the inguinal canal into the scrotum guided by the gubernaculum
  - Testes accompanied by elongating testicular arteries and veins, lymphatic vessels, nerves, spermatic ducts, and extensions of internal abdominal oblique muscle
- **Cryptorchidism**—undescended testes
  - Occurs in about 3% of male births
  - In most cases the testes descend during the first year of infancy
  - If not, testosterone injection or simple surgery can draw testes into the scrotum
  - Uncorrected cases lead to sterility or testicular cancer

Descent of the Gonads

- **Ovaries** descend to lesser extent
  - Lodge on inferior brim of the lesser pelvis
  - Gubernaculum becomes a pair of ligaments that supports the ovary and the uterus

Descent of the Testis

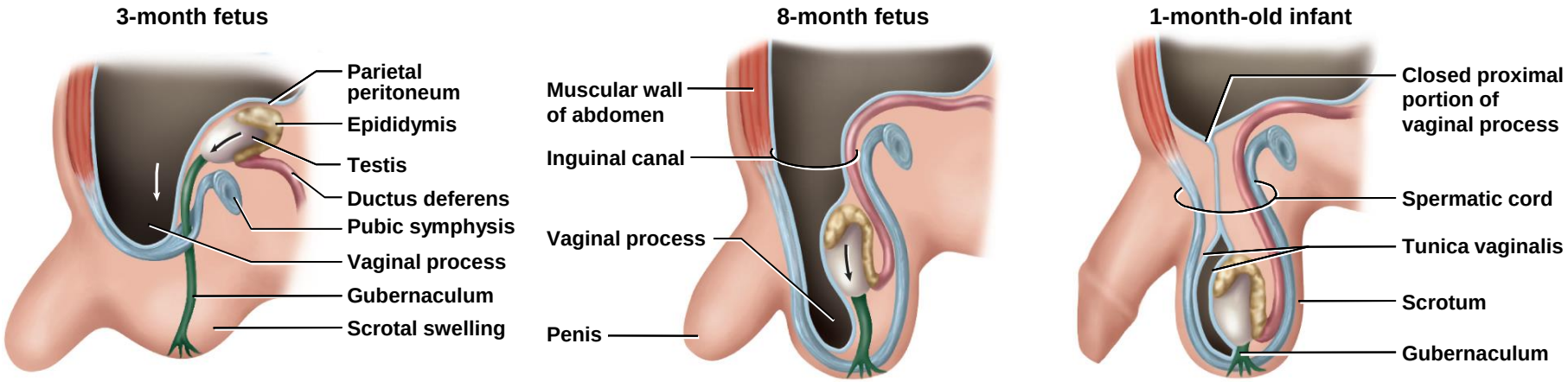

Figure 27.5

Male Reproductive Anatomy

- **Expected Learning Outcomes**
  - Describe the anatomy of the scrotum, testes, and penis.
  - Describe the pathway taken by a sperm cell from its formation to its ejaculation, naming all the passages it travels.
  - State the names, locations, and functions of the male accessory reproductive glands.

Male Reproductive Anatomy

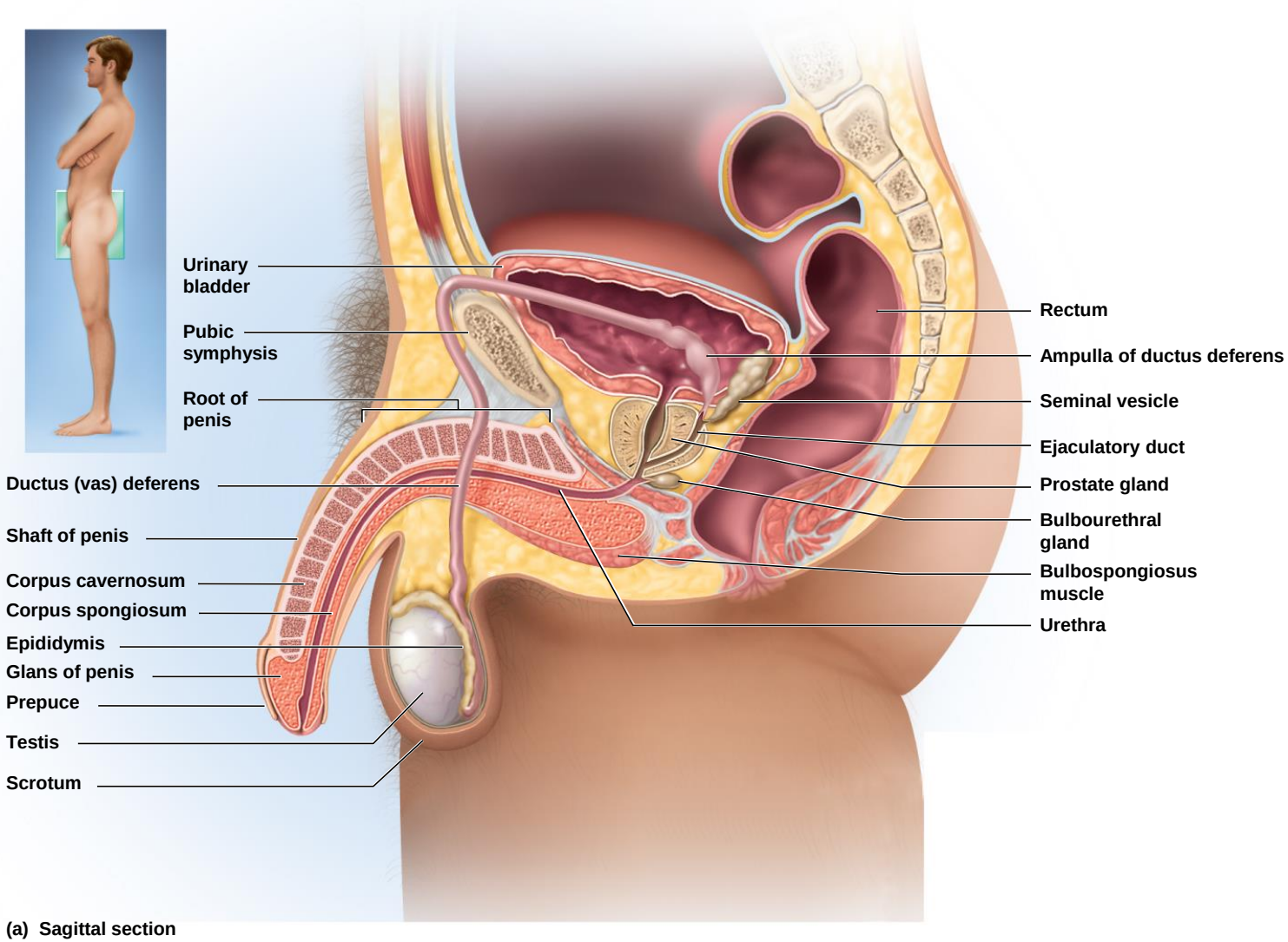

(a) Sagittal section

Figure 27.10a

The Scrotum

- **External genitalia** of the male—scrotum and penis
  - Occupy the **perineum:** diamond-shaped area between the thighs
    - Bordered by the pubic symphysis, ischial tuberosities, and coccyx

The Male Perineum

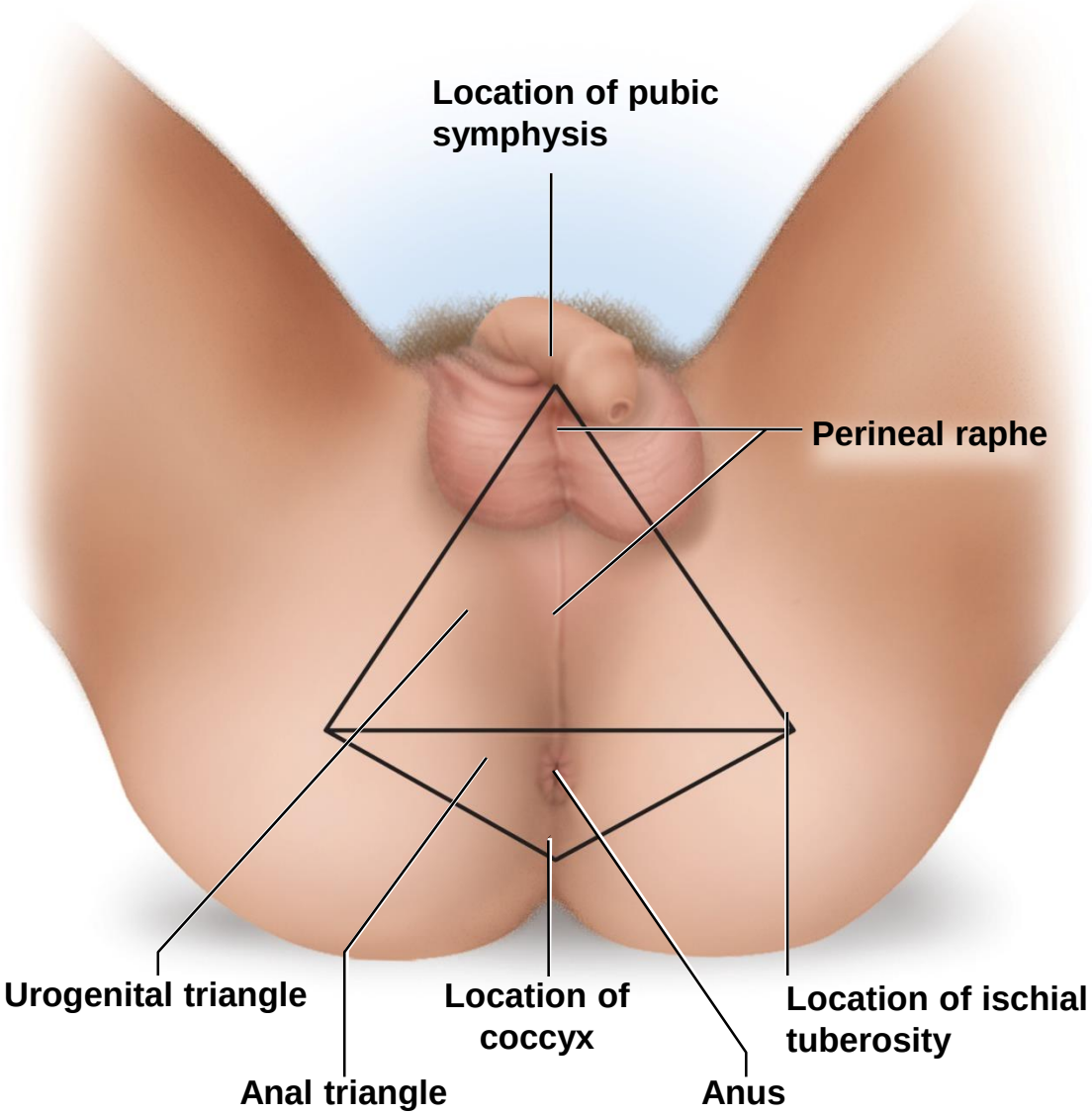

Figure 27.6

The Scrotum

- **Scrotum**—pouch of skin, muscle, and fibrous connective tissue containing the testes
  - **Left testicle** usually descends lower than the right so the two are not compressed against each other
  - **Skin** has sebaceous glands, sparse hair, rich sensory innervation, dark pigmentation
  - **Internal median septum** divides scrotum into right and left compartments
  - **Perineal raphe:** medial seam on scrotum surface that marks location of median septum
    - Extends anteriorly along ventral side of penis and posteriorly to anus

The Scrotum

- **Spermatic cord**—bundle of fibrous connective tissue containing the ductus deferens, blood and lymphatic vessels, and testicular nerve
  - Continues through inguinal canal into pelvic cavity
  - **External inguinal ring:** inferior entrance to inguinal canal
  - **Internal inguinal ring:** superior exit to pelvic cavity
- **Human testes reside in the scrotum because of its cooler environment**
  - Cannot produce sperm at core body temperature of 37°C
  - Must be held at about 35°C

The Scrotum

- **Scrotum has three mechanisms to regulate temperature of testes**
  - **Cremaster muscle:** strips of the internal abdominal oblique muscle
    - Enmesh the spermatic cord
    - In cold temperatures, contracts and draws testes upward toward body
    - In warm temperatures, relaxes suspending testes further from body
  - **Dartos muscle:** subcutaneous layer of smooth muscle
    - Contracts when cold, wrinkling the scrotum, holding testes against warm body
    - Reduces surface area of the scrotum and heat loss

The Scrotum

(Continued)

- **Pampiniform plexus:** an extensive network of veins from the testes that surrounds the testicular artery and spermatic cord
  - **Countercurrent heat exchanger—**without the pampiniform plexus, warm arterial blood would heat the testis and inhibit sperm production
  - Removes heat from the descending arterial blood
  - By the time it reaches the testis, the blood is 1.5° to 2.5°C cooler

The Scrotum and Spermatic Cord

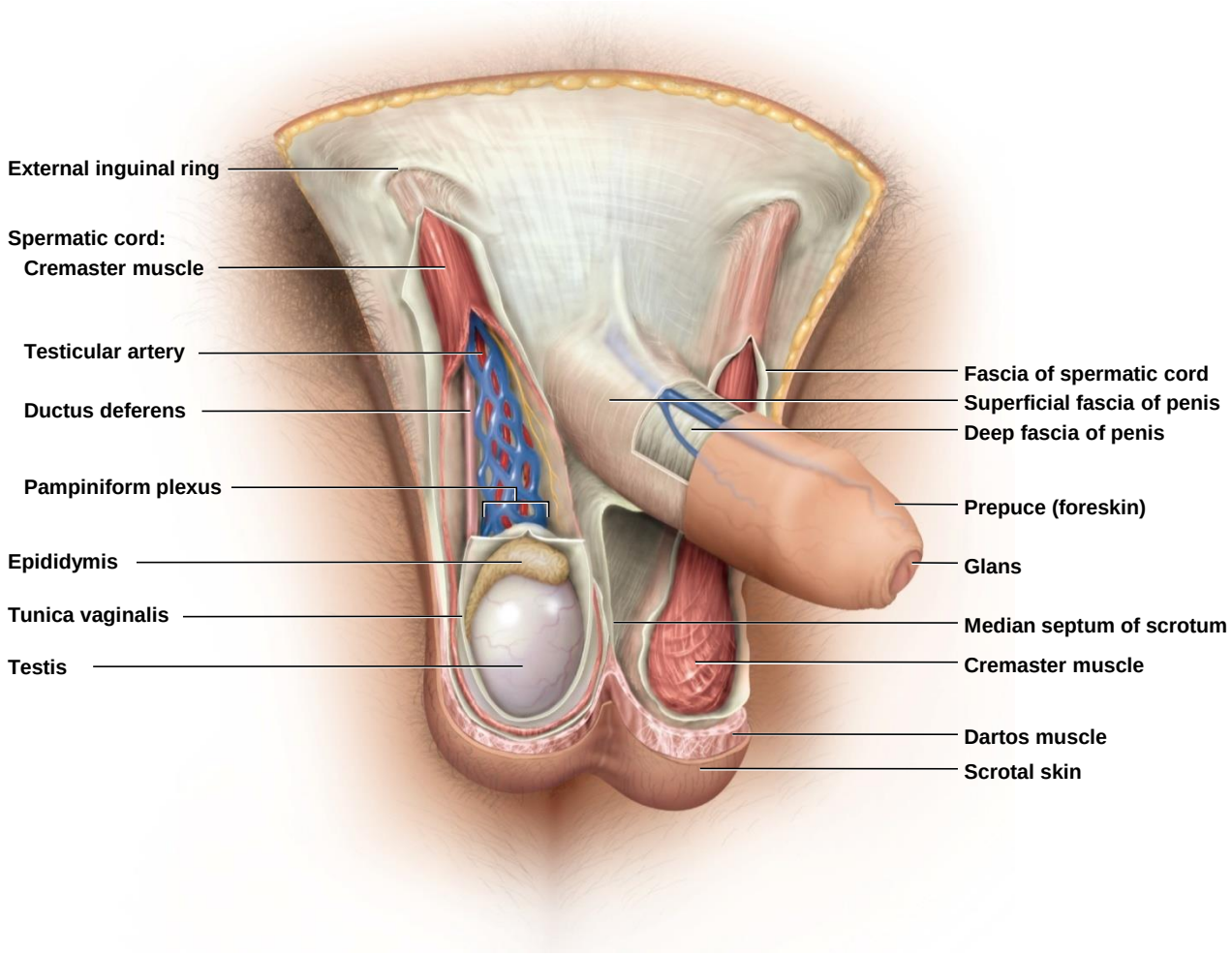

Figure 27.7

The Testes

- **Testes (testicles)**—combined endocrine and exocrine glands that produce **sex hormones** and **sperm**
- **Each testis: oval and slightly flattened, 4 cm long x 2.5 cm in diameter**
  - Covered anteriorly and laterally by tunica vaginalis
- **Tunica albuginea:** white fibrous capsule on testes
- Connective tissue septa divides testes into **250 to 300 wedge-shaped lobules**

The Testes

- **Seminiferous tubules—**ducts where sperm are produced
  - One to three in each lobule
  - Each tubule lined with a thick germinal epithelium of germ cells (becoming sperm) and sustentacular cells
  - **Sustentacular (Sertoli) cells** in between germ cells
    - Protect the germ cells, and promote their development
    - Germ cells depend on them for nutrients, waste removal, growth factors, and other needs
- **Interstitial (Leydig) cells** between tubules produce **testosterone**

The Testis and Associated Structures

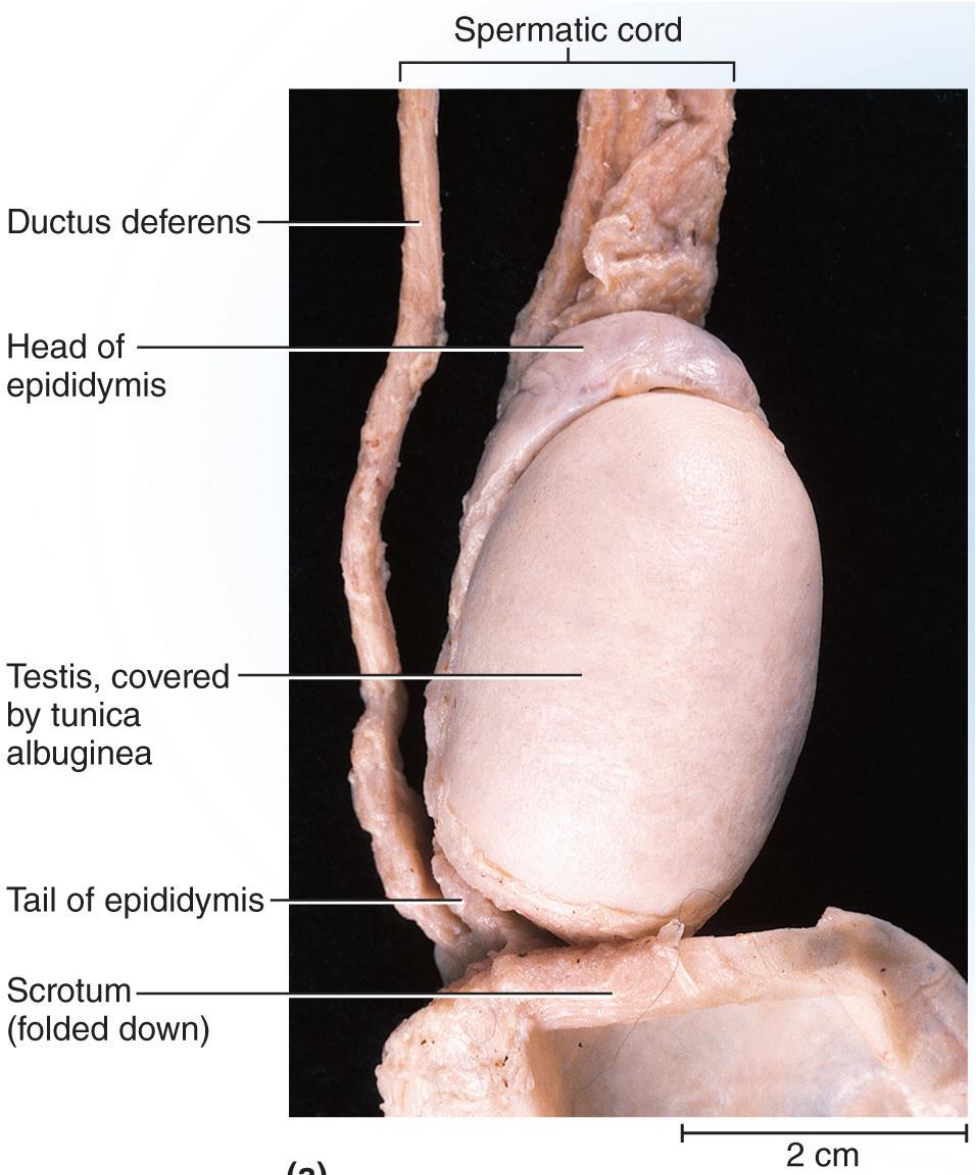

(a)

Figure 27.9a

The Testes

- **Blood–testis barrier (BTB)**—formed by tight junctions between **sustentacular cells**
  - Separates sperm from immune system
  - Prevents antibodies and other large molecules in the blood from getting to germ cells
  - Germ cells are immunologically different from body cells and would be attacked by the immune system

Histology of the Testis

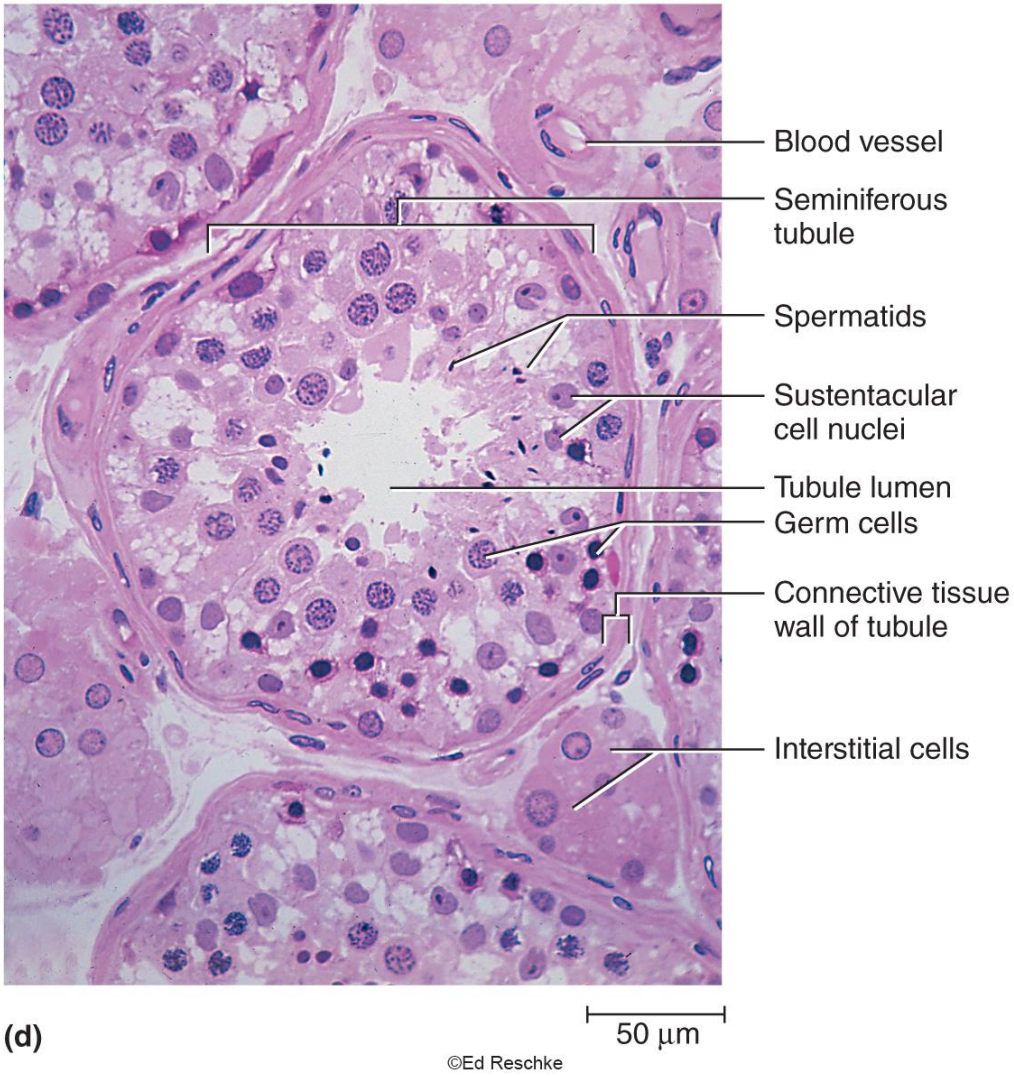

Figure 27.9d

The Testes

- **Rete testis**—a network on the posterior side of the testis that collects sperm from seminiferous tubules
  - Sperm flow with fluid secreted by **sustentacular cells**
  - Sperm do not swim while in the male reproductive tract

- A **testicular artery** supplies each testis
  - Low BP of testicular artery results in poor O_2 supply to the testes
  - Sperm develop large mitochondria to cope with poor oxygen supply and to help them survive hypoxic environment of female reproductive tract

The Testes

- Blood leaves the testes through the **pampiniform plexus** of veins which converge to form the **testicular veins**
  - Right testicular vein drains to inferior vena cava
  - Left one drains into left renal vein

- **Testicular nerves** from spinal cord segments T10 and T11
  - Carry sensory fibers concerned with pain and sympathetic fibers regulating blood flow

The Testis and Associated Structures

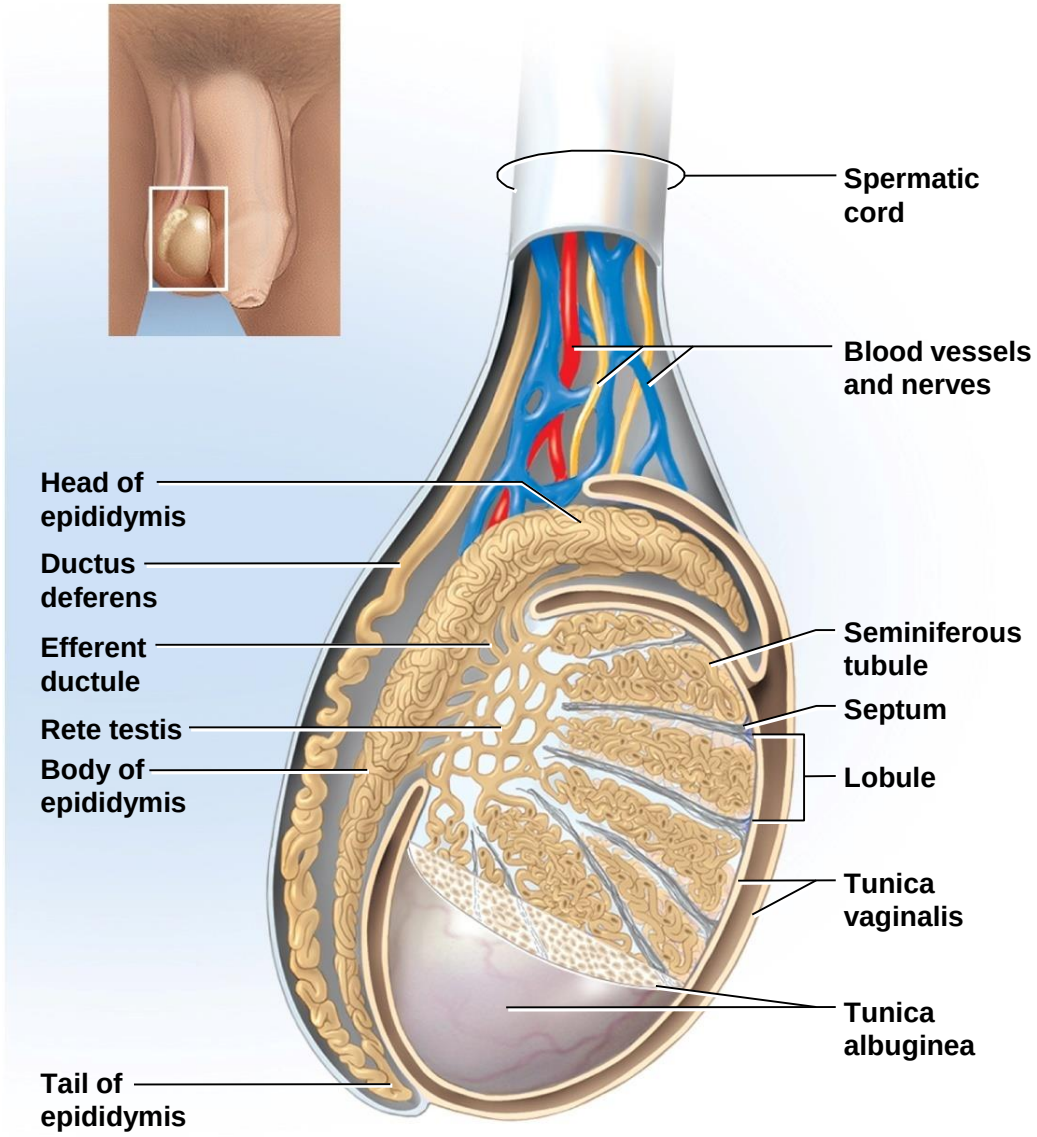

(b)

Figure 27.9b

The Spermatic Ducts

- **Spermatic ducts from testis to the urethra**
  - **Efferent ductules**
    - About 12 small ciliated ducts collecting sperm from rete testes and transporting it to epididymis
  - **Duct of the epididymis (head, body, and tail)**
    - Site of sperm maturation and storage (fertile for 40 to 60 days)
    - Contains a single coiled duct, 6 m long, adhering to posterior of testis
    - Sperm mature as they travel through the duct
    - If not ejaculated, they disintegrate and epididymis reabsorbs them

The Spermatic Ducts

(Continued)

- **Ductus (vas) deferens**
  - Muscular tube, 45 cm long, passing up from scrotum through inguinal canal to posterior surface of bladder
  - Duct widens behind the bladder and widens into the terminal **ampulla**
  - Duct ends by uniting with duct of the seminal vesicle
  - Thick wall of smooth muscle well innervated by sympathetic nerve fibers
- **Ejaculatory duct**
  - 2 cm duct formed from ductus deferens and seminal vesicle; passes through prostate to empty into **urethra**

The Spermatic Ducts

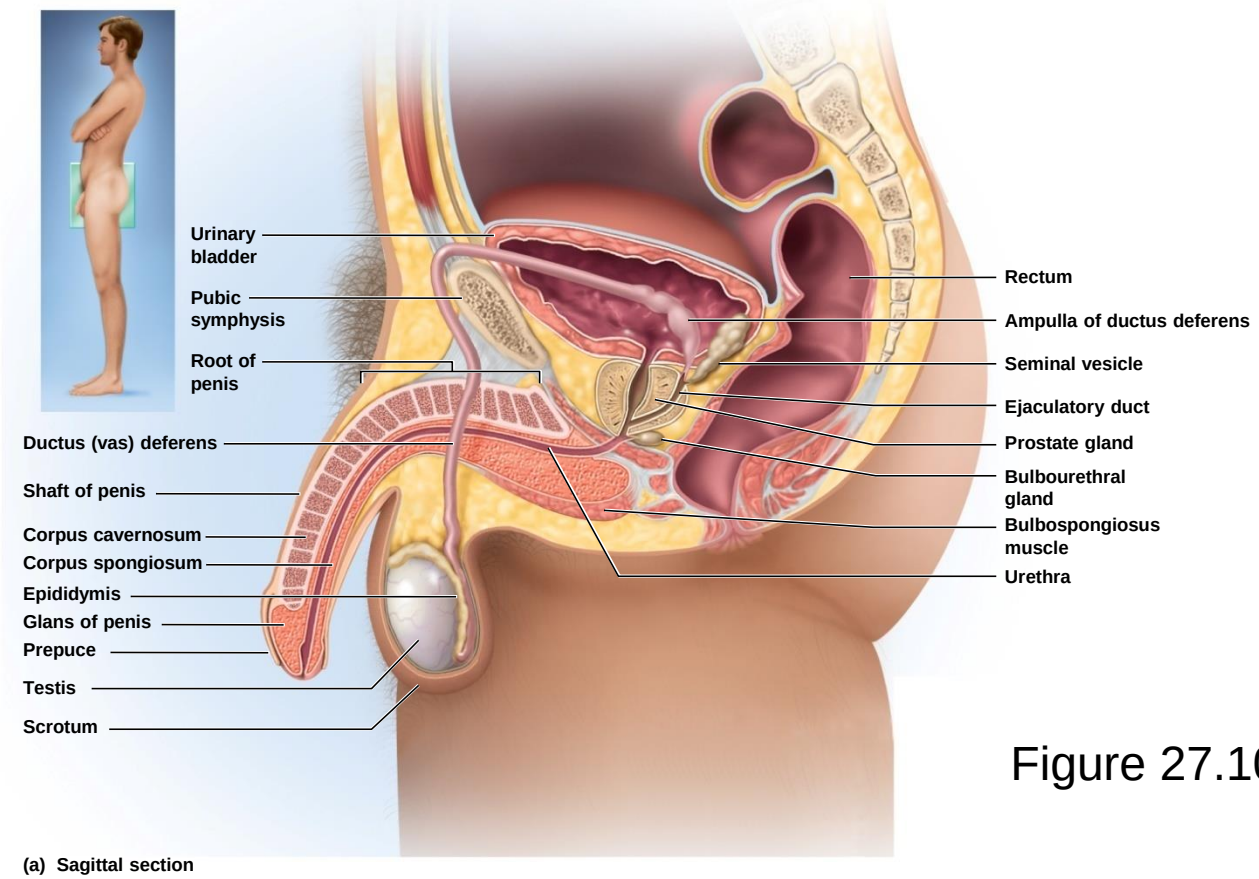

Figure 27.10a

- **Male urethra (18 cm long) is shared by reproductive and urinary systems**
- Consists of three regions: **prostatic, membranous,** and **spongy (penile) urethra**

The Spermatic Ducts

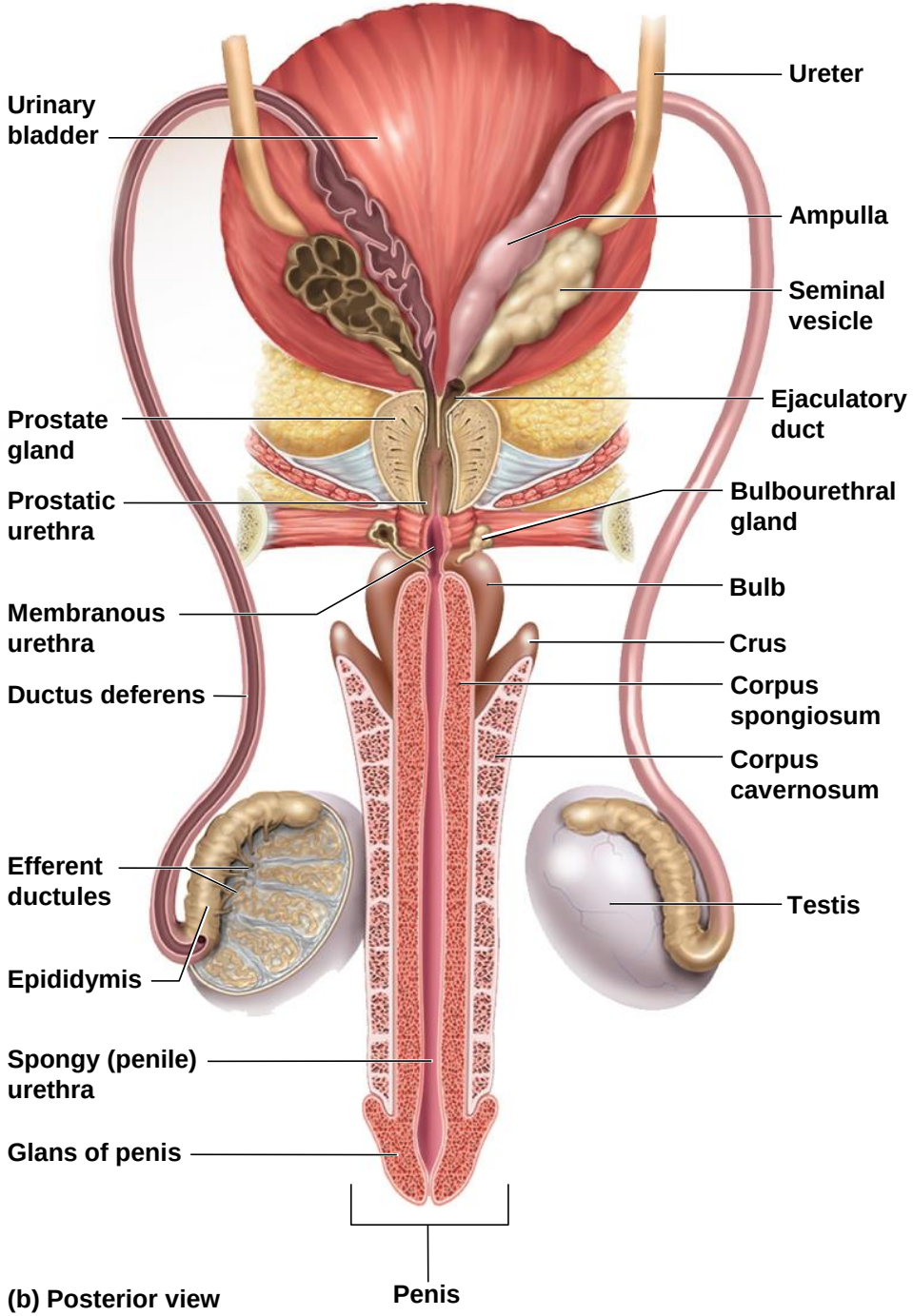

Figure 27.10b

The Accessory Glands

- **Three sets of accessory glands in male reproductive system: seminal vesicles, prostate gland, bulbourethral glands**
  - **Seminal vesicles**
    - Pair of glands posterior to bladder
    - Empties into ejaculatory duct
    - Forms 60% of semen
  - **Prostate gland**
    - Surrounds urethra and ejaculatory duct just inferior to the bladder
    - 30 to 50 compound tubuloacinar glands
    - Empty through about 20 pores in the prostatic urethra
    - Thin milky secretion forms 30% of semen

The Accessory Glands

(Continued)

- **Bulbourethral (Cowper) glands**
  - Near bulb of penis
  - During sexual arousal, they produce a clear slippery fluid that lubricates the head of the penis in preparation for intercourse
  - Protects the sperm by neutralizing the acidity of residual urine in the urethra

Prostate Diseases

- **Benign prostatic hyperplasia (BPH)**—noncancerous enlargement of the prostate
  - Compresses urethra and obstructs flow of urine
  - Promotes bladder and kidney infections

Prostate Diseases

- **Prostate cancer**
  - Second most common cancer in men after lung cancer
  - Tumors tend to be near the periphery of the gland where they do not obstruct urine flow
    - Go unnoticed until they cause pain
  - Metastasize to nearby lymph nodes and then to lungs and other organs
  - **Digital rectal exam (DRE):** palpated through rectal wall to check for tumors
  - Diagnosed from elevated levels of **serine protease (PSA)** and **acid phosphatase** in the blood

The Penis

- **Penis** serves to deposit semen in the vagina
  - Half of the penis is an internal **root**
  - Half is an externally visible **shaft** and **glans (head)**
  - External portion 4 in. long when **flaccid (nonerect)**
    - 5 to 7 in. long when erect
  - Skin over shaft loosely attaches to allow expansion
    - Extends over glans as **prepuce (foreskin)** that is removed by **circumcision**
      - Circumcision leads to development of less sensitive epidermis on glans
    - **Smegma—**waxy secretion produced by the sebaceous glands in the glans and facing surface of the prepuce

The Penis

- Three cylindrical bodies of **erectile tissue** fill with blood during sexual arousal and account for erection
  - Single **corpus spongiosum** along ventral side of penis
    - Encloses spongy (penile) urethra
    - Distal end enlarges and forms the glans penis
    - Proximal end is a dilated bulb ensheathed by **bulbospongiosus muscle**
  - Two **corpora cavernosa**
    - Diverge like arms of a Y
    - Each arm, called a **crus,** attaches penis to pubic arch
    - Covered with **ischiocavernosus muscle**

The Penis

- **The three cylinders of erectile tissue are spongy**
  - Contain many blood sinuses called **lacunae**
  - **Trabeculae:** partitions between lacunae

The Penis

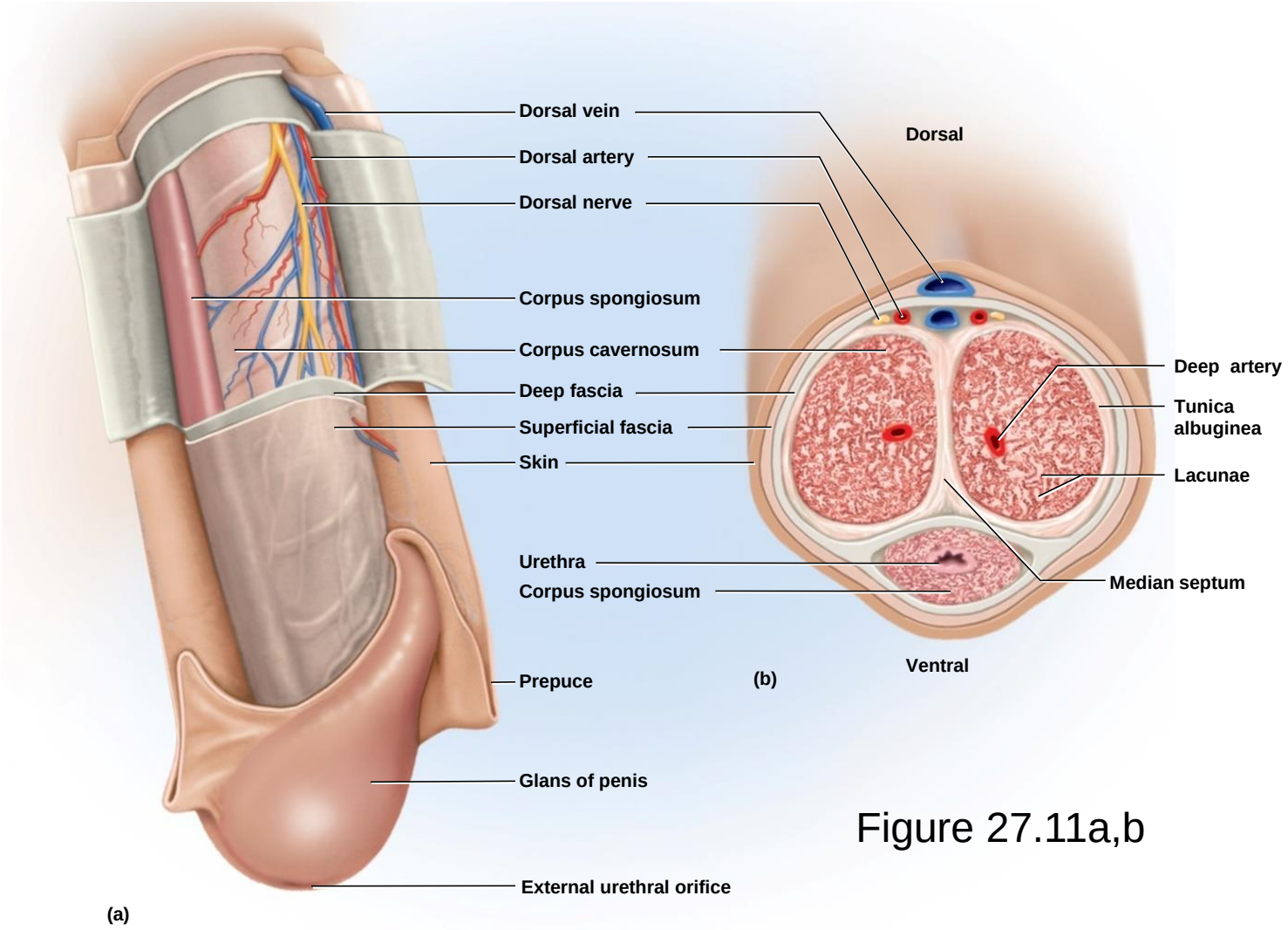

Figure 27.11a,b

Puberty and Climacteric

- **Expected Learning Outcomes**
  - Describe the hormonal control of puberty.
  - Describe the resulting changes in the male body.
  - Define and describe male climacteric and the effect of aging on male reproductive function.

Puberty and Climacteric

- **Reproductive system remains dormant for several years after birth**
  - 10 to 12 years in most boys; 8 to 10 years in most girls
  - **Surge of pituitary gonadotropins** awakens the reproductive system, leading to **onset of puberty**
- **Adolescence**—period from onset of gonadotropin secretion and reproductive development to when a person attains full adult height
- **Puberty**—first few years of adolescence, until the first menstrual period in girls or the first ejaculation of viable sperm in boys
  - Typically around age 14 in boys and age 12 in girls

Endocrine Control of Puberty

- **Testes secrete testosterone in first trimester of fetal development at levels about as high as they are in midpuberty**
  - Then testes becomes **dormant until puberty**
  - From puberty through adulthood, reproductive function is regulated by **hormonal links between the hypothalamus, pituitary gland, and gonads**

Endocrine Control of Puberty

- As hypothalamus matures it produces **gonadotropin-releasing hormone (GnRH)**
  - GnRH stimulates anterior pituitary cells **(gonadotropes)** to secrete:
    - **Follicle-stimulating hormone (FSH)**
      - Stimulates **sustentacular cells** to secrete **androgen-binding protein** that binds testosterone, keeping it in seminiferous tubule lumen to stimulate spermatogenesis
    - **Luteinizing hormone (LH)** sometimes called **interstitial cell–stimulating hormone (ICSH)**
      - Stimulates **interstitial cells** to produce **testosterone**

Endocrine Control of Puberty

- Puberty
  - **Growth** of sex organs
    - Penis, testes, scrotum, ducts, glands
  - Testosterone stimulates generalized body growth
    - Limbs elongate, muscle mass increases, and larynx enlarges
  - Erythropoiesis, basal metabolic rate, and increase in appetite
  - **Pubic hair, axillary hair, and facial hair** develop in response to dihydrotestosterone (DHT)
    - Associated scent and sebaceous glands also develop
  - Stimulates **sperm production** and **libido (sex drive)**

Endocrine Control of Puberty

- **Adulthood**
  - Testosterone sustains the male reproductive tract, sperm production, and libido
  - **Inhibin** from sustentacular cells suppresses FSH output from the pituitary, reducing sperm production without reducing LH and testosterone secretion

Hormonal Relationships

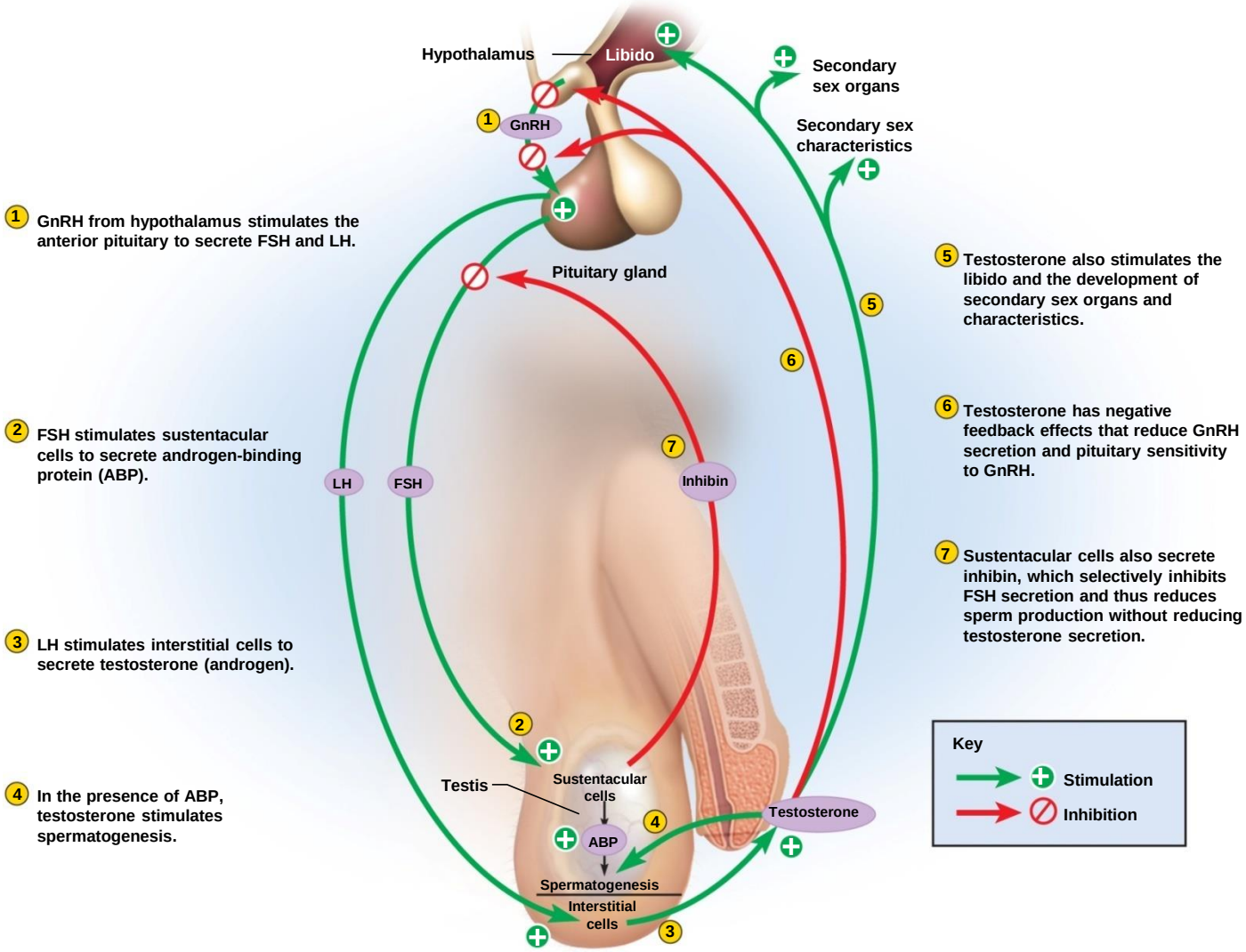

Figure 27.12

Aging and Sexual Function

- **Testosterone secretion declines with age**
  - Peak secretion at 7 mg/day at age 20; declines to one-fifth of that by age 80
    - Decline in number and activity of interstitial cells
- **Male climacteric (andropause)** may occur
  - A period of declining reproductive function that may be first seen in early 50s
  - Although sperm counts decline, men can still father children throughout old age

Aging and Sexual Function

- **Age-related drop in testosterone and inhibin triggers a rise in FSH and LH**
  - Although most men do not notice this, some experience mood changes, hot flashes, “illusions of suffocation”
- **Erectile dysfunction (impotence)**—the inability to produce or maintain an erection sufficient for intercourse
  - 20% of men in 60s to 50% of those in 80s

Sperm and Semen

- **Expected Learning Outcomes**
  - Describe the stages of meiosis and contrast meiosis with mitosis.
  - Describe the sequence of cell types in spermatogenesis, and relate these to the stages of meiosis.
  - Describe the role of the sustentacular cell in spermatogenesis.
  - Describe or draw and label a sperm cell.
  - Describe the composition of semen and functions of its components.

Sperm and Semen

- **Spermatogenesis**—process of sperm production in seminiferous tubules
- **Involves three principal events**
  - Division and remodeling of large germ cells into small, mobile sperm cells with flagella
  - Reduction of chromosome number by one-half
  - Shuffling of genes so each chromosome contains new gene combinations that did not exist in parent
    - Ensures genetic variation in the offspring
- **Meiosis recombines genes and reduces chromosome number, while producing four daughter cells that will become sperm**

Meiosis

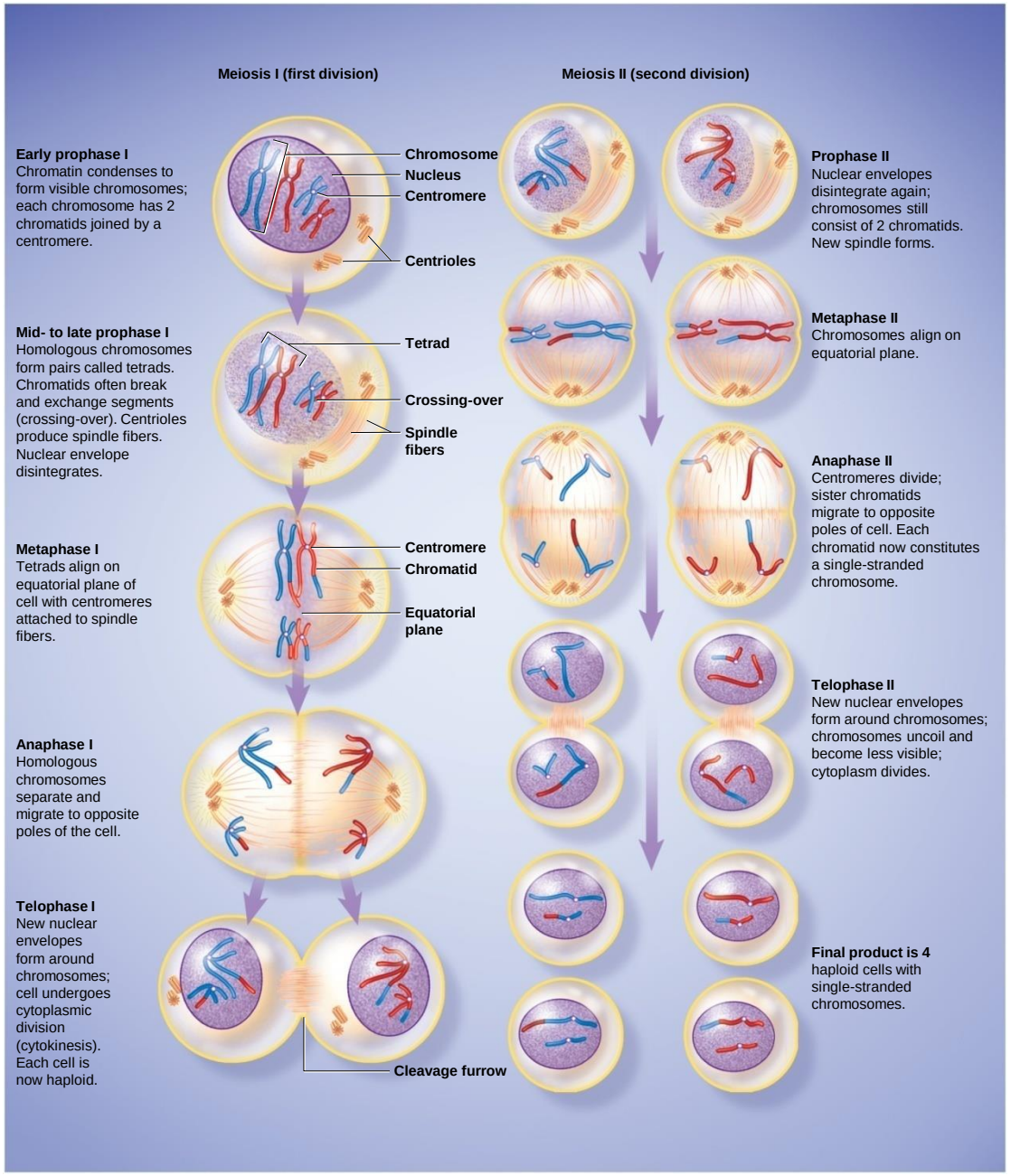

Figure 27.13

Meiosis

- **Two forms of cell division**
  - **Mitosis:** a body cell doubles its DNA and then divides to produce two genetically identical daughter cells
    - Basis for division of single-cell fertilized egg, growth of an embryo, all postnatal growth, and tissue repair
    - Consists of four stages: prophase, metaphase, anaphase, telophase
  - **Meiosis** produces four gametes (haploid cells), each with only half the DNA of the diploid body cells
    - Combining male and female gametes with half the genetic material produces an embryo with the same number of chromosomes as each of the parents
    - Meiosis is sometimes called **reduction division**

Meiosis

- **Meiosis has two cell** divisions (following one replication of DNA) with each division having four stages
  - Meiosis I: prophase I, metaphase I, anaphase I, and telophase I
    - Before this begins, the DNA is doubled
    - Prophase I: each pair of homologous chromosomes lines up side by side and forms a **tetrad**
    - **Crossing-over** creates new combinations of genes
    - After meiosis I, each cell has 23 chromosomes, but each chromosome is double-stranded

Meiosis

(Continued)

- Meiosis II: prophase II, metaphase II, anaphase II, and telophase II
  - More like mitosis
  - Each of double-stranded chromosomes divides into two chromatids, and these separate
  - At the end, each cell contains 23 single-stranded chromosomes

Spermatogenesis

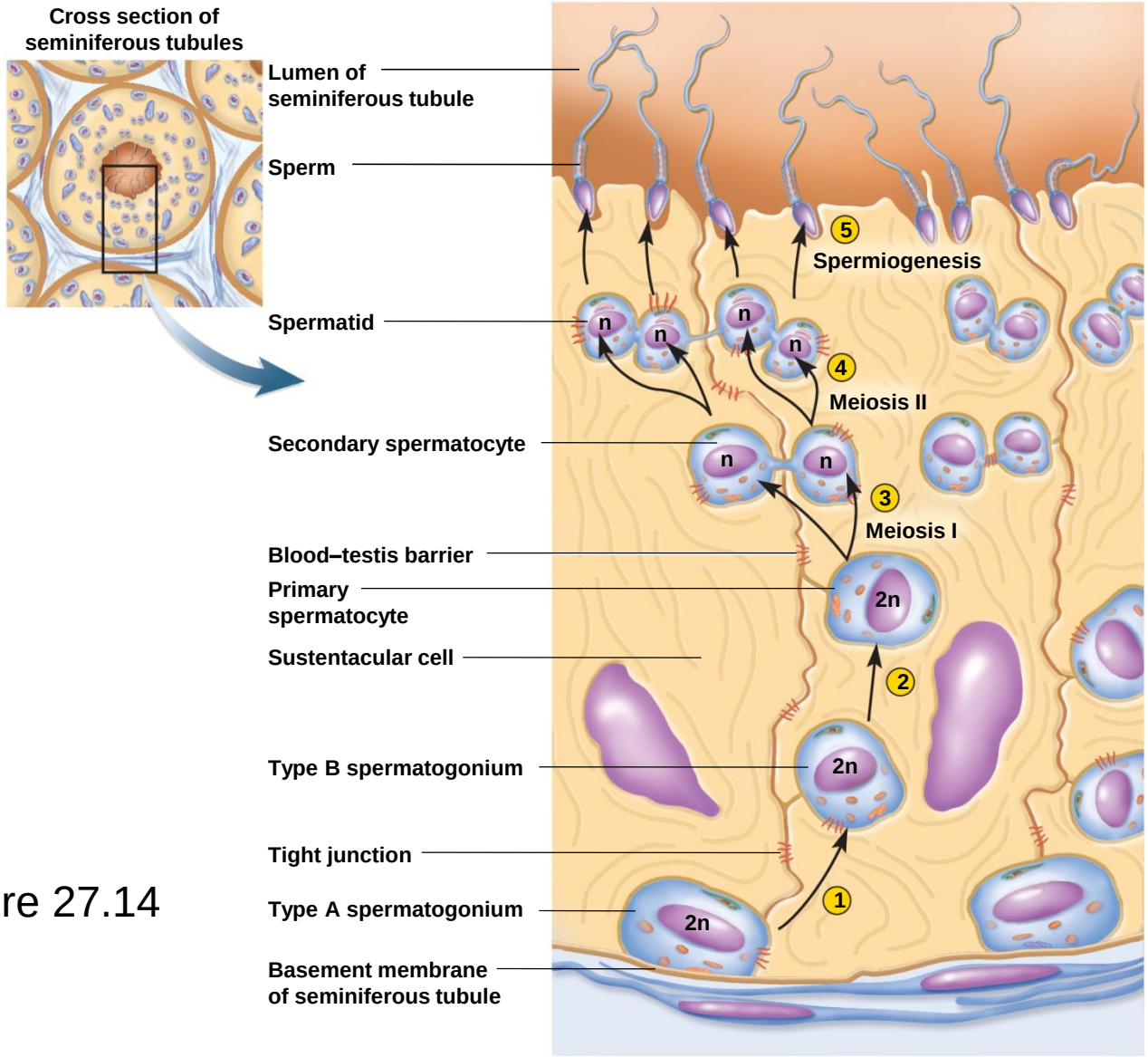

Figure 27.14

Spermatogenesis

- **Primordial germ cells** form in yolk sac of embryo
  - Colonize gonadal ridges and become **spermatogonia**
- **Puberty brings on spermatogenesis**
  - **Spermatogonia** lie along periphery of seminiferous tubules and divide by mitosis
  - One daughter cell of each division remains in tubule wall as stem cell: **type A spermatogonium**
  - Other daughter cell migrates away from wall and is on its way to producing sperm: **type B spermatogonium**

Spermatogenesis

(Continued)

– **Type B spermatogonium** enlarges and becomes a **primary spermatocyte**
  - Sustentacular cells protect it from the body's immune system: blood–testis barrier (BTB)
  - Primary spermatocyte undergoes meiosis I which gives rise to two equal-size, haploid, genetically unique **secondary spermatocytes**
  - Each secondary spermatocyte undergoes meiosis II dividing into two **spermatids**—a total of four for each spermatogonium
  - **Spermiogenesis**—four spermatids undergo transformations in which they differentiate into a **spermatozoa**

Spermatogenesis

- When a primary spermatocyte undergoes meiosis, it becomes genetically different and needs to be protected from the immune system
- The primary spermatocyte moves toward the lumen of the seminiferous tubule and a new tight junction between sustentacular cells forms behind it
- Now protected by the blood–testis barrier closing behind it

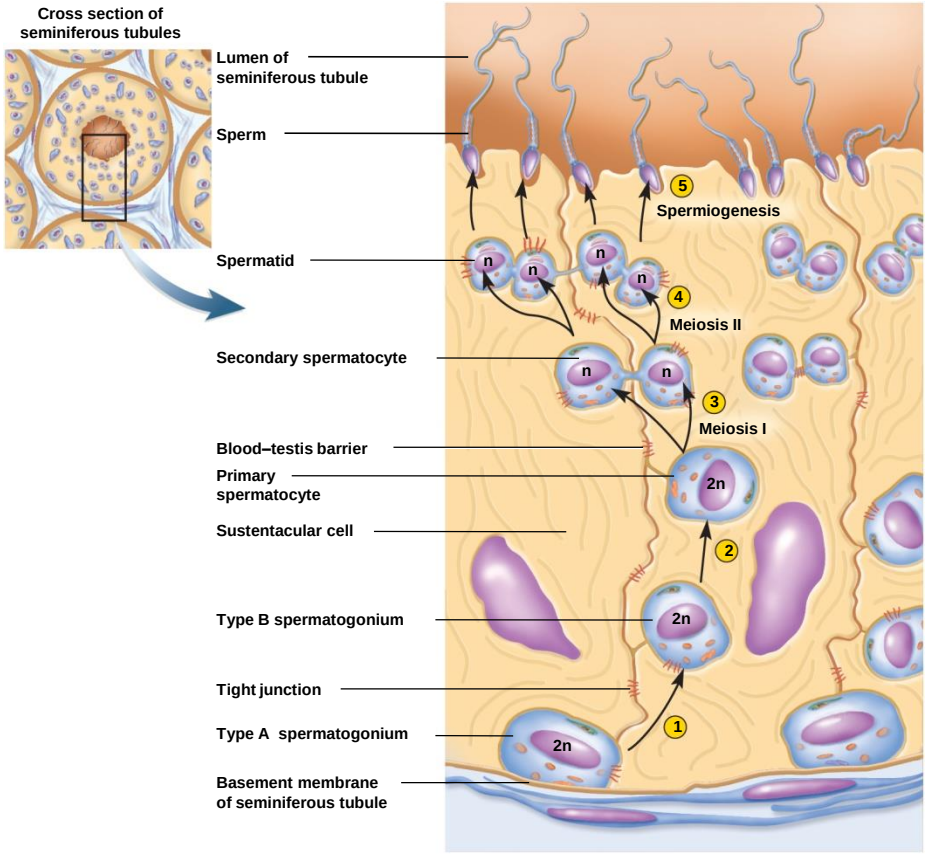

Figure 27.14

Spermatogenesis

- **Spermiogenesis—changes that transform spermatids into spermatozoa**
  - Discarding excess cytoplasm and growing tails

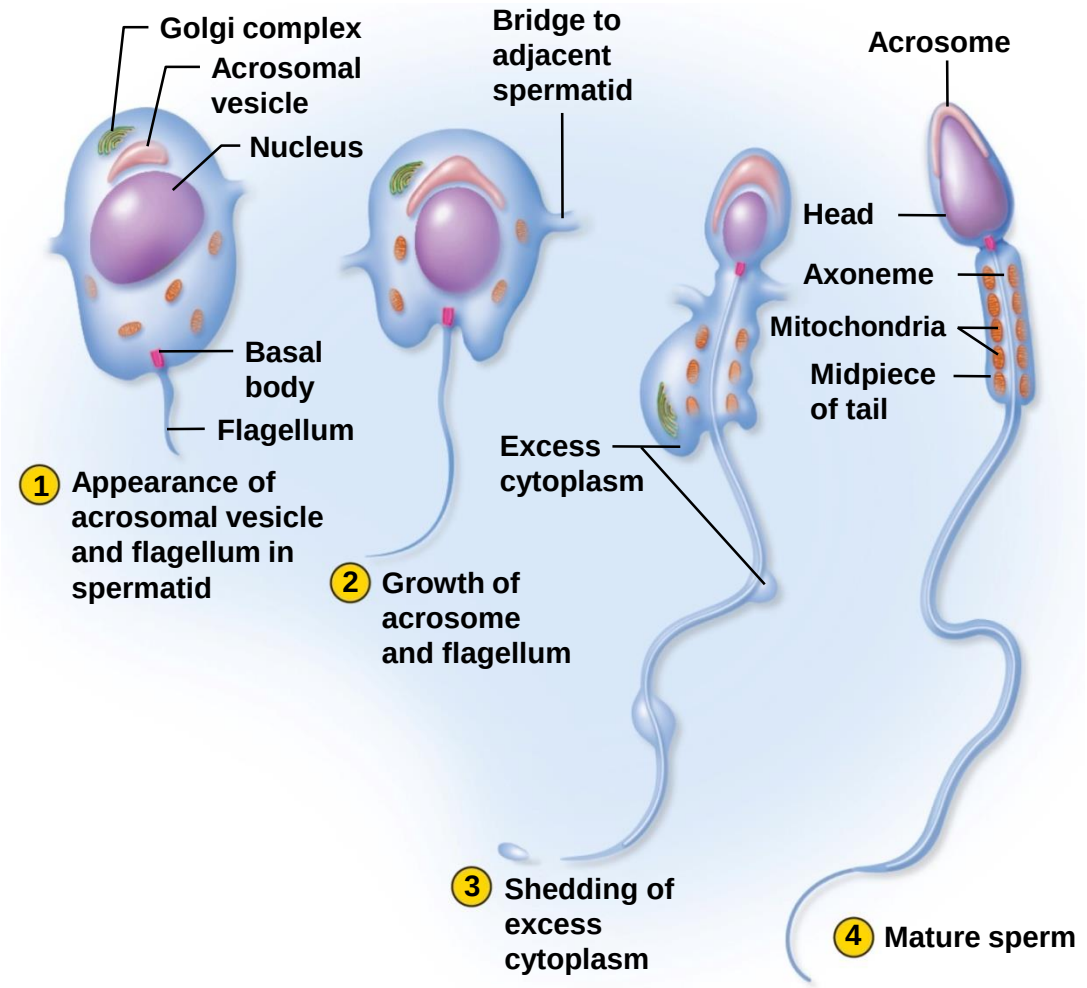

Figure 27.15

The Spermatozoon

- **Spermatozoon** has two parts: head and tail
  - **Head** is pear-shaped
    - 4 to 5 μm long; structure contains nucleus, acrosome, and basal body of tail flagellum
    - **Nucleus** contains haploid set of chromosomes
    - **Acrosome—**enzyme cap over the apical half of the nucleus that contains enzymes that penetrate the egg
    - **Basal body—**indentation in the basal end of the nucleus where flagellum attaches

The Spermatozoon

- **Tail** is divided into three regions
  - **Midpiece** contains mitochondria around axoneme of the flagella, produces ATP for flagellar movement
  - **Principal piece** is axoneme surrounded by sheath of supporting fibers
    - Constitutes most of tail
  - **Endpiece** is very narrow tip of flagella

The Mature Spermatozoon

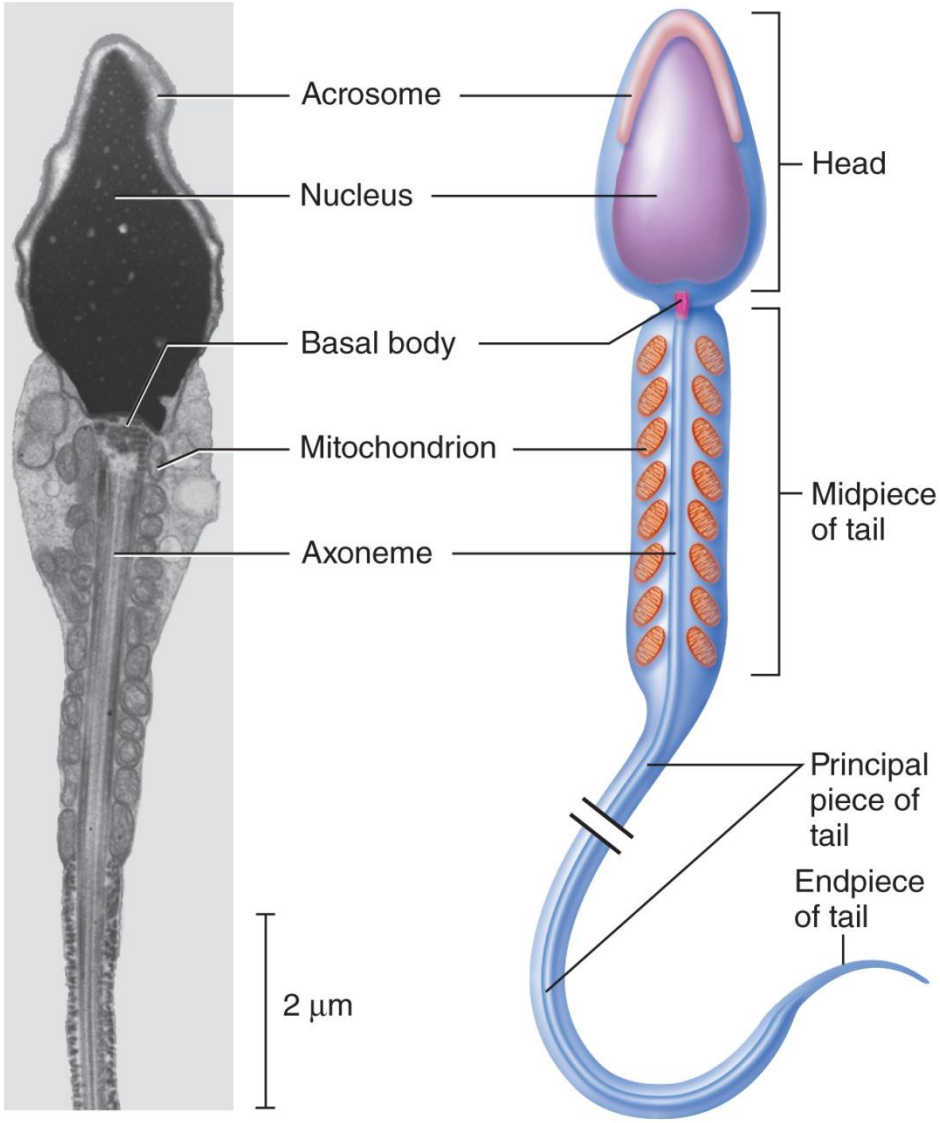

a: ©David Phillips/Visuals Unlimited

Figure 27.16a,b

Semen

- **Semen (seminal fluid)—**fluid expelled during orgasm
- 2 to 5 mL of fluid expelled during ejaculation
  - 60% seminal vesicle fluid, 30% prostatic fluid, and 10% sperm and spermatic duct secretions
    - Normal **sperm count** 50 to 120 million/mL
    - Lower than 20 to 25 million/mL: **infertility**

Semen

(Continued)

– **Prostate** produces a thin, milky white fluid
  - Contains calcium, citrate, and phosphate ions
  - Clotting enzyme
  - Protein-hydrolyzing enzyme called serine protease (prostate-specific antigen)

– **Seminal vesicles** contribute viscous yellowish fluid
  - Contains fructose and other carbohydrates, citrate, prostaglandins, and protein called **proseminogelin**

Semen

(Continued)

– **Stickiness** of semen promotes fertilization
  - Clotting enzyme from prostate activates **proseminogelin**
  - Converts it to a sticky fibrin-like protein: **seminogelin**
  - Entangles the sperm
  - Sticks to the inner wall of the vagina and cervix
  - Ensures semen does not drain back into vagina
  - Promotes uptake of sperm-laden clots of semen into the uterus
  - 20 to 30 minutes after ejaculation, serine protease from prostatic fluid breaks down seminogelin, and liquifies the semen

Semen

(Continued)

- Two requirements for **sperm motility: elevated pH** and an **energy source**
  - Prostatic fluid buffers vaginal acidity from pH 3.5 to 7.5
  - Seminal vesicles provide fructose and other sugars to the mitochondria of sperm for ATP production
- Active sperm crawl up vagina and uterus
- Prostaglandins in semen may thin the mucus of the cervical canal and may stimulate waves of contractions in uterus and uterine tubes to spread the semen

Reproductive Effects of Pollution

- **Endocrine disrupting chemicals (EDCs)**—environmental agents that interfere with hormones
  - Found in a wide variety of products
  - Exposure comes through food, water, air, soil, household items, workplace chemicals
  - Effects may be long lasting (for generations)
    - Genetic and epigenetic effects
  - It is extremely difficult to prove the link between a suspected disruptor and a reproductive disorder, but the problem demands further investigation

Male Sexual Response

- **Expected Learning Outcomes**
  - Describe the blood and nerve supply to the penis.
  - Explain how these govern erection and ejaculation.

Male Sexual Response

- **Publication of research by William Masters and Virginia Johnson (1966)**
  - Divided intercourse into **four recognizable phases**
    - **Excitement**
    - **Plateau**
    - **Orgasm**
    - **Resolution**
  - Led to therapy for sexual dysfunction
  - Sexual intercourse is also known as **coitus, coition,** or **copulation**

Anatomical Foundations

- **Internal pudendal (penile) artery** enters root of the penis and divides in two
  - **Dorsal artery:** travels under skin on dorsal surface
    - Supplies blood to skin, fascia, and corpus spongiosum
    - When penis is flaccid, most blood comes from dorsal artery
  - **Deep artery** travels through the core of the corpus cavernosa
    - Gives off smaller helicine arteries that penetrate the trabeculae and enter lacunae
    - Dilation of deep artery fills lacunae causing an erection
  - Many anastomoses unite deep and dorsal arteries
- **Deep dorsal vein** drains blood from penis

Anatomical Foundations

- **Penis is richly innervated**
  - The glans has an abundance of tactile, pressure, and temperature receptors
  - **Dorsal nerves** of penis and **internal pudendal nerves** lead to sacral spinal cord
  - Both autonomic and somatic motor fibers carry impulses from spinal integrating center to penis
    - **Sympathetics** help induce erection in response to input from special senses and sexual thoughts
    - **Parasympathetics** induce an erection in response to direct stimulation of the penis

Excitement and Plateau

- **Excitement phase** is characterized by vasocongestion (swelling of genitals with blood), myotonia (muscle tension), and increases in heart rate, blood pressure, and pulmonary ventilation
  - Bulbourethral glands secrete fluid
  - Initiated by a broad spectrum of erotic stimuli
  - Erection is primarily due to parasympathetic triggering of nitric oxide (NO) secretion
  - Dilation of deep arteries and filling of lacunae with blood
  - Vasocongestion can also cause testes to become 50% larger during excitement
  - Erection allows for **intromission (entry)** into vagina

Excitement and Plateau

- **Plateau phase**—variables such as respiratory rate, heart rate, and blood pressure stay increased
  - Marked increased vasocongestion and myotonia
  - Lasts for a few seconds or a few minutes before orgasm

Neural Control of Male Sexual Response

- **Parasympathetic signals produce an erection with direct stimulation of the penis or perineal organs**

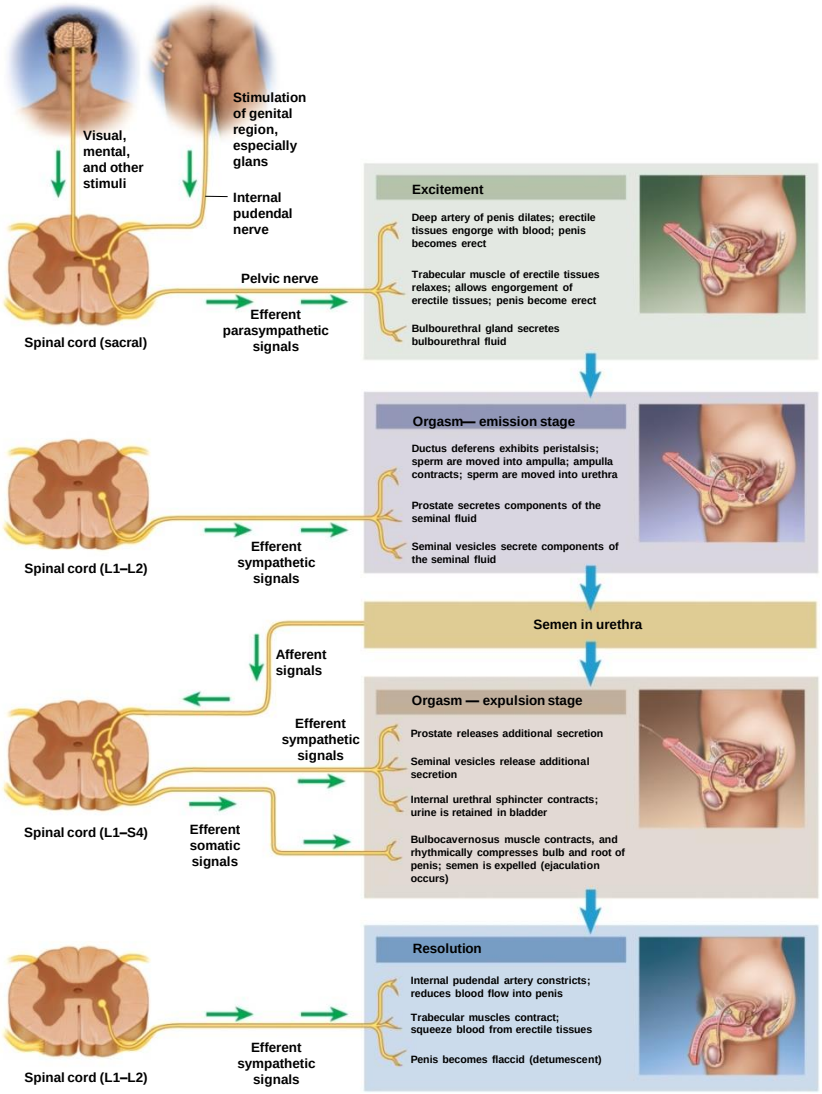

Figure 27.17

Orgasm and Ejaculation

- **Orgasm** or **climax—**a short but intense reaction that is usually marked by the discharge of semen
  - Lasts 3 to 15 seconds
  - Heart rate, blood pressure, and breathing greatly elevate

Orgasm and Ejaculation

- **Ejaculation occurs in two stages**
  - **Emission:** sympathetic nervous system stimulates peristalsis which propels sperm through ducts as glandular secretions are added
  - **Expulsion:** semen in urethra activates somatic and sympathetic reflexes that stimulate muscular contractions that lead to expulsion
    - Sympathetic reflex constricts internal urethral sphincter so urine cannot enter urethra and semen cannot enter bladder
- **Ejaculation and orgasm are not the same**
  - Usually occur together, but can occur separately

Resolution

- **Resolution phase**—body variables return to preexcitement state
  - Sympathetic signals constrict internal pudendal artery and reduce blood flow to penis
  - Penis becomes soft and flaccid **(detumescence)**
  - Cardiovascular and respiratory functions return to normal
- **Refractory period**—period following resolution in which it is usually impossible for a male to attain another erection or orgasm
  - May last from 10 minutes to a few hours

Treating Erectile Dysfunction

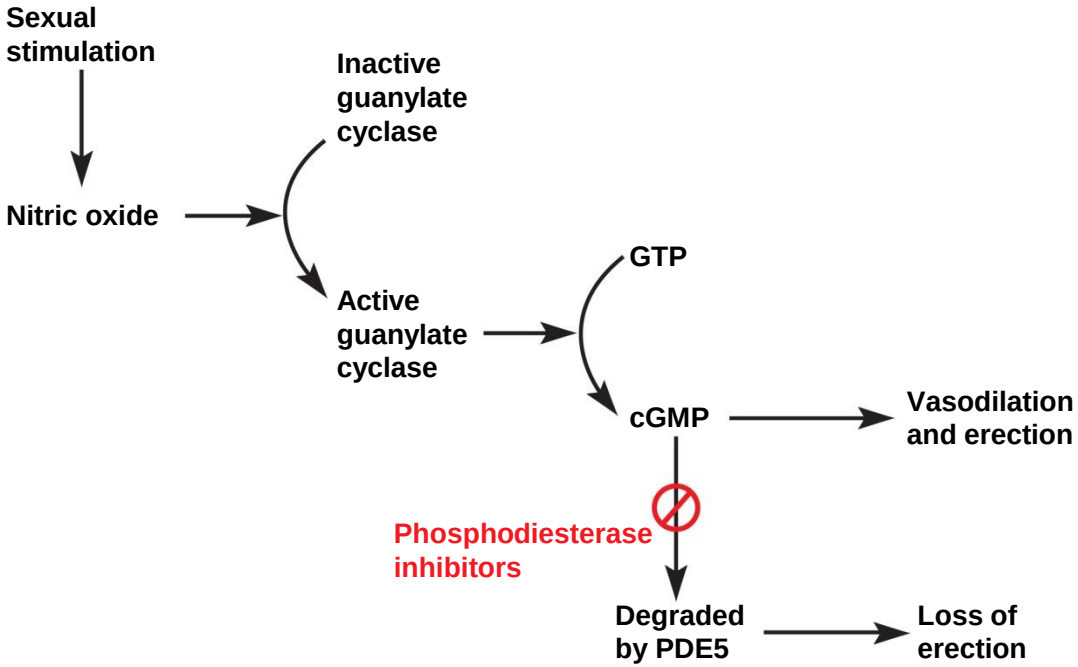

Figure 27.18

- **Treatments—Viagra®, Levitra®, and Cialis®**
  - Phosphodiesterase inhibitors
- Sexual stimulation triggers **nitric oxide** secretion, which activates **cGMP,** which then increases blood flow into erectile tissue
  - These drugs slow breakdown of **cGMP** by **phosphodiesterase type 5 (PDE5)** and prolong duration of erection

Sexually Transmitted Diseases

- Many STDs have an **incubation period** in which the pathogen multiplies with no symptoms and a **communicable period** in which the disease can be transmitted to others
  - Symptomless carriers do exist

Sexually Transmitted Diseases

- **Bacterial STDs**
  - **Chlamydia:** may cause urethral discharge and testicular pain
  - **Gonorrhea:** pain and pus discharge; may result in sterility from pelvic inflammatory disease
  - **Syphilis:** hard lesions (chancres) at site of infection
    - Disappearance of chancres ends first stage
    - Second stage is widespread pink rash
    - Neurosyphilis is third stage with cardiovascular damage and brain lesions

Sexually Transmitted Diseases

- **Viral STDs**
  - **Genital herpes:** most common STD in United States
    - Blisters and pain
  - **Genital warts:** warts on perineal region, cervix, anus
  - **Hepatitis B and C:** inflammatory liver disease