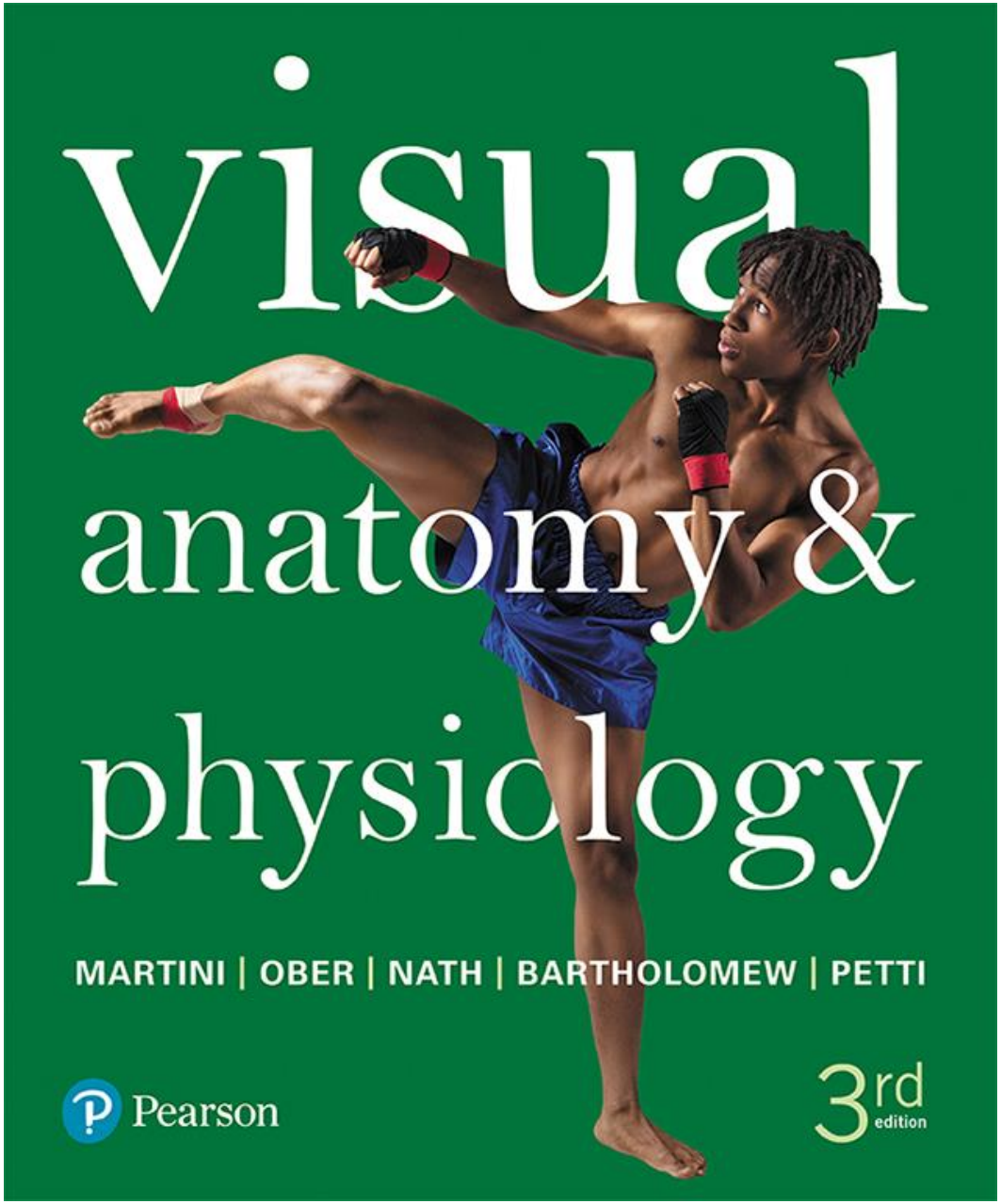

4

Tissue Level of Organization

Lecture Presentation by
Lori Garrett

Section 1: Epithelial Tissue

Learning Outcomes

4.1 Identify the four types of tissues in the body, and describe their roles.

4.2 Describe three microscopy techniques.

4.3 Describe epithelial tissues, including cell shape, layers, and functions.

4.4 Discuss the types and functions of intercellular connections between epithelial cells.

4.5 Describe the structure and function of squamous epithelium.

Section 1: Epithelial Tissue

Learning Outcomes (continued)

4.6 Describe the structure, function, and locations of cuboidal and transitional epithelia.

4.7 Describe the structure, function, and locations of columnar epithelia.

4.8 Compare the three different methods of exocrine secretion by glandular epithelia.

4.9 Explain how multicellular exocrine glands are classified by their structure.

Module 4.1: Four types of tissue make up the body

Body organization review

- **Atoms → Molecules → Cells → Tissues**
  - Chemical level can only be seen using special imaging techniques
  - Cellular level details seen best with electron microscope

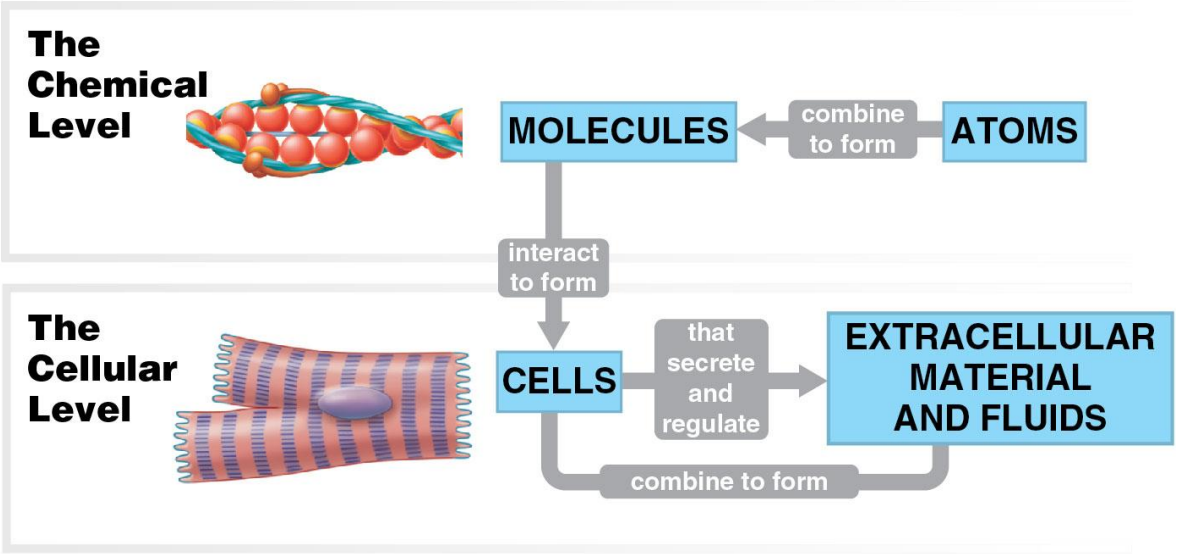

Module 4.1: Types of tissue

Body organization review (continued)

- Trillions of cells in the body
- Only about 200 different types of cells
- Cells working together form **tissues**
- Study of tissues called **histology**
- Four basic types of tissues
  1. Epithelial
  2. Connective
  3. Muscle
  4. Neural

Levels of organization up to the tissue level

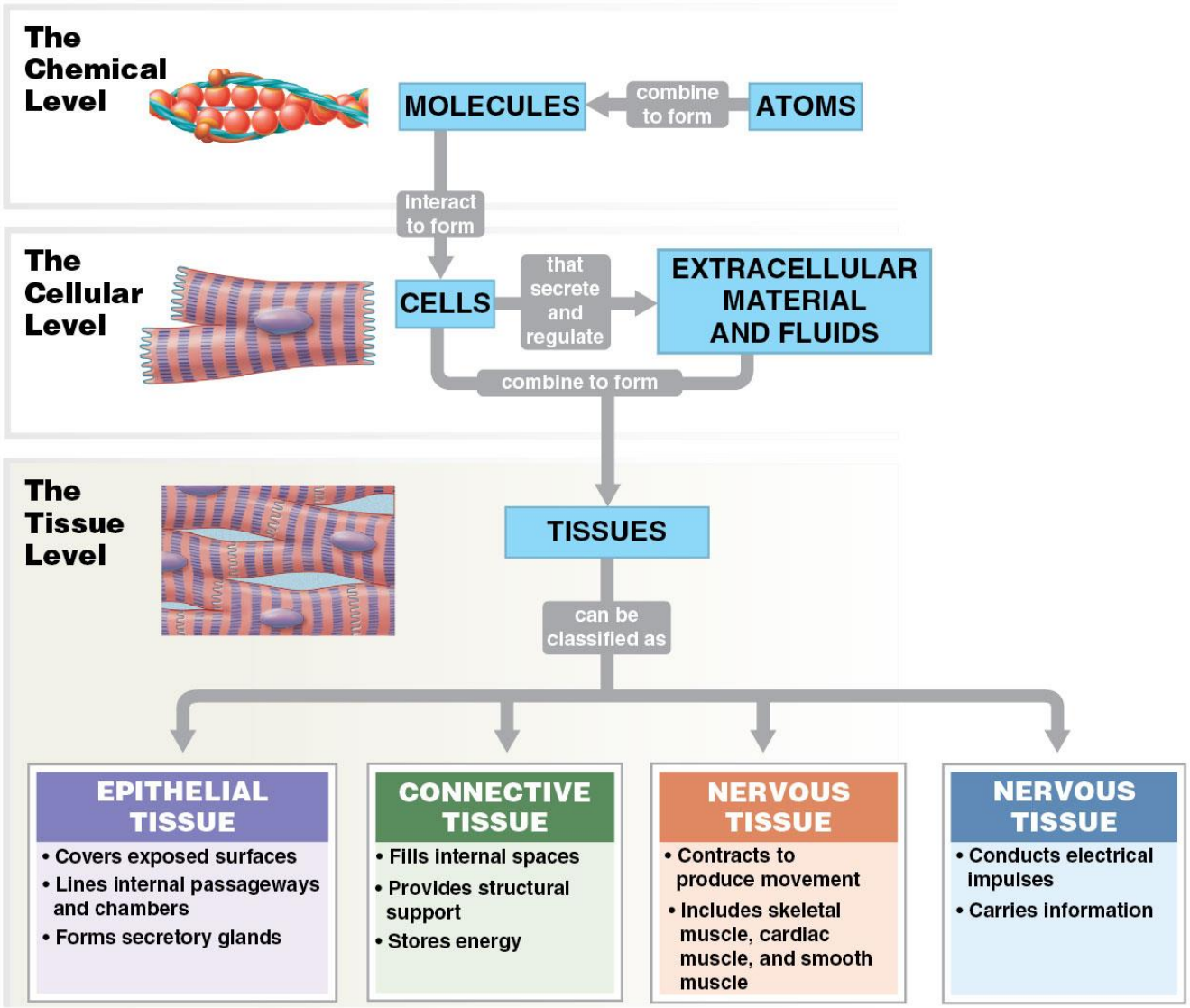

Module 4.1: Review

A. Give the term for “the study of tissues.”
B. What is a tissue?
C. List the four basic tissue types, and describe the functions of each.

Learning Outcomes: Identify the four types of tissue in the body, and describe their roles.

Module 4.2: Microscopes are used to study cells and tissues

Anatomy studied at different scales

- **Microscopy** (the use of microscopes)
  - Began about 400 years ago
    - Early magnification levels 10–20 times actual size
  - **Simple microscope**—uses only one lens
  - **Compound microscope**—uses >1 lens
  - Electron microscope
    - Can magnify over 1 million times
  - Amount of fine detail (resolution) of an image varies with magnification and type of microscope used

Magnification and resolution of different types of microscopes

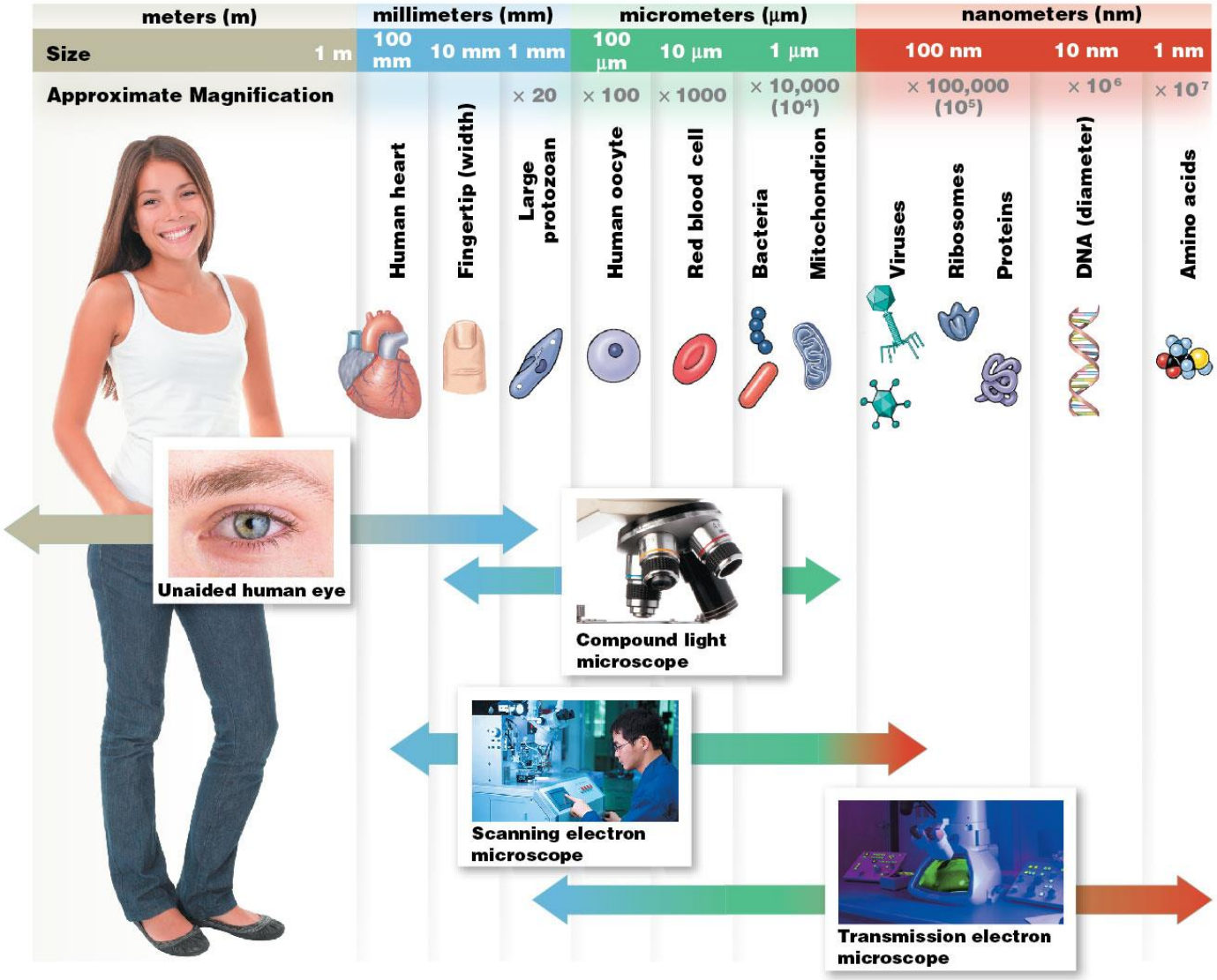

Module 4.2: Microscopy techniques

Types of microscopes

1. **Compound light microscope**
   - Detects visible light through thin section of tissue
   - Two lenses magnify specimen
     1. Objective lens located on **revolving nosepiece**
     2. Ocular lens located in the eye piece

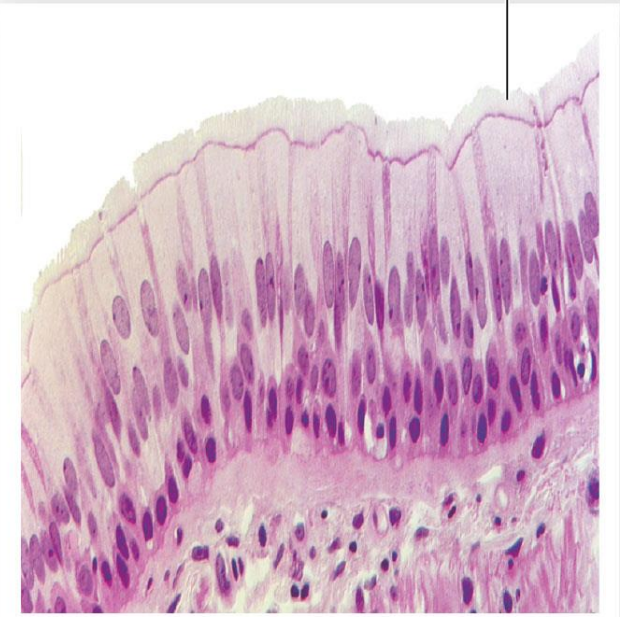

Epithelium (respiratory tract) LM × 400

Module 4.2: Microscopy techniques

Types of microscopes (continued)

1. **Compound light microscope** (continued)
   - **Total magnification** calculated by multiplying the two lens powers (objective × ocular)
   - **Resolution**
     - Ability to distinguish between two separate points
     - Wavelength of light limits resolution on light microscope to about 200 nm (0.2 μm)

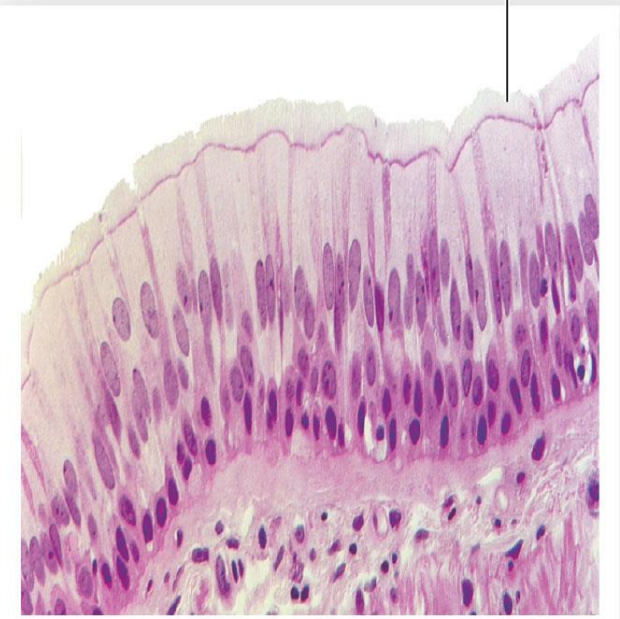

Epithelium (respiratory tract) LM × 400

Module 4.2: Microscopy techniques

Types of microscopes (continued)

2. **Transmission electron microscope**
   - "Transmits" electrons through specimen
   - Uses magnets to direct beam of electrons through the surface of a very thin object onto a photographic plate
   - Wavelength of electron beam 0.00001 of white light
   - Maximum resolution 0.2 nm (0.0002 μm)

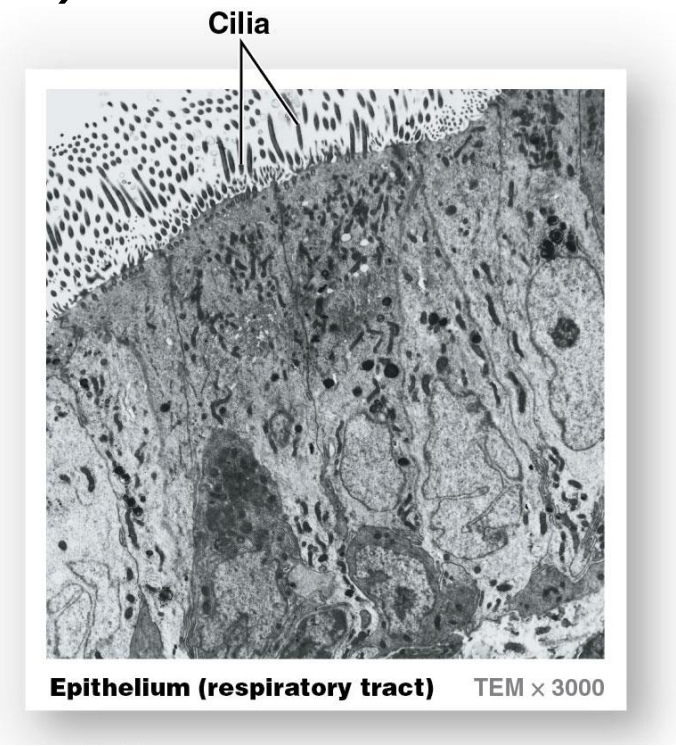

Module 4.2: Microscopy techniques

Types of microscopes (continued)

3. **Scanning electron microscope**
   - Uses electrons, but not by sending them through a specimen
   - Specimen coated with electron dense material
   - Electron beams are focused on the specimen



Epithelium (respiratory tract) SEM × 15,846

   - Reflection of electrons bouncing off object produce three dimensional image of the surface
   - Can view surface features only
   - Maximum resolution of about 10 nm (0.01 μm)

Module 4.2: Microscopy techniques

Magnification notation examples

- Type of microscope used (abbreviation) and magnification
  1. LM × 400
     - Light micrograph magnified 400 times
  2. TEM × 3000
     - Transmission electron micrograph magnified 3000 times
  3. SEM × 15,846
     - Scanning electron micrograph magnified 15,846 times

Module 4.2: Microscopy techniques

A&P lab microscopy tips

- Light microscopes most often used
- Begin with lowest magnification objective lens over specimen
- When in focus on that power, carefully rotate objective lenses with greater magnification into place
- Compare images from textbook to microscope image at same magnification

Module 4.2: Review

A. How do early microscopes compare with modern microscopes?
B. Differentiate among LM, TEM, and SEM.
C. The LM at the top of this page is magnified 400 times (400×). If the ocular lens used to make this image has a magnification of 10×, what is the magnification of the objective lens?

Learning Outcome: Describe three microscopy techniques.

Module 4.3: Epithelial tissue covers surfaces, lines cavities, and forms secretory glands

Divisions of epithelial tissue

1. **Epithelia**
   - Avascular layers
   - Cover exposed surfaces
   - Line internal cavities and passageways
   - Often contain secretory or gland cells scattered among other cell types

Module 4.3: Epithelial tissues

Divisions of epithelial tissue (continued)

2. **Glands**
   - Derived from epithelia
   - Predominantly secretory cells
   - Two types
     1. **Exocrine glands**
        - Secrete onto external surfaces or into ducts
     2. **Endocrine glands**
        - Secrete hormones into interstitial fluid
        - Hormones then distributed by bloodstream

Epithelial tissues

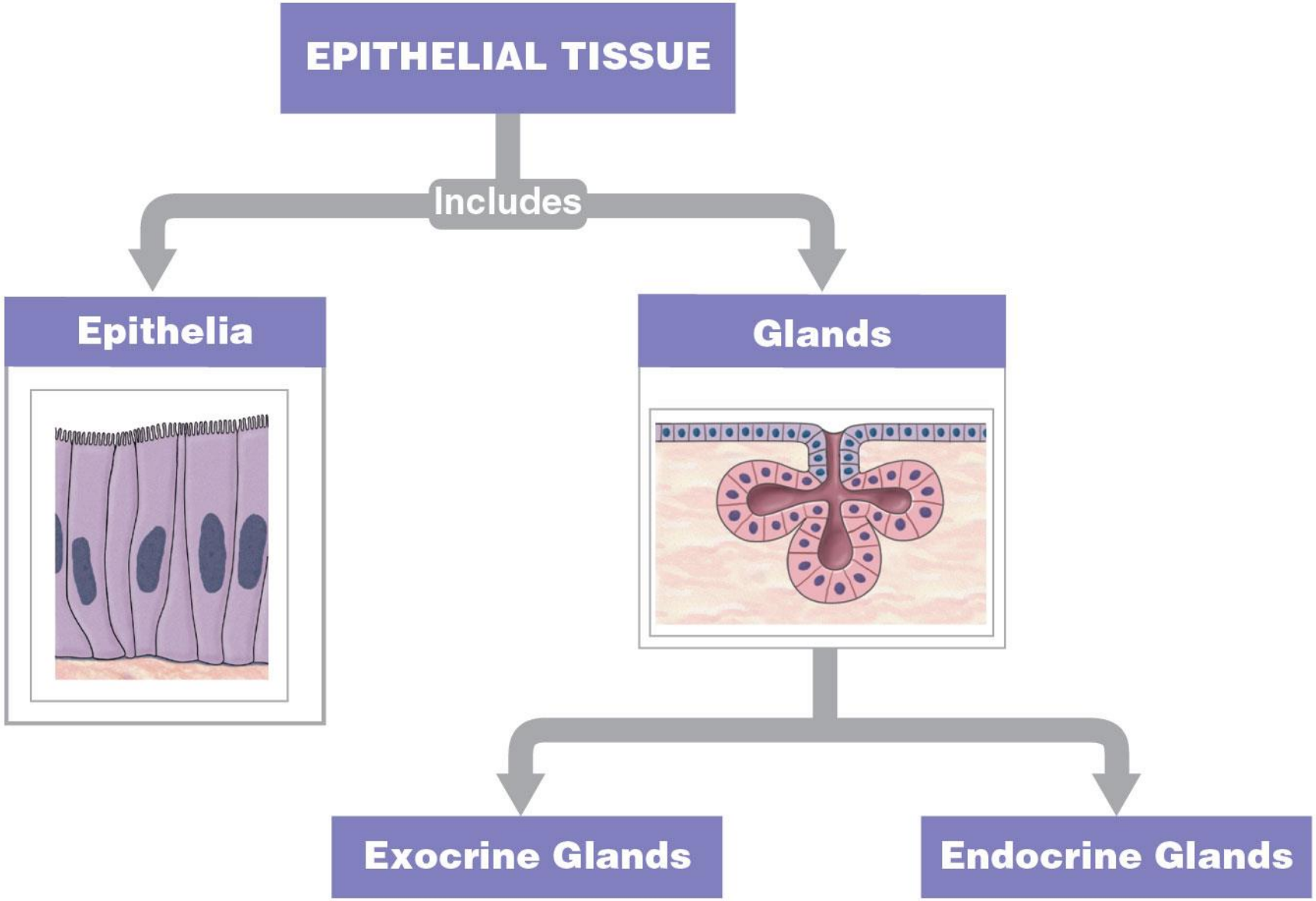

Module 4.3: Epithelial tissues

Functions of epithelial tissue

- **Provide physical protection**
  - Protect surfaces from abrasion, dehydration, or destruction by chemical or biological agents
- **Control permeability**
  - Most epithelia are capable of selective absorption or secretion
  - Epithelial barrier can be modified in response to stimuli (*Example:* calluses)

Module 4.3: Epithelial tissues

Functions of epithelial tissue (continued)

- **Provide sensation**
  - Specialized epithelial cells detect changes in environment (for example, touch receptors)
  - **Neuroepithelium**
    - Sensory epithelium found in special sense organs
- **Produce specialized secretions**
  - Glandular epithelial cells produce secretions

Module 4.3: Epithelial tissues

Features of epithelial tissue (continued)

- **Surfaces**
  - **Apical surface**
    - Faces exterior of body or internal space
  - **Base**
    - Attached to underlying tissues
    - **Basolateral surface**
      - Includes base and sides (lateral surfaces) attached to neighboring cells

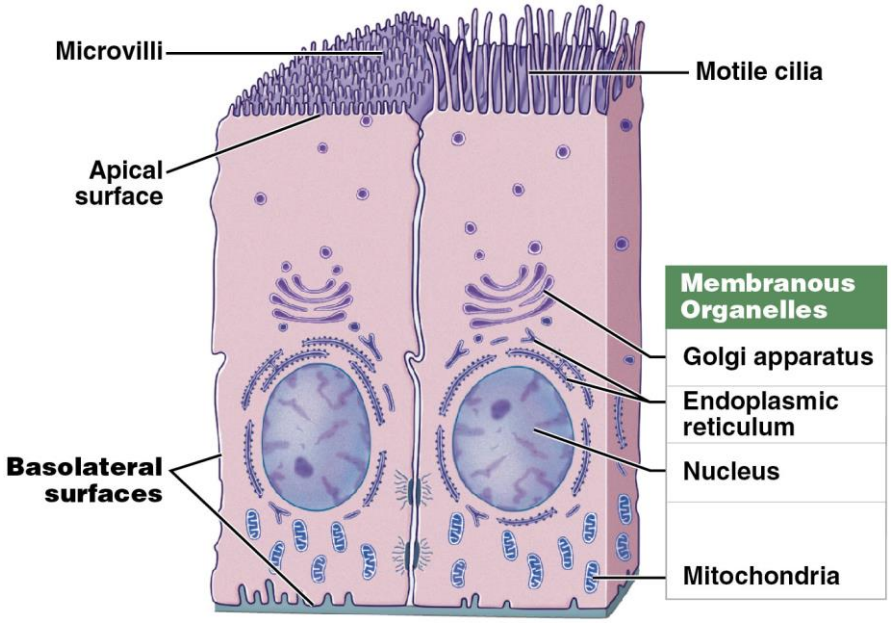

- **Polarity**
  - Refers to structural differences between exposed and attached surfaces

Module 4.3: Epithelial tissues

Features of epithelial tissue (continued)

- **Apical surface** features
  - If lining a tube, apical surface is exposed to space inside the tube, called **lumen**
  - Microvilli found on this surface in digestive, urinary, and reproductive tracts
  - Cilia found on this surface in parts of the respiratory and reproductive tracts
- Epithelial cells also contain membranous organelles comparable to other cell types

Module 4.3: Epithelial tissues

Epithelial cells have 3 basic shapes (viewed perpendicular to exposed surface)

1. **Squamous**
   - Thin and flat
2. **Cuboidal**
   - Cube-shaped
   - Like little boxes
3. **Columnar**
   - Taller than they are wide
   - Slender rectangles

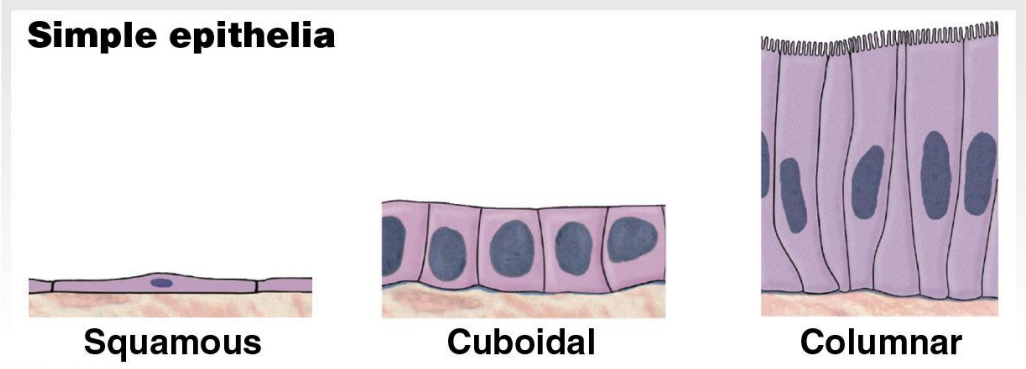

Module 4.3: Epithelial tissues

Epithelial cell layers

- Single layer
  - **Simple epithelium**
- Several layers of cells
  - **Stratified epithelium**
  - Found in areas that need protection from abrasion or chemical stress
    - *Examples:* surface of skin, lining of the mouth

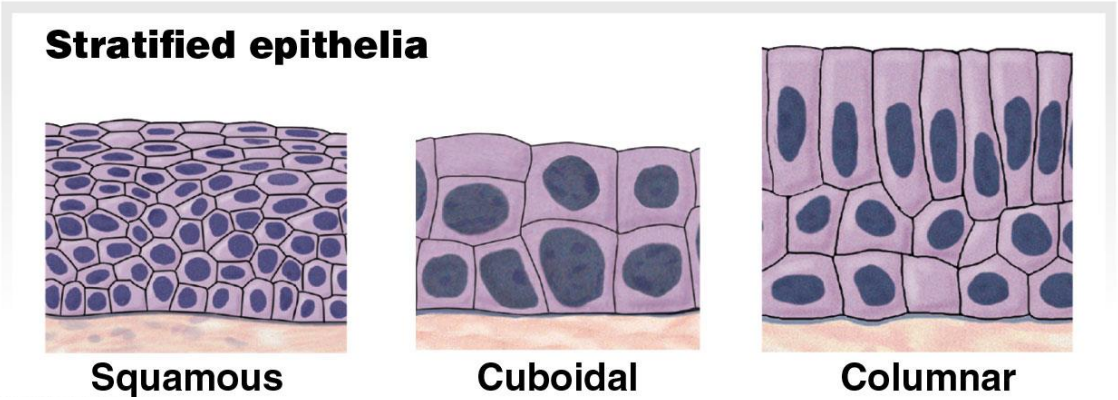

Module 4.3: Review

A. List four essential functions of epithelial tissue.
B. Summarize the classification of an epithelium based on cell shape and number of cell layers.
C. What function is served by motile cilia on epithelial cell surfaces?

Learning Outcome: Describe epithelial tissues, including cell shape, layers, and functions.

Module 4.4: Epithelial cells are extensively interconnected, both structurally and functionally

Epithelial attachments

- Extensive attachments between adjacent cells and adjacent tissues
  - To function as a barrier, must have intact, complete lining
  - Must be able to replace damaged or lost cells
  - Epithelia lack blood vessels (**avascular**)
    - Requires attachment to underlying connective tissue for nourishment from blood vessels there

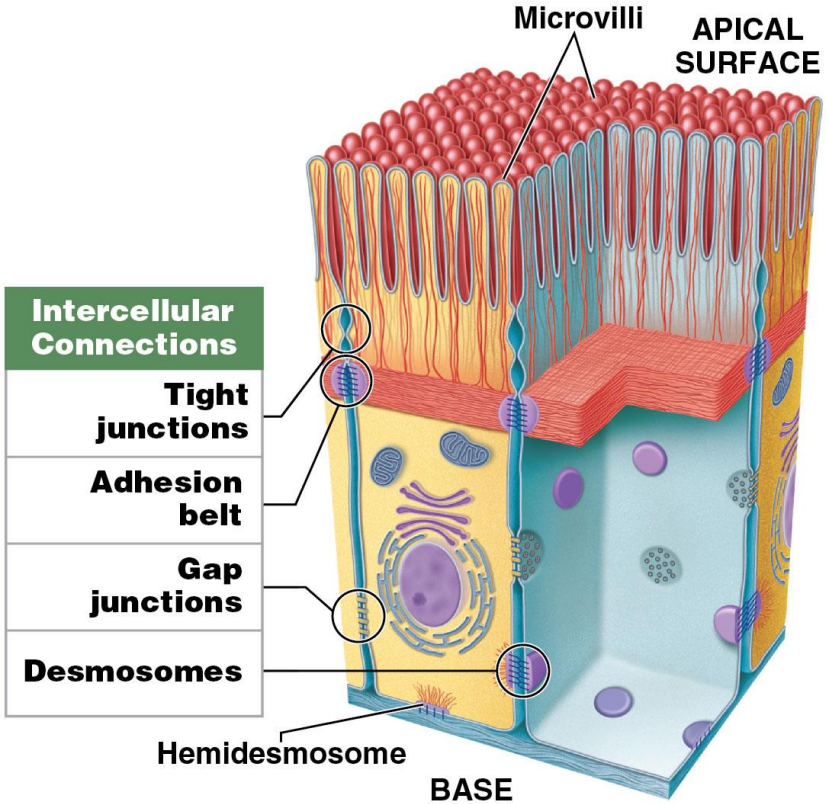

Module 4.4: Intercellular connections

Types of intercellular connections

1. **Hemidesmosomes**
   - Attach deepest epithelial cells to **basement membrane**
     1. **Basal lamina**
        - Contains glycoproteins and fine protein filaments
        - Produced by basal surface of epithelium

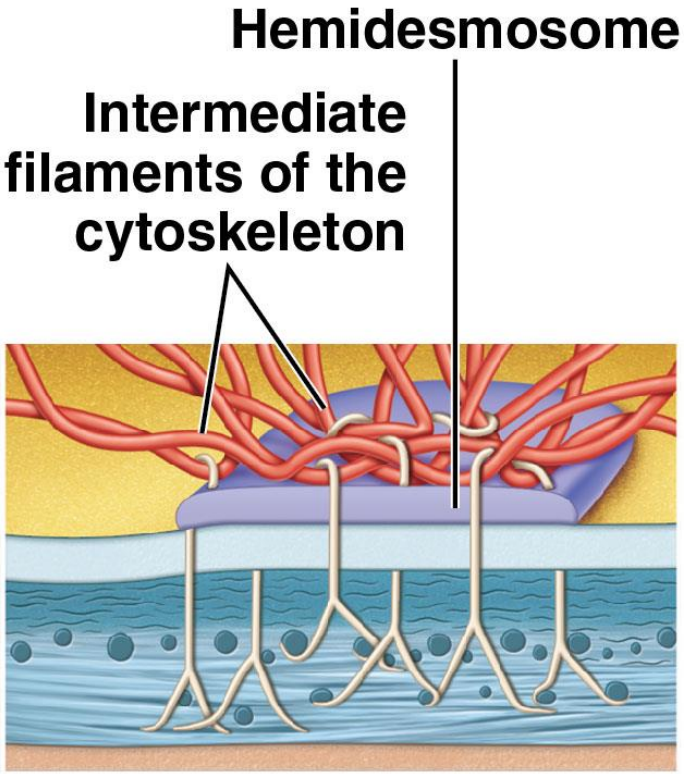

Module 4.4: Intercellular connections

Types of intercellular connections (continued)

1. **Hemidesmosomes** (continued)
   2. **Reticular lamina**
      - Contains bundles of coarse protein fibers
      - Gives strength and restricts diffusion

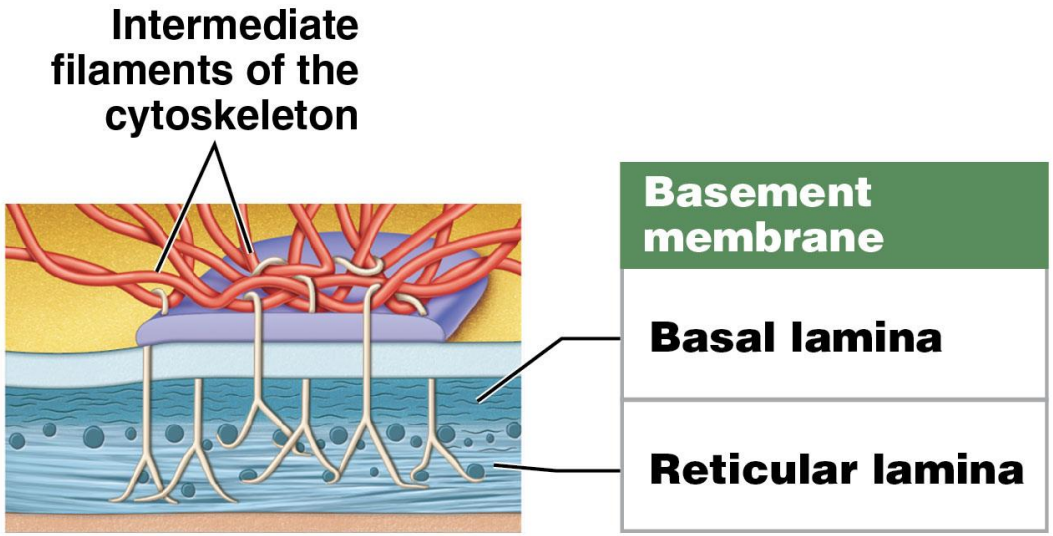

Module 4.4: Intercellular connections

Types of intercellular connections (continued)

2. **Tight** (occluding) **junctions**
   - Interlocking membrane proteins bind adjacent plasma membranes together
   - Prevent passage of water and solutes between cells
   - Isolate basolateral surfaces and deeper tissues from contents in lumen
   - Found in intestinal tract

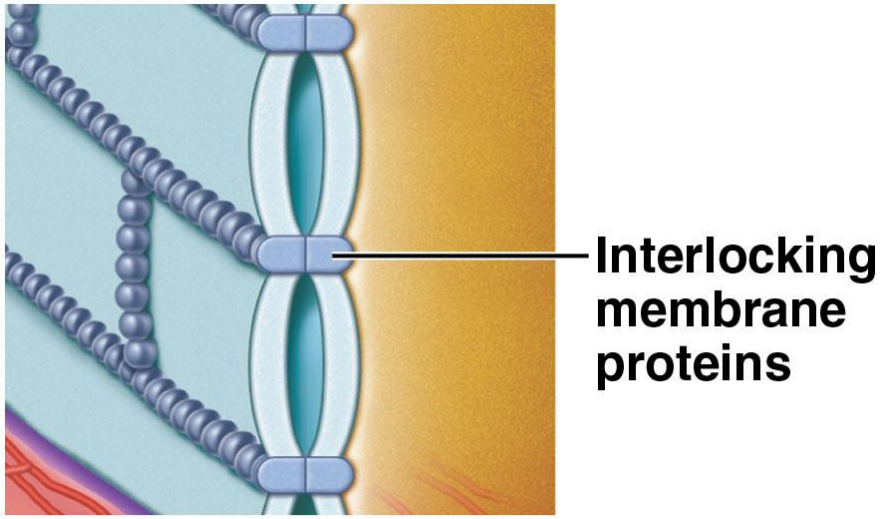

Module 4.4: Intercellular connections

Types of intercellular connections (continued)

3. **Adhesion belts**
   - Continuous band of membrane proteins
   - Strengthens apical region of cells
     - Reinforces tight junctions

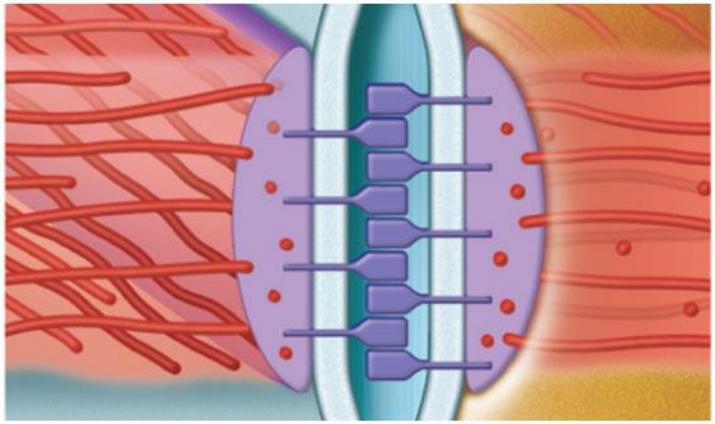

   - Dense proteins attached to microfilaments of the terminal web (part of cytoskeleton)
   - Belts encircle cells and bind to adjacent cells

Module 4.4: Intercellular connections

Types of intercellular connections (continued)

4. **Gap junctions**
   - Held together by interlocking transmembrane proteins (**connexons**)
   - Assist chemical communication to help coordinate functions such as secretion or beating cilia
   - Also found in cardiac muscle and smooth muscle tissue to coordinate contraction

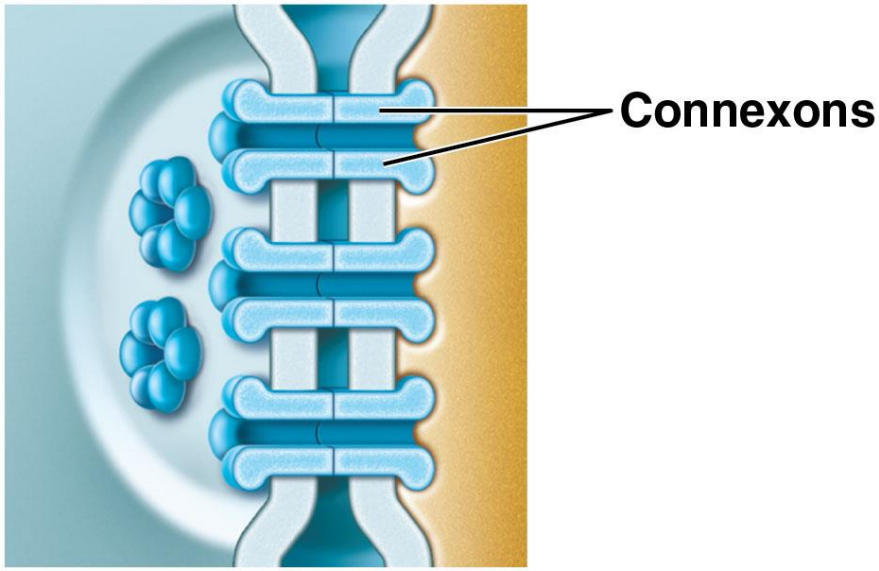

Module 4.4: Intercellular connections

Types of intercellular connections (continued)

5. **Desmosomes**
   - Provide firm attachments by interlocking adjacent cells' cytoskeletons
   - Opposing plasma membranes locked together by **cell adhesion molecules** (**CAMs**)
     - Thin layer of proteoglycans may also bond
       - Contain polysaccharide, notably **hyaluronic acid**
   - Very strong; resist stretching and twisting
   - Found in superficial layers of skin

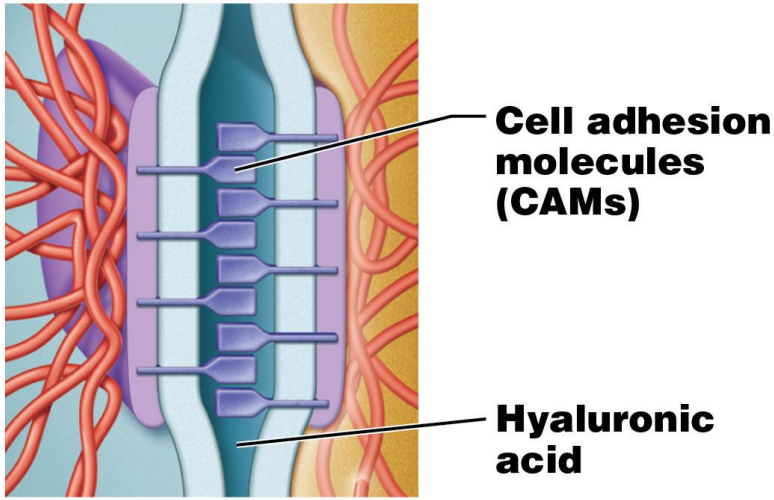

Module 4.4: Review

A. Identify the various types of epithelial intercellular connections.
B. What is the functional significance of gap junctions?
C. How do epithelial tissues obtain needed nutrients?
D. What two types of tissues contribute to the formation and maintenance of the basement membrane?

Learning Outcome: Discuss the types and functions of intercellular connections between epithelial cells.

Module 4.5: The cells in a squamous epithelium are flat and irregularly shaped

Squamous epithelium
(*squama*, plate or scale)

- Thin, flat, irregularly shaped cells (like jigsaw puzzle pieces)
  - Viewed from above, cells look like fried eggs
  - In sectional view, disc-shaped nucleus found in thickest part of cell
- May be single layer (simple) or multiple layers (stratified)

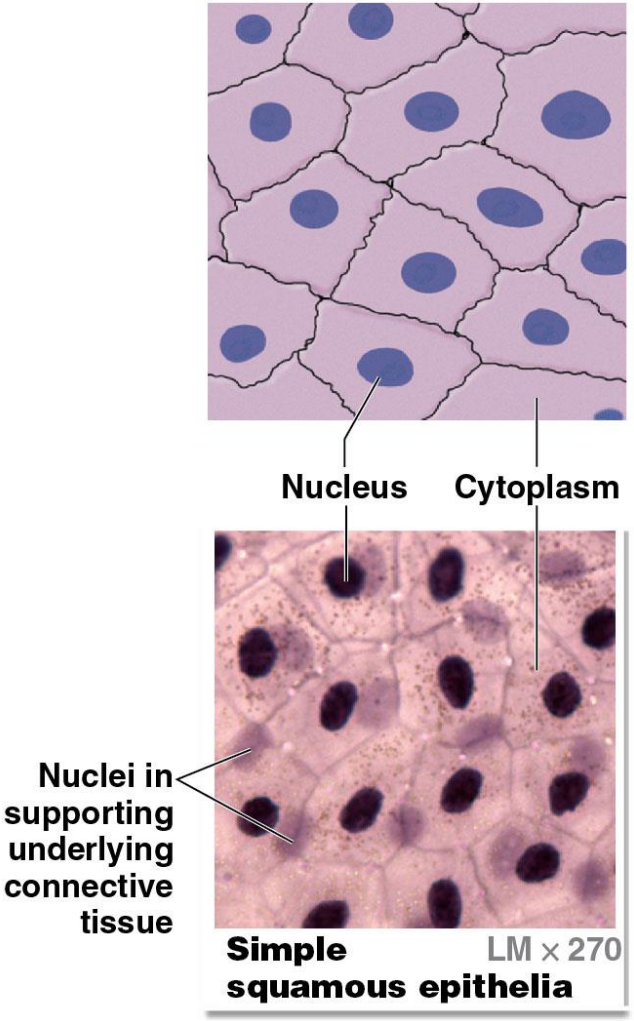

Module 4.5: Squamous epithelium

Simple squamous epithelium

- Most delicate epithelium (one layer thick)
- Functions include absorption, diffusion, reduction of friction
- Found in protected regions such as peritoneum, capillary walls, inside eye, lung alveoli

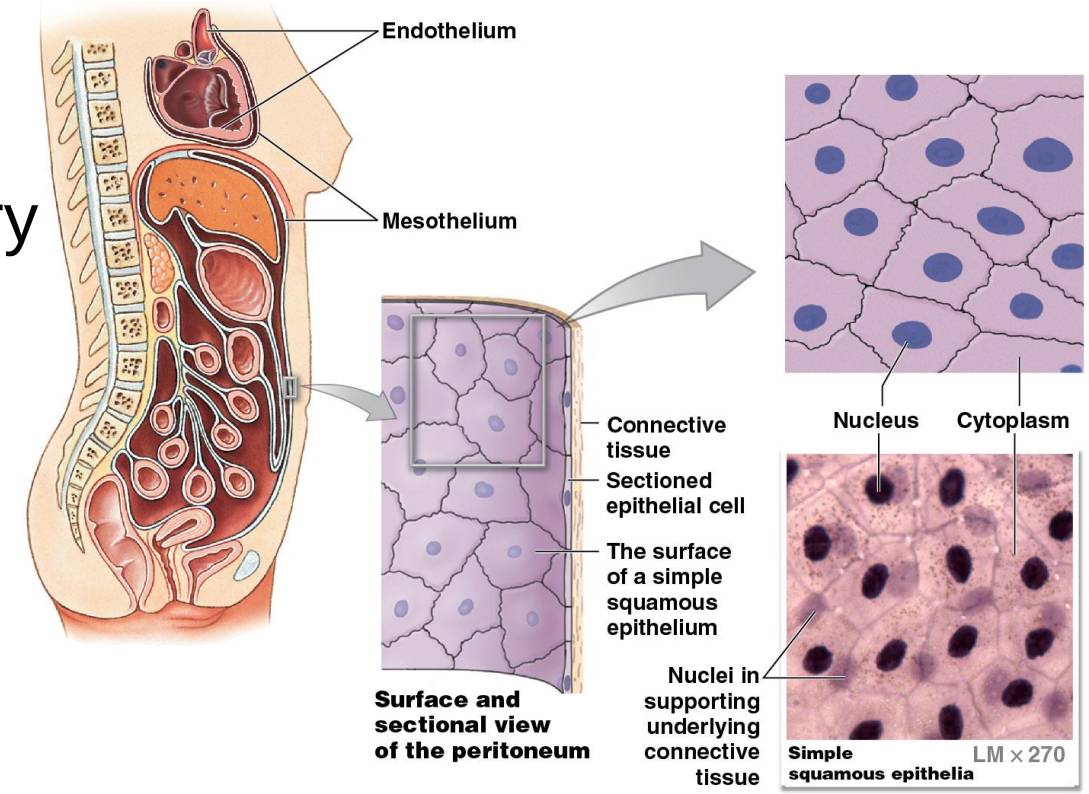

Module 4.5: Squamous epithelium

Simple squamous epithelium (continued)

- Certain locations have special names
  - **Mesothelium** lining ventral body cavities
  - **Endothelium** lining heart and blood vessels

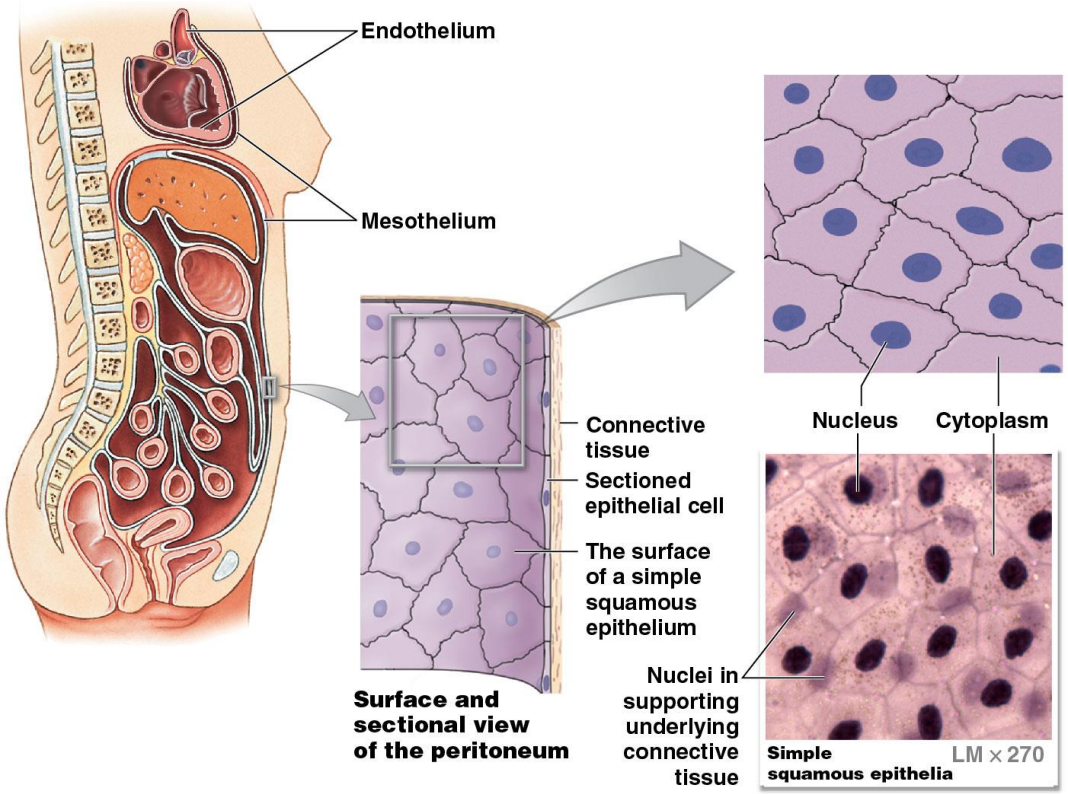

Module 4.5: Squamous epithelium

Stratified squamous epithelium

- Located where severe mechanical or chemical stresses exist
- Many layers of cells
- Superficial layer flattened
- Forms surface of skin and lines mouth, throat, esophagus, rectum, anus, vagina

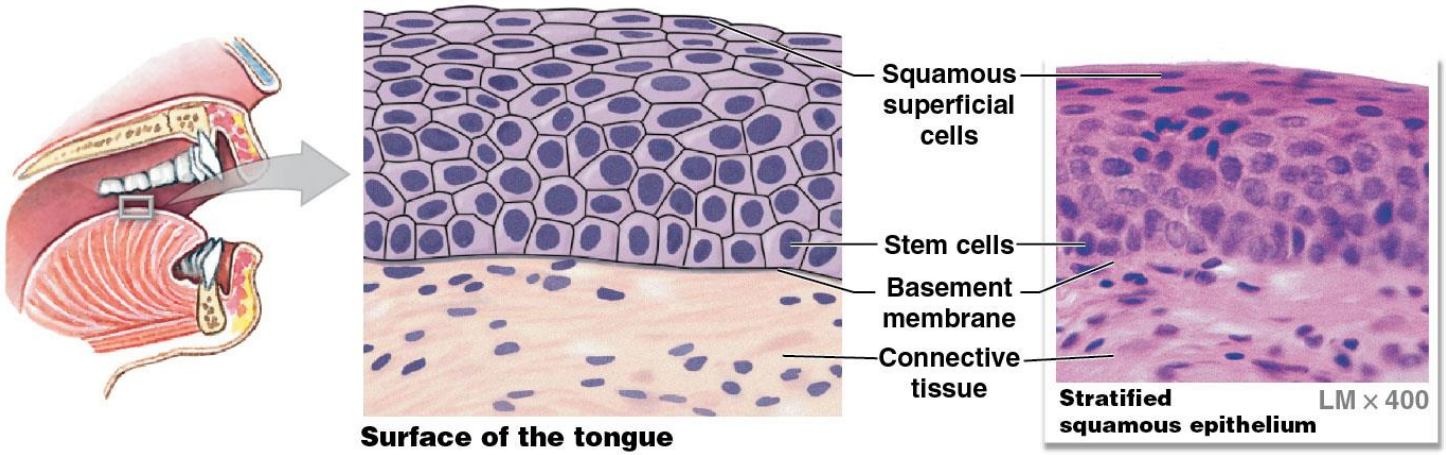

Module 4.5: Squamous epithelium

Stratified squamous epithelium (continued)

- Two types
  1. **Keratinized**
     - Superficial layers packed with keratin
     - Tough and water resistant
     - Resists both mechanical stress and dehydration
     - Found on surface of skin and in hair and nails
  2. **Nonkeratinized**
     - Resists abrasion but can dry out
     - Found lining oral cavity, pharynx, esophagus, anus, vagina

Keratinized skin layers

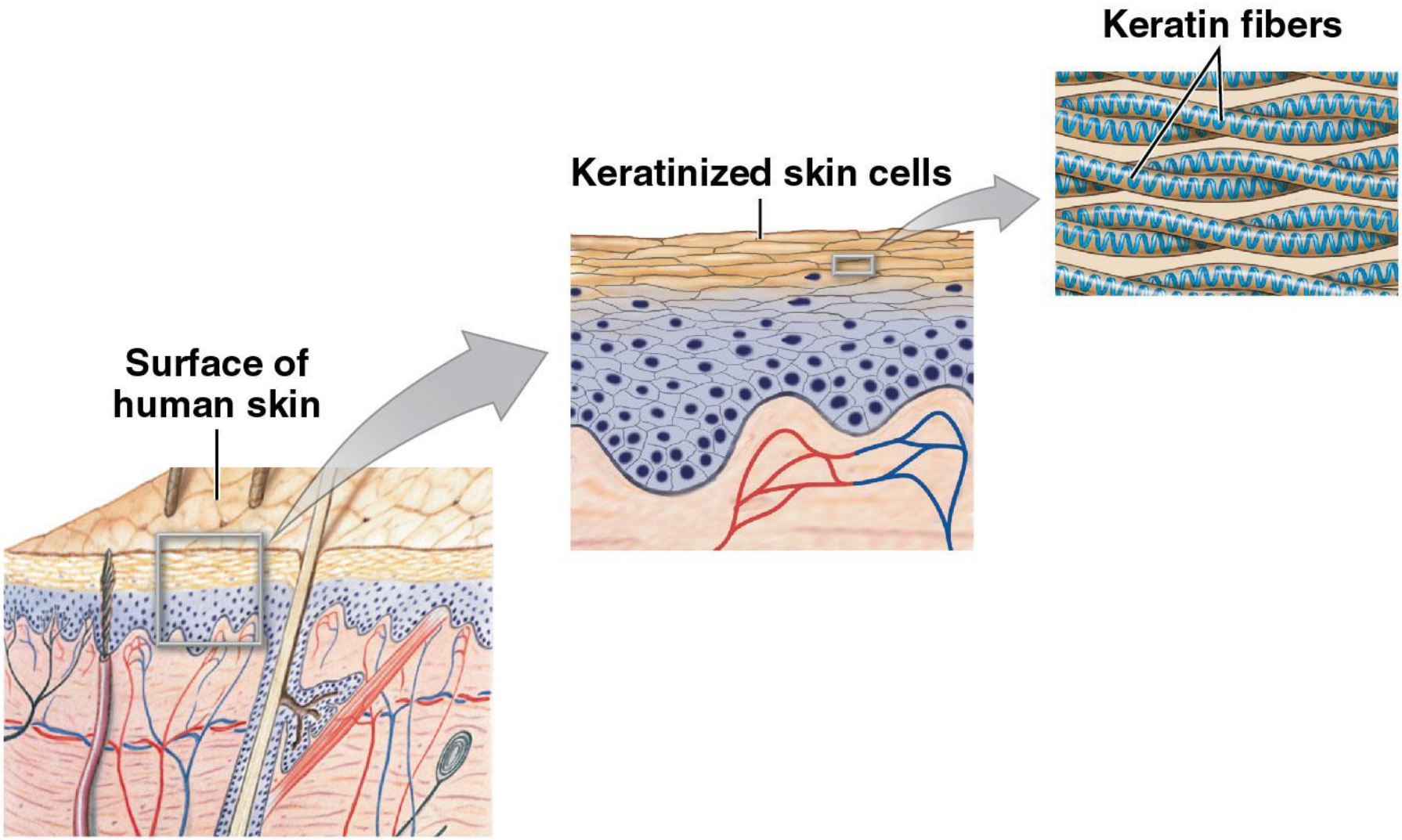

Module 4.5: Review

A. What do a mesothelium and an endothelium have in common?
B. Why do the pharynx, esophagus, anus, and vagina have a similar epithelial organization?
C. What properties are common to keratinized epithelia?
D. Under a light microscope, a tissue appears as a simple squamous epithelium. Can this be a sample of the skin surface? Why or why not?

Learning Outcome: Describe the structure and function of squamous epithelium.

Module 4.6: Cuboidal and transitional epithelia line several passageways and chambers connected to the exterior

Cuboidal epithelium

- Cells resemble hexagonal boxes
  - In sectional view, cells appear square
- Spherical nucleus near center of each cell

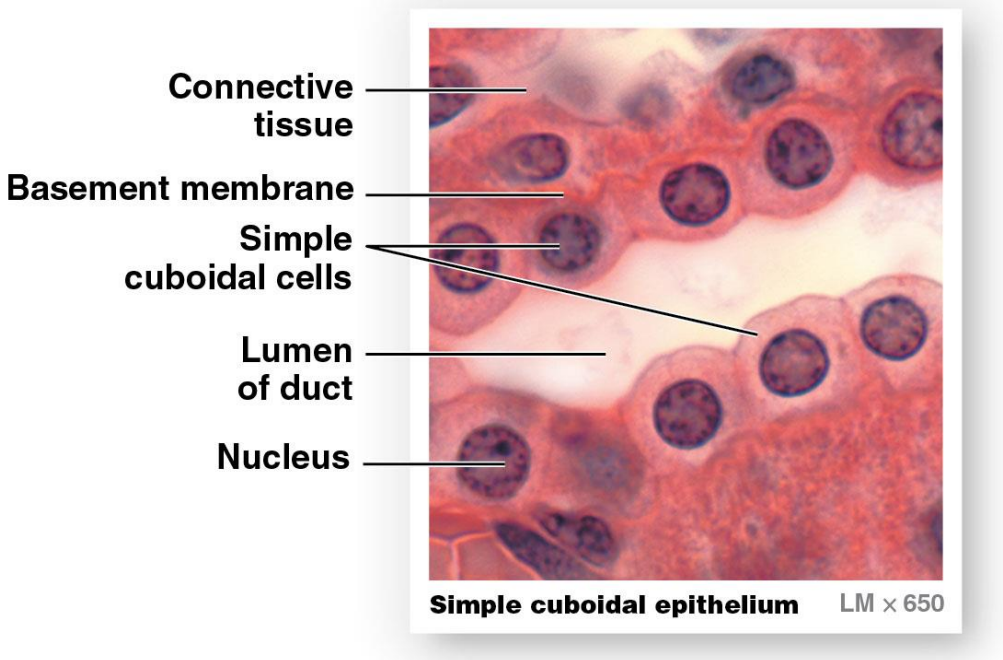

Module 4.6: Cuboidal and transitional epithelium

Two types of epithelium

1. **Simple cuboidal epithelium**
   - Functions in secretion and absorption
   - Lines exocrine glands and ducts
   - Lines parts of kidney tubules and thyroid gland

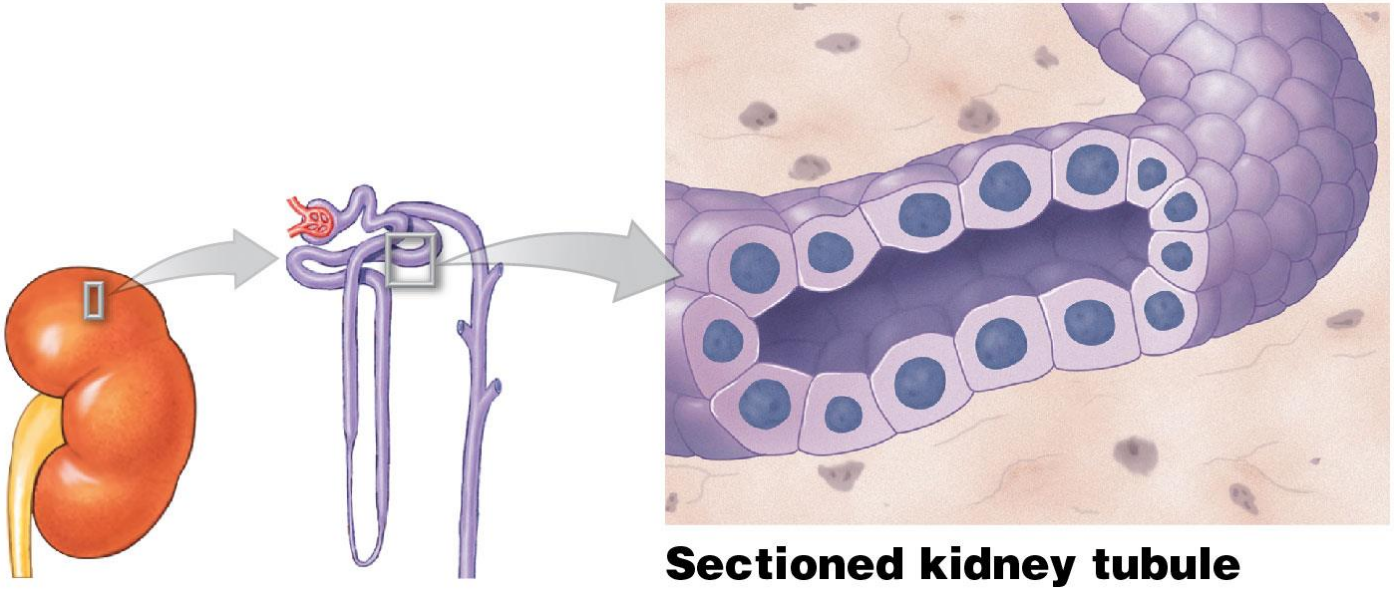

Module 4.6: Cuboidal and transitional epithelium

Two types of epithelium (continued)

2. **Stratified cuboidal epithelium**
   - Rare tissue
   - Found in ducts of sweat glands and mammary glands

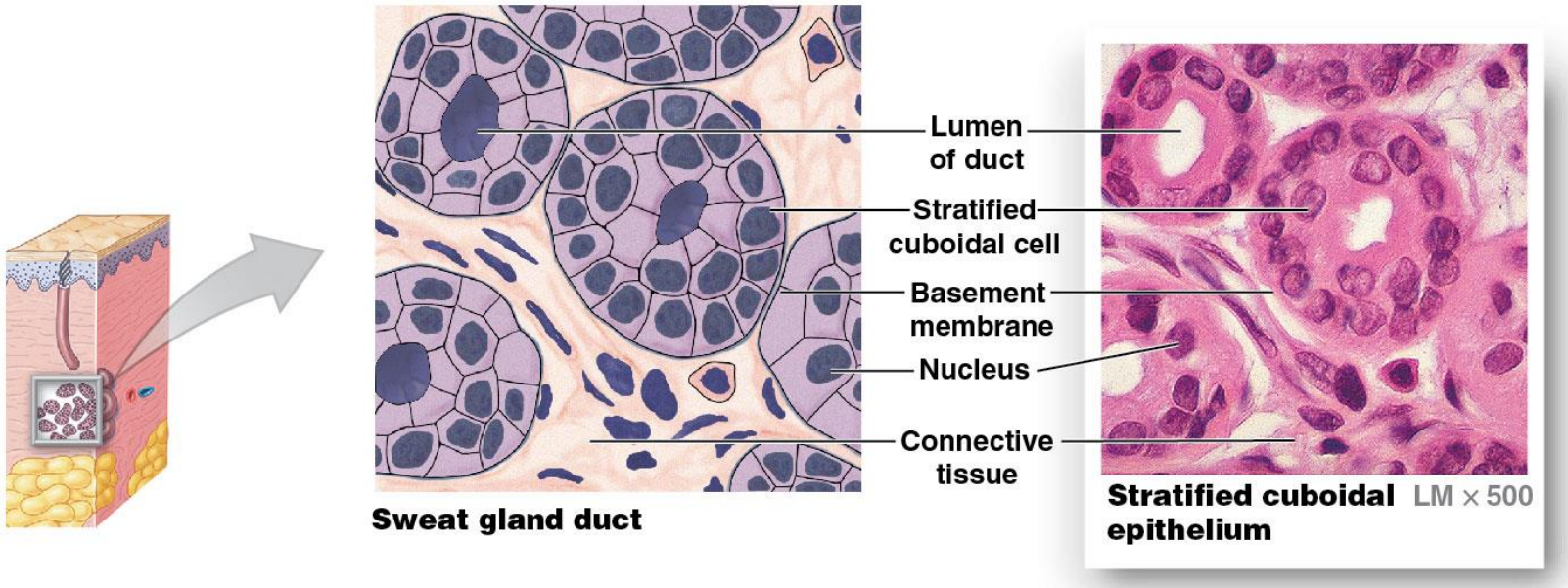

Module 4.6: Cuboidal and transitional epithelium

Transitional epithelium

- Unusual stratified epithelium that can stretch and recoil without damage
  - *Transitional* name because changes appearance
- Found only in urinary system (urinary bladder, ureters, urine-collecting chambers of kidneys)
- Changes in appearance
  - Relaxed (e.g., empty bladder)—superficial cells cuboidal
  - Stretched (e.g., full bladder)—superficial cells flattened

Transitional epithelium

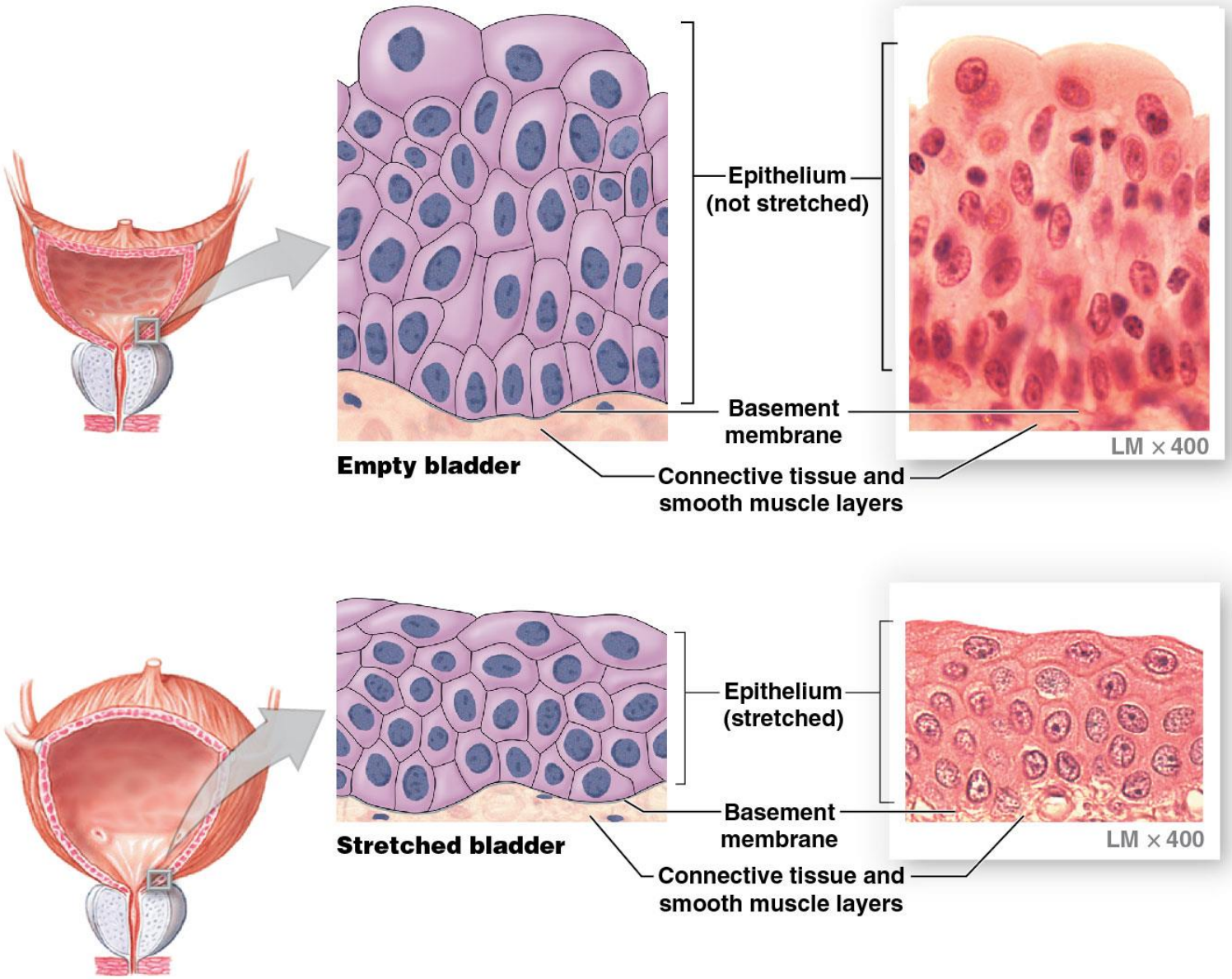

Module 4.6: Review

A. Describe the appearance of simple cuboidal epithelial cells in sectional view.
B. Identify the epithelium that lines the urinary bladder, and describe its unusual functional characteristic.
C. Describe the changes in appearance of the transitional epithelium lining the urinary bladder as stretching occurs.
D. What functions are associated with a simple cuboidal epithelium and a transitional epithelium?

Learning Outcome: Describe the structure, function, and locations of cuboidal and transitional epithelia.

Module 4.7: Columnar epithelia absorb substances and protect the body from digestive chemicals

Columnar epithelium

- In sectional view, cells appear rectangular
- Cells taller and more slender than cuboidal
- Elongated nuclei in band close to basement membrane
- Types
  1. **Simple columnar epithelium**
  2. **Pseudostratified columnar epithelium**
  3. **Stratified columnar epithelium**

Module 4.7: Columnar epithelium

Simple columnar epithelium

- Found where absorption or secretion takes place
  - Line stomach, intestine, gallbladder, uterine tubes, kidney ducts
- May have microvilli (for absorption) or cilia (for movement) on apical surface

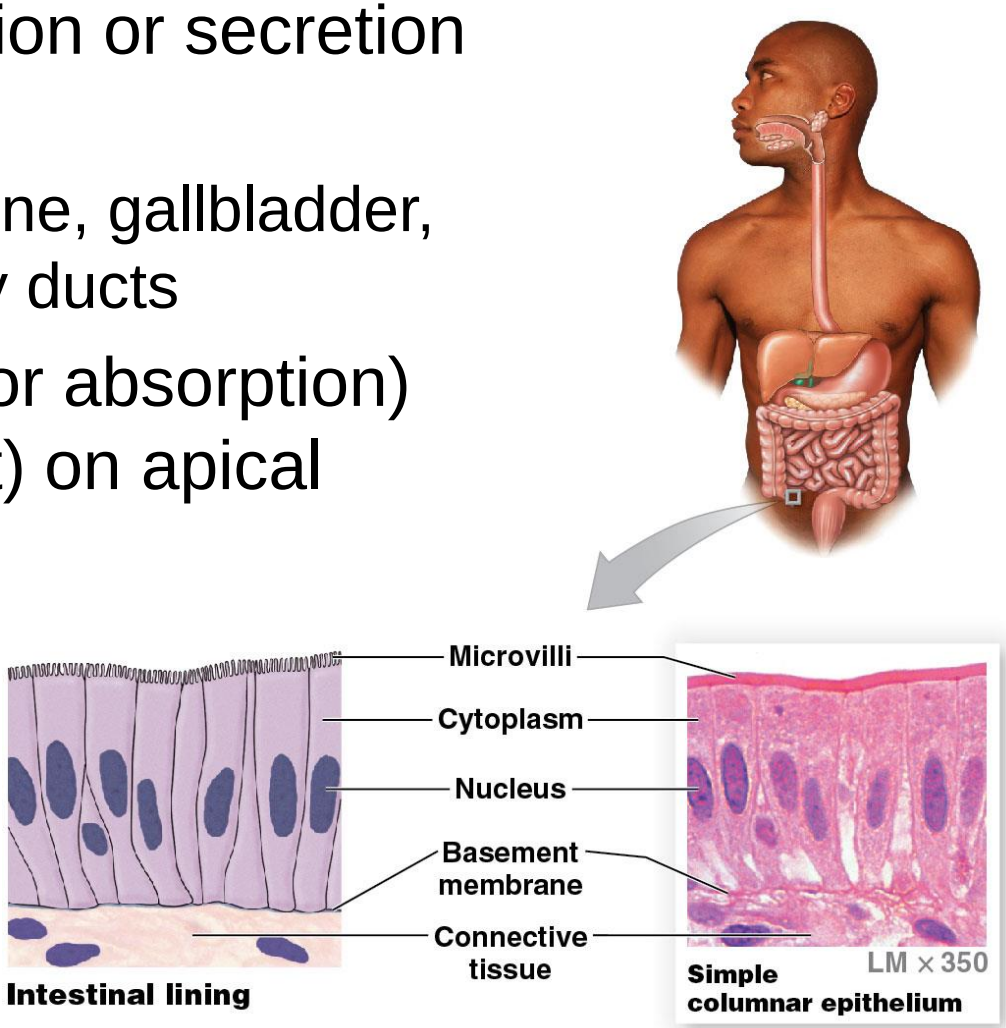

Module 4.7: Columnar epithelium

Pseudostratified columnar epithelium

- Cells of varying shapes and functions
- Distance between nuclei varies, giving appearance of layering or being stratified
  - Each cell contacts basement membrane
- Cells usually have cilia
- Lines nasal cavities, trachea, larger airways in lungs, portions of male reproductive tract

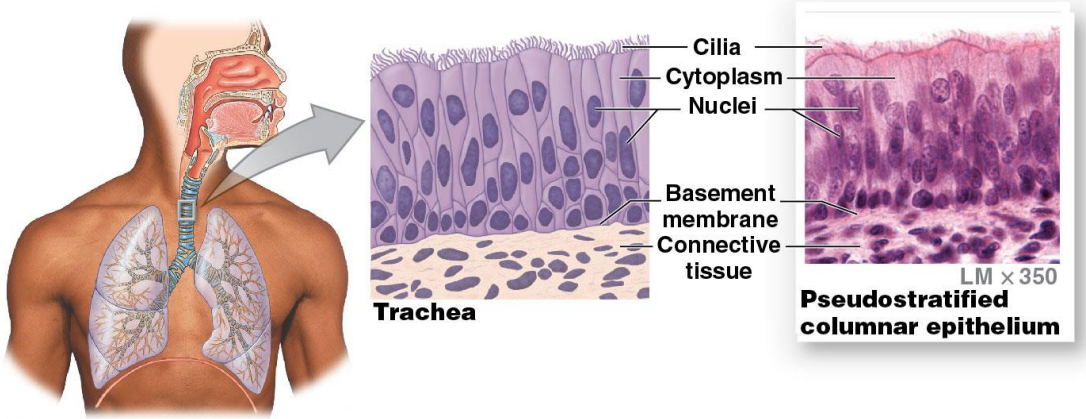

Module 4.7: Columnar epithelium

Stratified columnar epithelium

- Rare tissue type
- Two or more layers of cells
  - Superficial layer of columnar cells
- Found lining large ducts such as those of salivary glands or pancreas

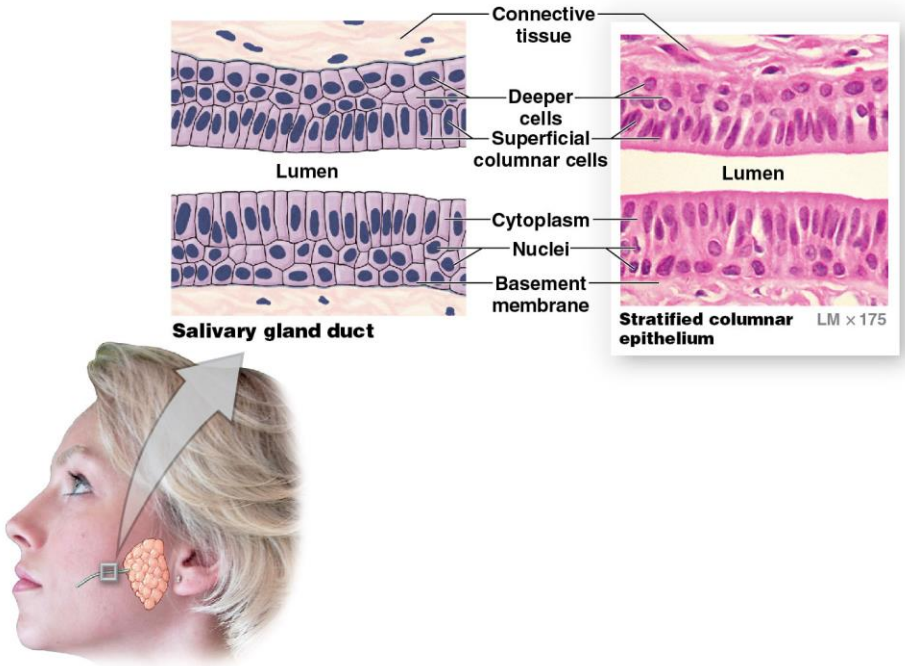

Module 4.7: Review

A. Describe the appearance of simple columnar epithelial cells in a sectional view.
B. Explain why a pseudostratified columnar epithelium is not truly stratified.
C. Describe the structures found on the surfaces of simple columnar and pseudostratified columnar epithelia.

Learning Outcome: Describe the structure, function, and locations of columnar epithelia.

Module 4.8: Glandular epithelia are specialized for secretion

Glands

- Collections of epithelial cells (or derived structures) that produce secretions
- Can be scattered cells or complex organs
- Categorized into two types
  1. **Endocrine glands**
     - Release secretions into interstitial fluid
  2. **Exocrine glands**
     - Release secretions into **ducts** onto epithelial surface

Module 4.8: Glandular epithelium

Three types of exocrine gland secretion

1. **Merocrine** (*meros*, part) **secretion**
   - Product released from secretory vesicles by exocytosis
   - Most common mode of secretion
   - *Example:* salivary gland secretion
   - **Mucin**
     - Merocrine secretion that mixes with water to form **mucus**

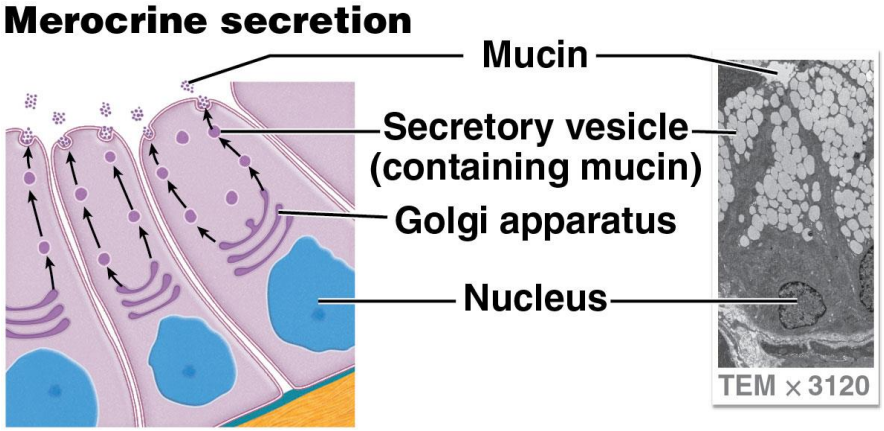

Mucin is a merocrine secretion that mixes with water to form mucus.

Module 4.8: Glandular epithelium

Three types of exocrine gland secretion (continued)

2. **Apocrine** (*apo*, off) **secretion**
   - Apical cytoplasm packed with secretory vesicles
   - Cell releases cytoplasm as well as secretory product
   - *Example:* mammary gland secretion (involves combination of merocrine and apocrine secretions)

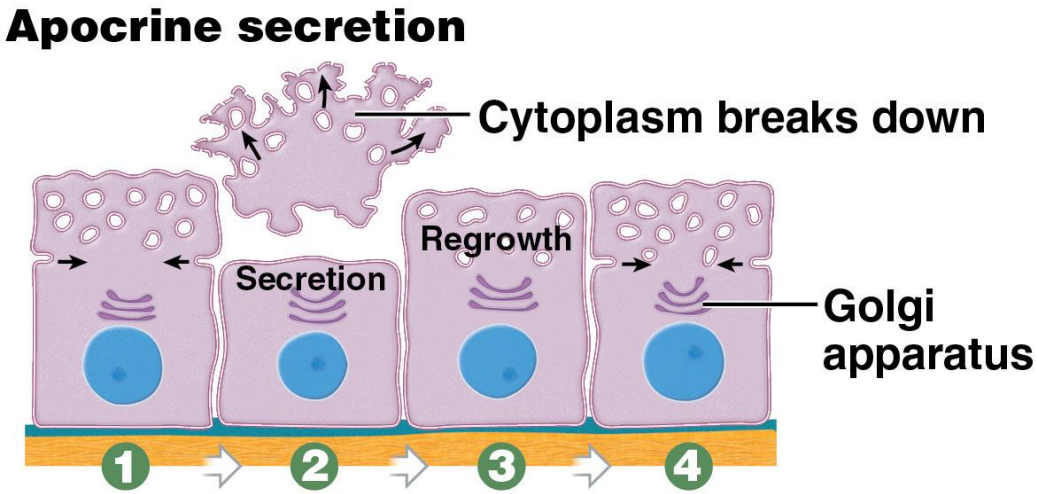

Module 4.8: Glandular epithelium

Three types of exocrine gland secretion (continued)

3. **Holocrine** (*holos*, entire) **secretion**
   - Destroys gland cell
   - Entire cell bursts, releasing secretions and killing cell
   - Destroyed cells replaced by stem cell division
   - *Example:* sebaceous glands

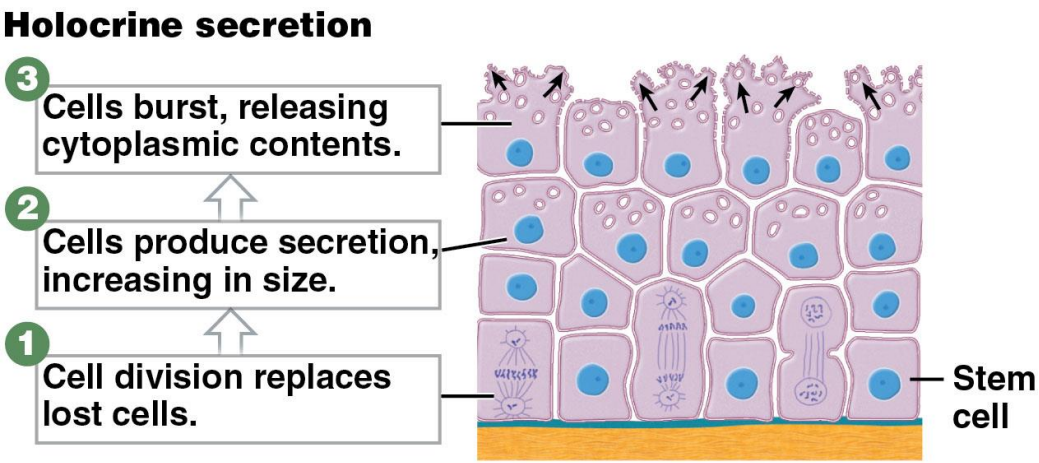

Module 4.8: Review

A. Describe the two primary types of glands.
B. By what three methods do various secretory cells of exocrine glands release their secretions?

Learning Outcome: Compare the three different methods of exocrine secretion by glandular epithelia.

Module 4.9: Exocrine glands can be classified by structure

Multicellular exocrine gland classification

- Based on duct structure
  - **Simple** (single duct that does not divide)
  - **Compound** (duct divides one or more times)

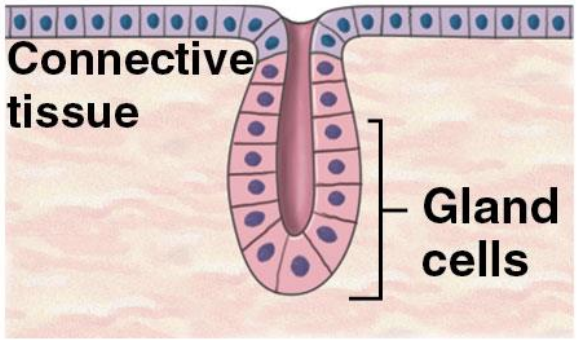

SIMPLE TUBULAR

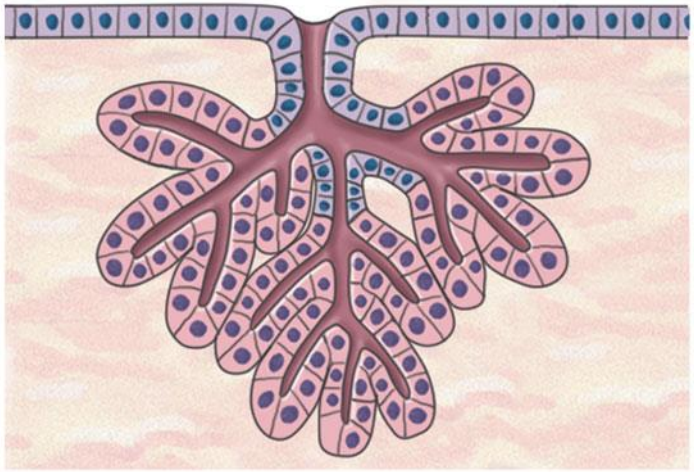

COMPOUND TUBULAR

Module 4.9: Glandular epithelium classification

Multicellular exocrine gland classification (continued)

- Based on the shape of the secretory area
  - **Tubular** (glandular cells form tubes)
  - **Alveolar** or **acinar** (glandular cells form sacs)
  - **Tubuloalveolar** (glandular cells form both tubes and sacs)

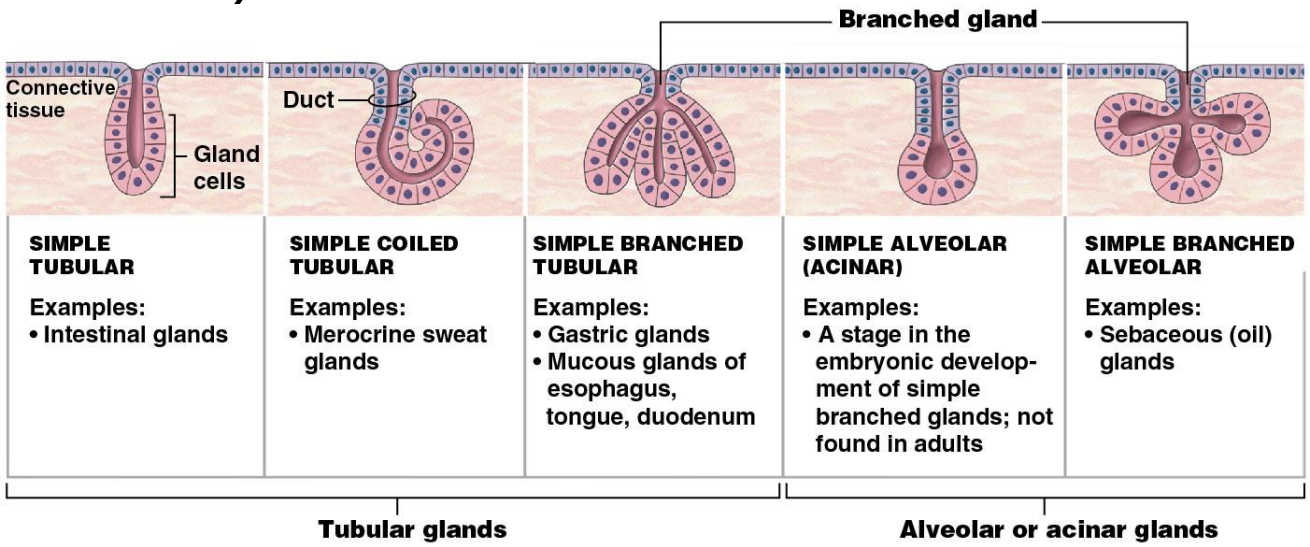

Types of compound glands

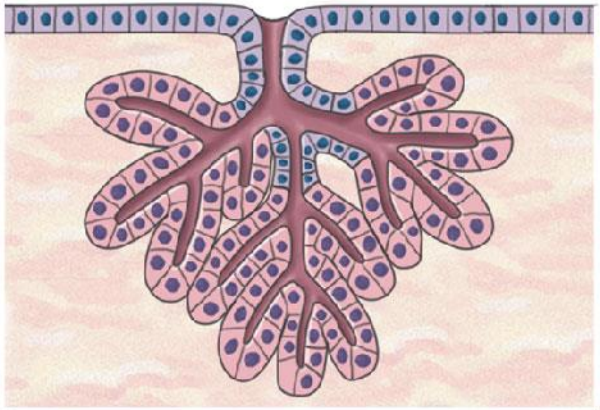

COMPOUND TUBULAR

Examples:
- Mucous glands in mouth
- Bulbo-urethral glands in male reproductive system
- Seminiferous tubules of testes

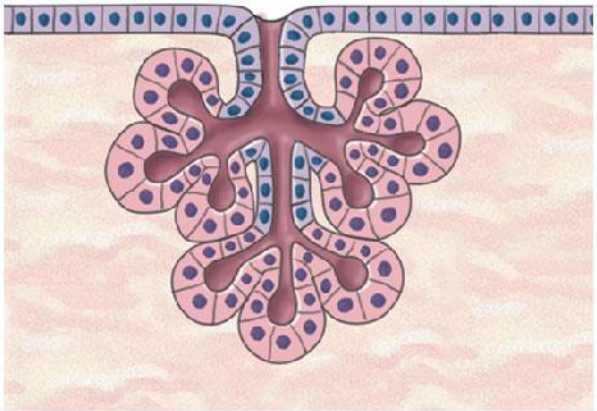

COMPOUND ALVEOLAR (ACINAR)

Examples:
- Mammary glands

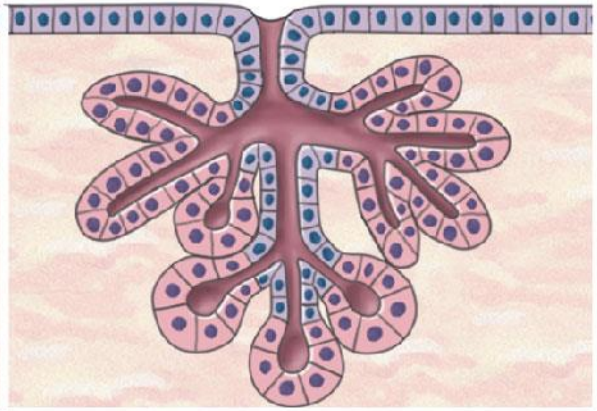

COMPOUND TUBULOALVEOLAR

Examples:
- Salivary glands
- Glands of respiratory passages
- Pancreas

Module 4.9: Glandular epithelium classification

Unicellular exocrine gland classification

- **Mucous (goblet) cells**
  - Only unicellular exocrine glands
  - Independent, scattered secretory cells in epithelium
  - Secrete mucin

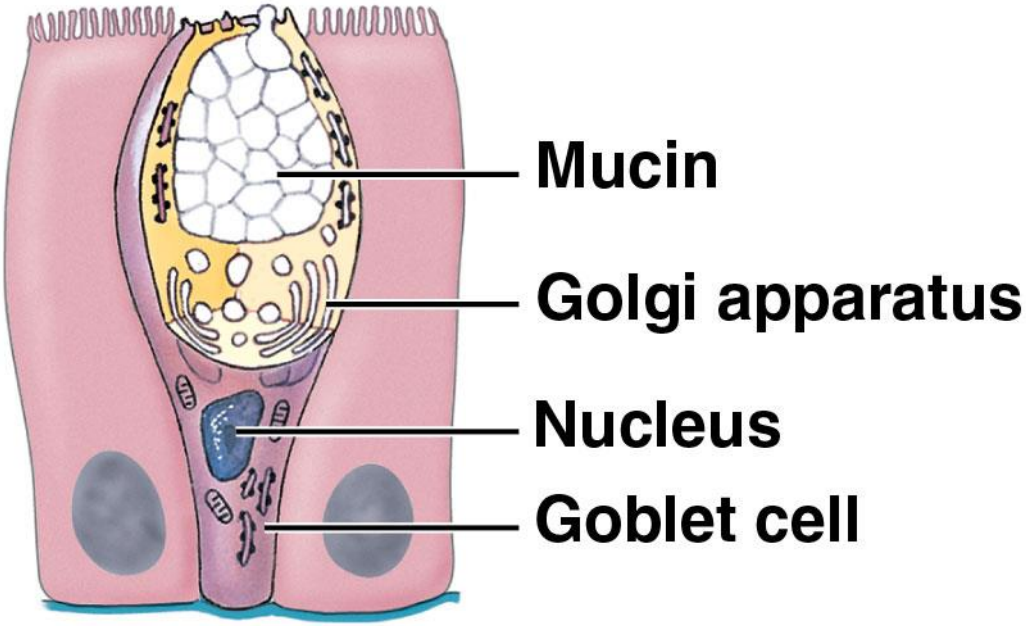

Module 4.9: Review

A. What three characteristics are used to describe multicellular exocrine glands?
B. Describe the simplest type of multicellular exocrine gland.

Learning Outcome: Explain how multicellular exocrine glands are classified by their structure.

Section 2: Connective Tissue

Learning Outcomes

4.10 Describe the general structure of connective tissue.

4.11 Describe the structure, function, and locations of areolar tissue, adipose tissue, and reticular tissue.

4.12 Describe the structure, function, and locations of dense connective tissues and fluid connective tissues.

4.13 Describe the structure, function, and locations of cartilage.

Section 2: Connective Tissue

Learning Outcomes (continued)

4.14 Describe the structure and function of bone.

4.15 Describe the arrangements of epithelial and connective tissues in the four types of tissue membranes, and describe the structures and locations of the three types of fasciae.

Module 4.10: A matrix surrounds connective tissue cells

Connective tissue overview

- Varies widely in appearance and function
  - Found throughout the body, but never exposed to surface
- Ranges from highly vascular to avascular
- Many contain sensory receptors that detect pain, pressure, temperature, and other stimuli

Functions of Connective Tissue

- Establish a structural framework for the body
- Transport fluids and dissolved materials
- Protect delicate organs
- Support, surround, and interconnect other types of tissue
- Store energy, especially in the form of triglycerides
- Defend the body from invading microorganisms

Module 4.10: Connective tissue

Three basic components shared by connective tissues

1. Specialized cells
2. Extracellular protein fibers
3. Fluid called **ground substance**
   - Matrix
     - Extracellular fibers and ground substance
     - Surrounds the cells
     - Accounts for majority of connective tissue volume
     - Fewer cells and more extracellular material compared to epithelial tissue

Module 4.10: Connective tissue

Three subdivisions of connective tissue

1. **Connective tissue proper**
   - Contains many types of cells
   - Extracellular fibers in syrupy ground substance
     - **Loose** (fibers create loose, open framework)
     - **Dense** (fibers densely packed)

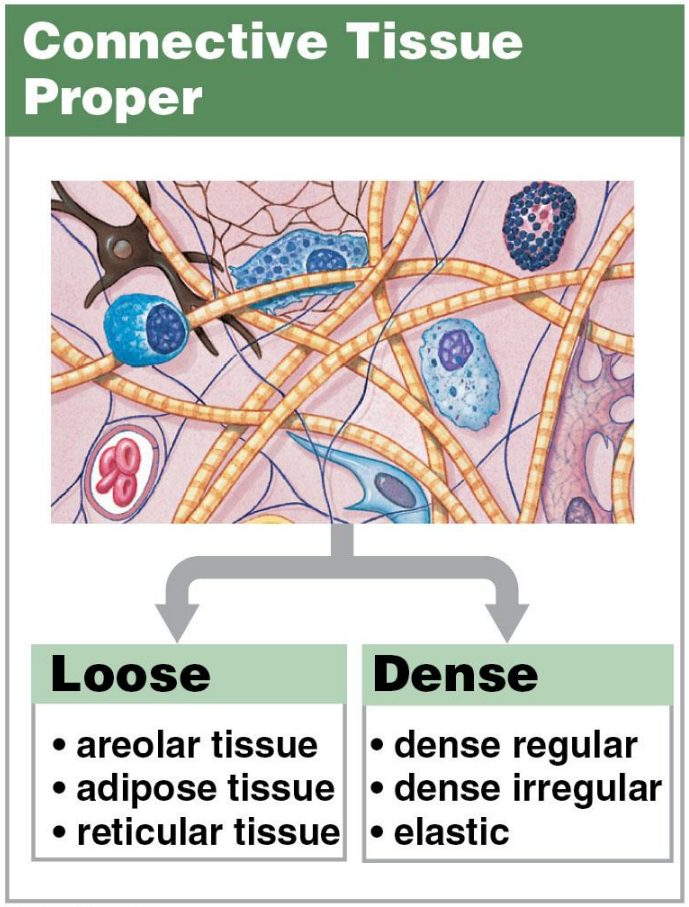

Module 4.10: Connective tissue

Three subdivisions of connective tissue (continued)

2. **Fluid connective tissue**
   - Distinctive group of cells
   - Watery matrix
     - **Blood** (within cardiovascular system)
     - **Lymph** (within lymphatic system)

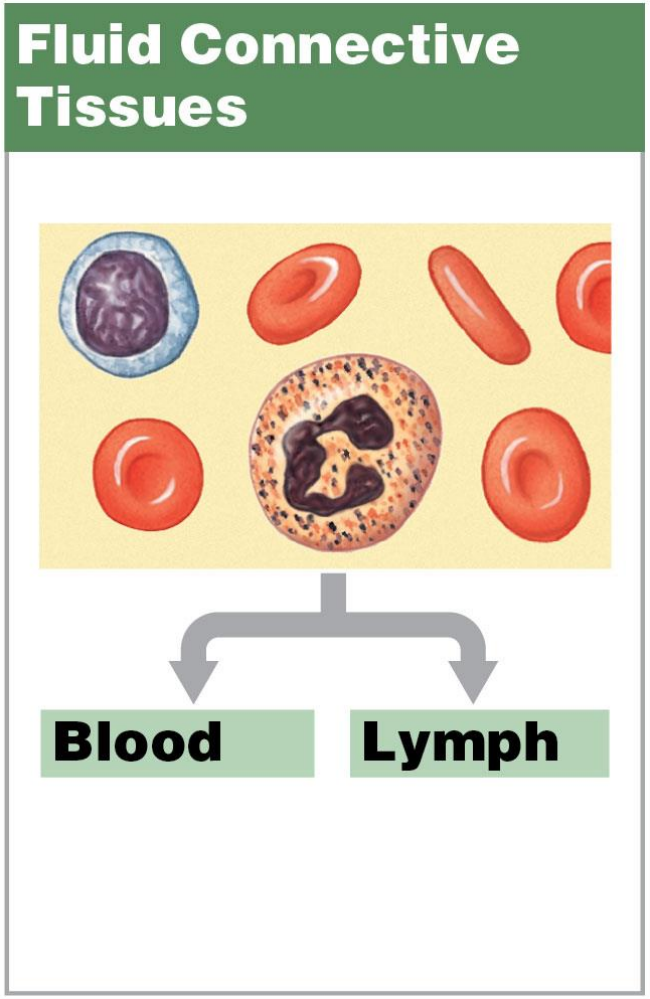

Module 4.10: Connective tissue

Three subdivisions of connective tissue (continued)

3. **Supporting connective tissue**
   - Less diverse cell population
   - More densely packed matrix
     - **Cartilage** (solid, rubbery matrix)
     - **Bone** (solid, crystalline matrix)

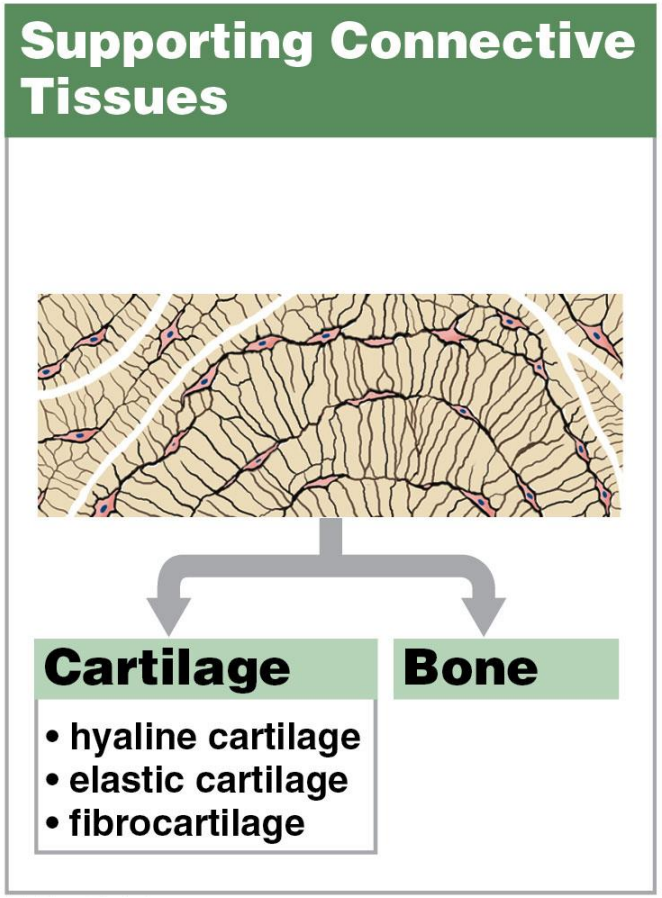

Module 4.10: Review

A. Identify the three basic components of connective tissue.
B. Summarize the functions of connective tissue.
C. Distinguish among connective tissue proper, fluid connective tissues, and supporting connective tissues.

Learning Outcome: Describe the general structure of connective tissue.

Module 4.11: Loose connective tissues support other tissue types

Connective tissue proper components

- Extracellular protein fibers
  - **Reticular fibers** (strong and form branching network)
  - **Collagen fiber**s (thick, very strong)
  - **Elastic fibers** (slender, very stretchy)
- Ground substance
  - Clear and colorless
  - Viscous (syrupy) due to presence of proteoglycans and glycoproteins

Module 4.11: Loose connective tissue

Connective tissue proper components (continued)

- Two classes of cells
  1. Fixed (stationary; involved with maintenance, repair, energy storage)
     - **Melanocytes** (synthesize melanin pigment)
     - **Fixed macrophage** (engulfs cell debris and pathogens)
     - **Mast cells** (stimulate inflammation and mobilize defenses)

Module 4.11: Loose connective tissue

Connective tissue proper components (continued)

- Two classes of cells
  1. Fixed
     - **Fibroblasts** (synthesize extracellular fibers)
     - **Adipocytes** (store lipid reserves)
     - **Fibrocytes** (differentiate from fibroblasts and maintain extracellular fibers)

Module 4.11: Loose connective tissue

Connective tissue proper components (continued)

- Two classes of cells
  2. Wandering (move throughout tissue; function in defense and repair)
     - **Plasma cells** (immune cells producing antibodies)
     - **Free macrophages** (engulf debris and pathogens)
     - **Mesenchymal cells** (stem cells that aid tissue repair)
     - **Neutrophils** and **eosinophils** (phagocytic blood cells)
     - **Lymphocytes** (immune system cells)

Connective tissue components

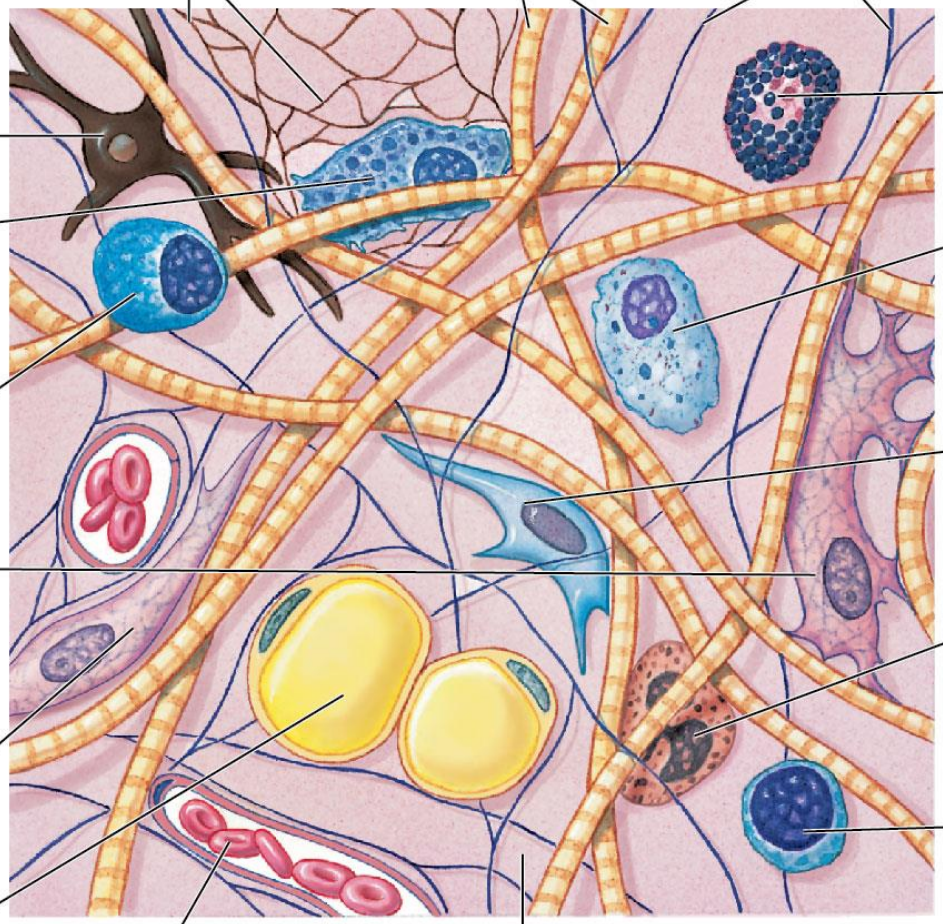

Module 4.11: Loose connective tissue

Three types of loose connective tissue

1. **Areolar tissue**
   - Most common connective tissue proper
   - Packing material of the body
   - Has all connective tissue proper cell types

Module 4.11: Loose connective tissue

Three types of loose connective tissue (continued)

2. **Adipose tissue**
   - Found deep to skin in various areas of body
   - Forms layer of padding around eyes and kidneys
   - Cells (adipocytes) account for most of tissue volume

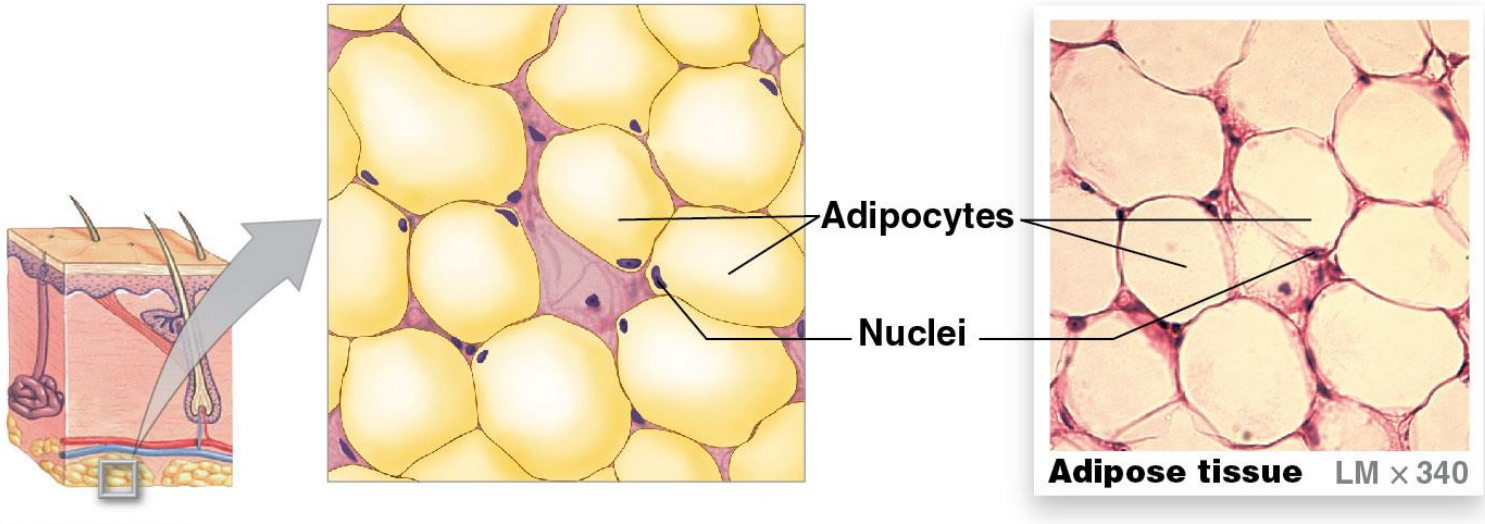

Module 4.11: Loose connective tissue

Three types of loose connective tissue (continued)

3. **Reticular tissue**
   - Found in liver, kidney, spleen, lymph nodes, and bone marrow
   - Provides support and resists distortion
   - Many reticular fibers forming network (**stroma**)

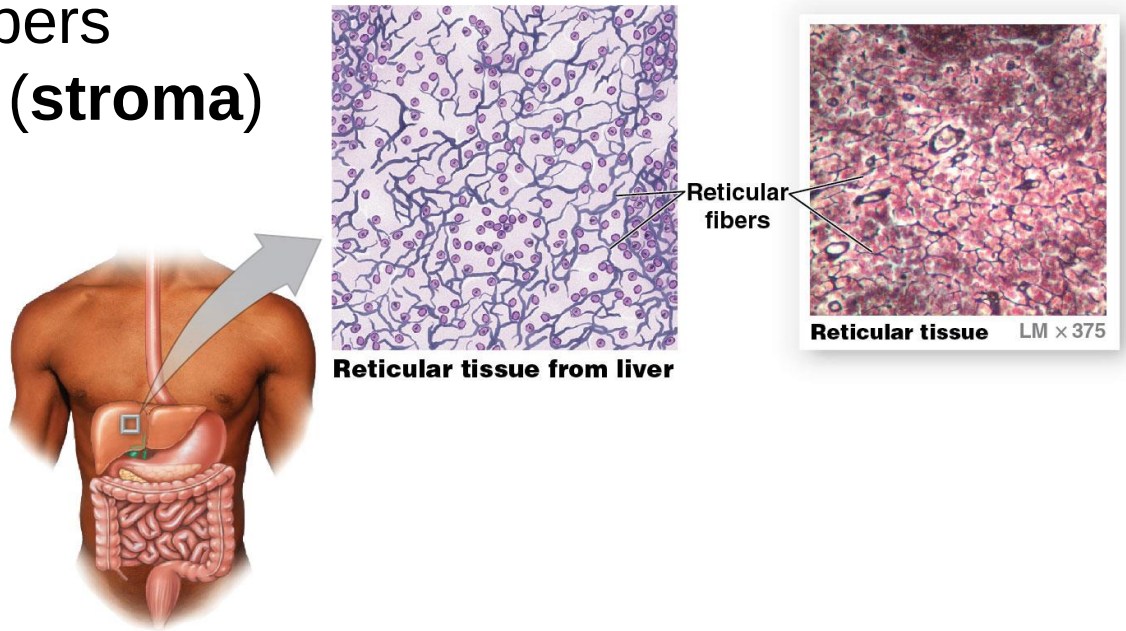

Module 4.11: Review

A. Identify the types of cells found in connective tissue proper.
B. Describe the role of fibroblasts in connective tissue.
C. Which type of loose connective tissue contains primarily lipids?
D. What term means the fibrous supporting network formed of reticular fibers?
E. What types of phagocytic cells are present in connective tissue proper?

Learning Outcome: Describe the structure, function, and locations of areolar tissue, adipose tissue, and reticular tissue.

Module 4.12: Dense connective tissues are dominated by extracellular fibers …

Three types of dense connective tissues

- Most volume occupied by extracellular fibers
  1. **Dense regular connective tissue**
     - Found in cords (tendons, ligaments) or sheets
     - Collagen arranged in parallel bundles

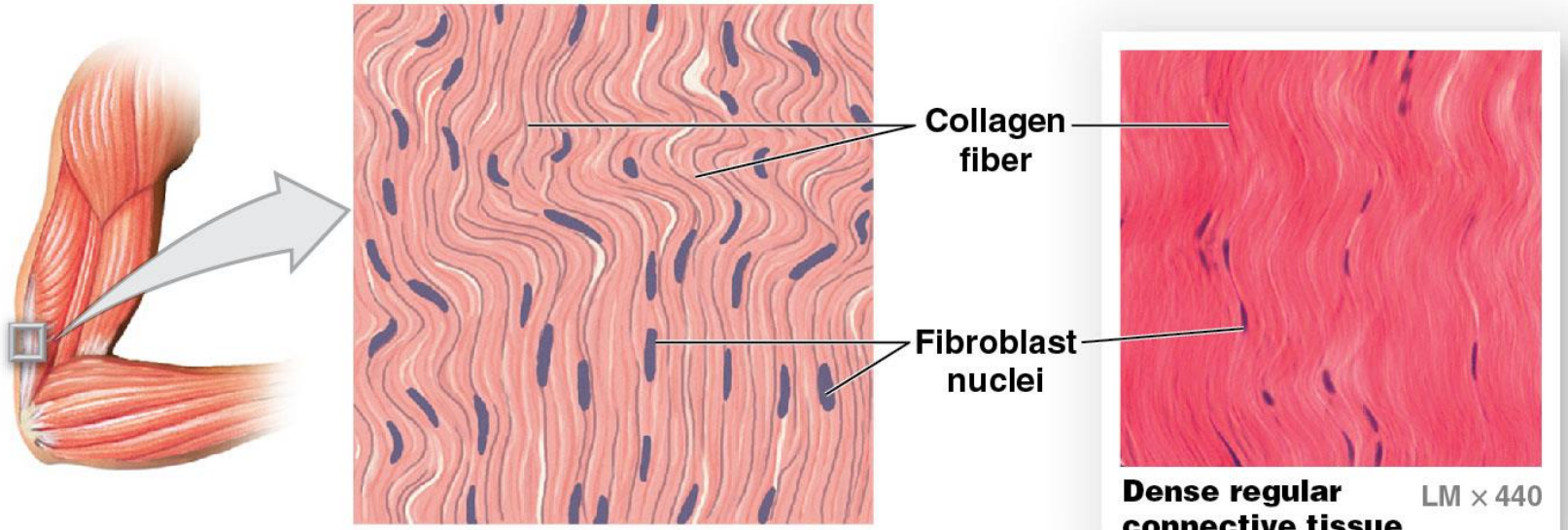

Module 4.12: Dense connective tissue

Three types of dense connective tissue (continued)

2. **Dense irregular connective tissue**
   - Fibers arranged in meshwork (no consistent pattern) to resist tension in many directions
   - Found covering visceral organs; in superficial layers of bones, cartilages, and peripheral nerves; in dermis of skin

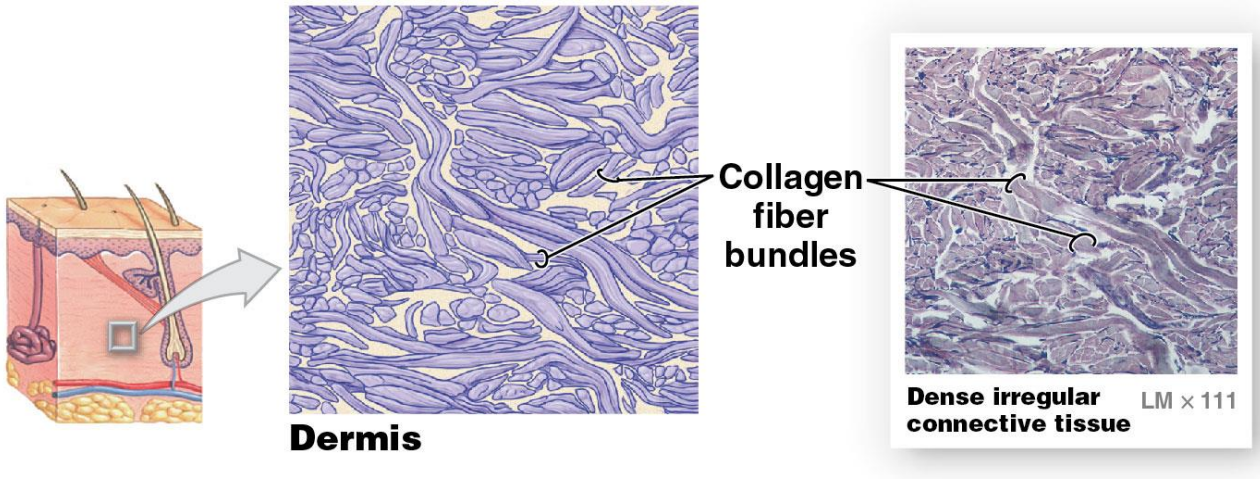

Module 4.12: Dense connective tissue

Three types of dense connective tissue (continued)

3. **Elastic tissue**
   - More elastic fibers than collagen
   - Is springy and resilient
   - Found between vertebrae, in walls of large blood vessels, erectile tissues of penis

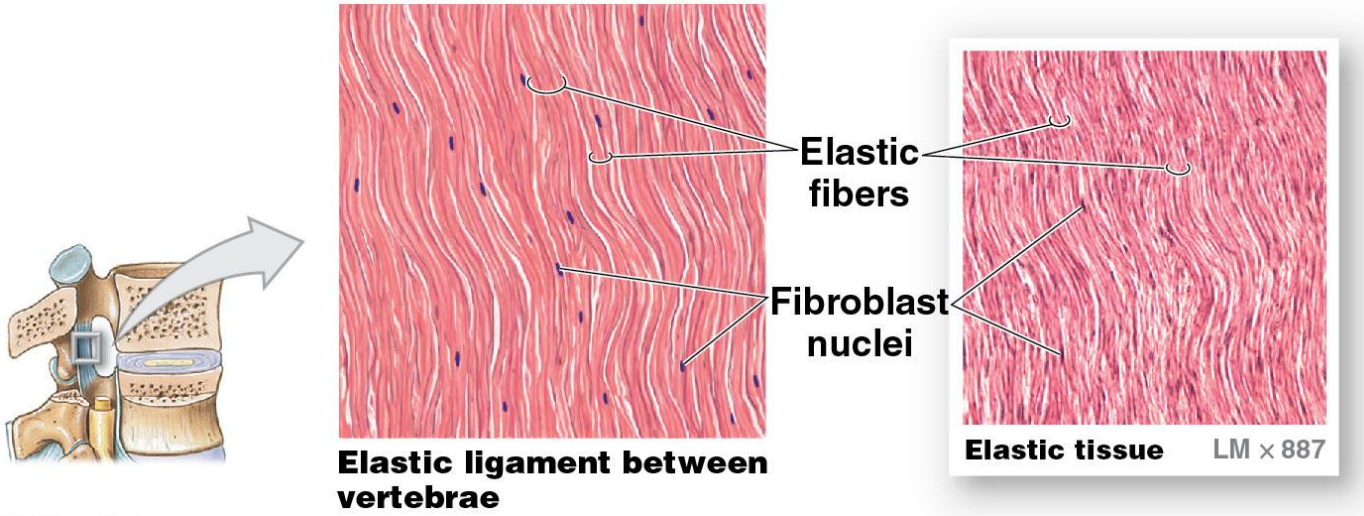

Module 4.12: … whereas fluid connective tissues have an aqueous matrix

Fluid connective tissue

- Fluid matrix with many suspended proteins
- Usually contains no insoluble fibers
- Two types of liquid connective tissue
  1. **Blood**
  2. **Lymph**

Module 4.12: Fluid connective tissue

Fluid connective tissue (continued)

- **Blood components**
  - Watery matrix called **plasma**
  - **Formed elements** suspended in plasma
    - **Red blood cells** (transport oxygen)
    - **White blood cells** (bodily defense)
      - **Monocytes** (large phagocytes)
      - **Lymphocytes** (uncommon in blood)
      - **Eosinophils/neutrophils** (small phagocytes)
      - **Basophils** (promote inflammation)
    - **Platelets** (involved in clotting response)

Blood as fluid connective tissue

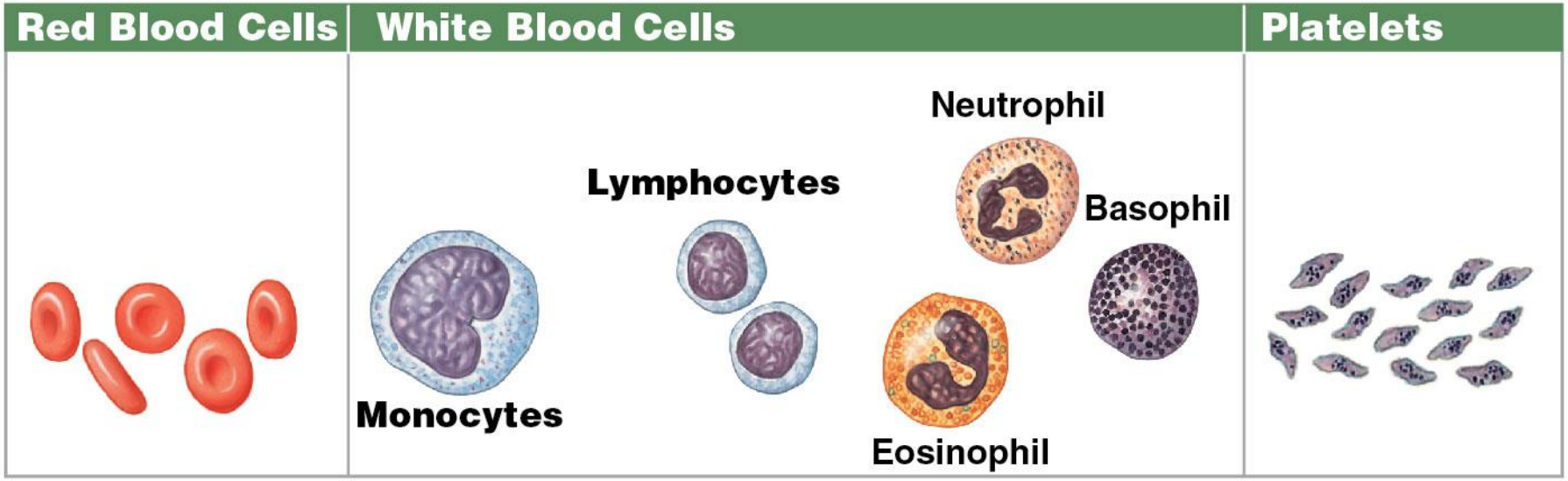

Module 4.12: Fluid connective tissue

Fluid connective tissue (continued)

- **Lymph**
  - Watery matrix called lymph located in lymphatic vessels
  - Collected from interstitial fluid
  - Majority of cells are lymphocytes
  - Returned to blood at large veins near heart
  - Functions to maintain solute levels, blood volume, and alert immune system of infection

Module 4.12: Fluid connective tissue

Fluid connective tissue (continued)

- Extracellular fluid circulation
  - Contractions of the heart move blood through blood vessels
    - **Arteries** (away from heart)
    - **Capillaries** (smallest vessels; sites of exchange)
    - **Veins** (toward heart)
  - Water and solutes exchanged between plasma and interstitial fluid
  - Lymphatic vessels collect excess interstitial fluid
  - Lymphatic vessels return lymph to large veins near heart

Lymph as fluid connective tissue

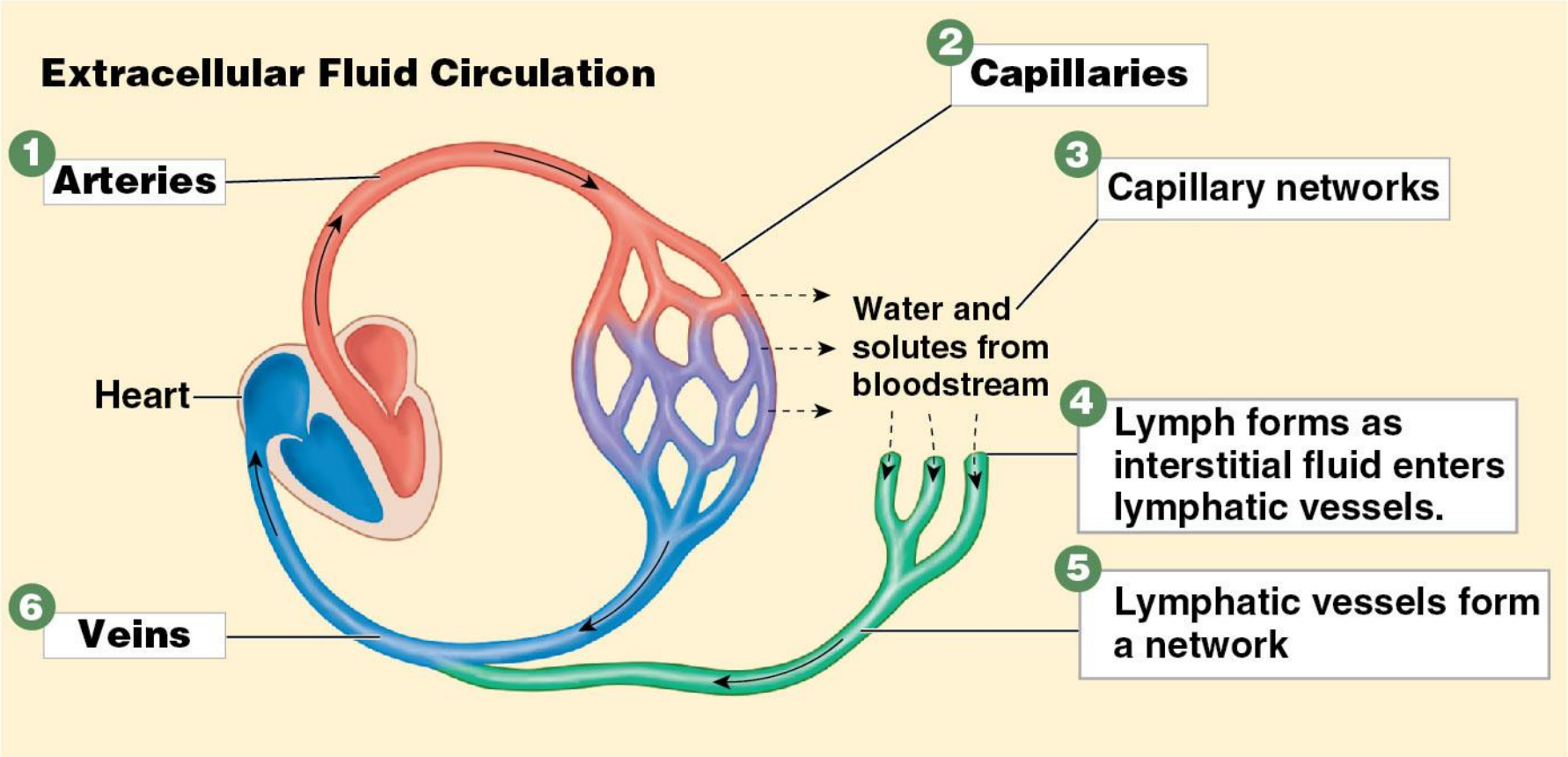

Module 4.12: Review

A. What makes a connective tissue “loose” or “dense”?
B. Summarize the role of extracellular fluid in maintaining homeostasis.
C. Lack of vitamin C in the diet interferes with the ability of fibroblasts to produce collagen. How might this affect connective tissue function?

Learning Outcome: Describe the structure, function, and locations of dense connective tissues and fluid connective tissues.

Module 4.13: Cartilage provides a flexible support for body structures

Cartilage overview

- Matrix is a firm gel containing **chondroitin sulfates** (*chondros*, cartilage), polysaccharide derivatives
  - Form complexes with proteins forming proteoglycans
- Only one type of cell (**chondrocyte**)
  - Found in small chambers called **lacunae** (*lacus*, lake)
- Avascular

Module 4.13: Cartilage

Three types of cartilage

1. **Hyaline cartilage**
   - Found between ribs and sternum, covering bones in mobile joints, part of nasal septum, supporting respiratory passageways
   - Provides stiff but flexible support
   - Reduces friction

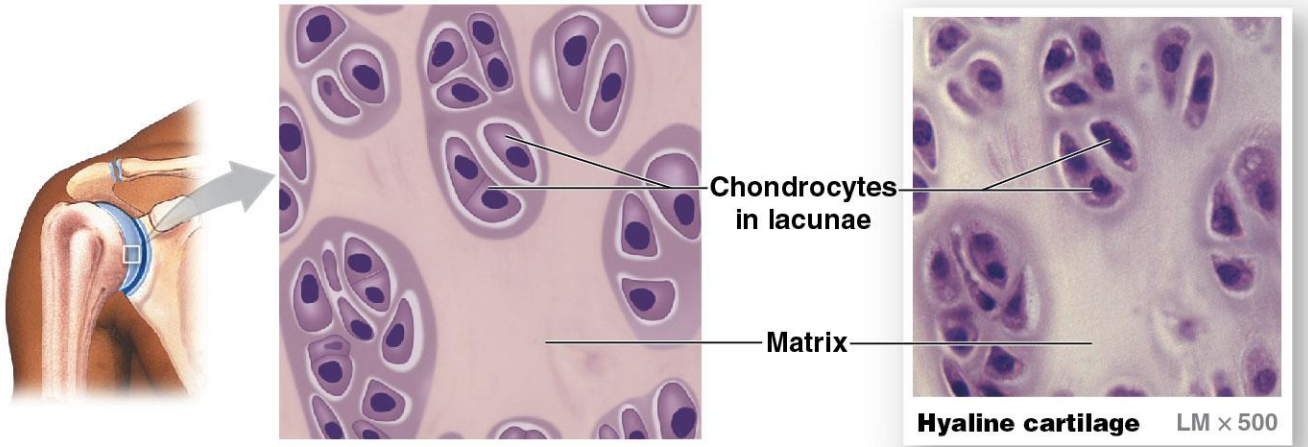

Hyaline cartilage from shoulder joint

Module 4.13: Cartilage

Three types of cartilage (continued)

2. **Elastic cartilage**
   - Distorts without damage and returns to original shape
   - Found in external ear and smaller internal structures

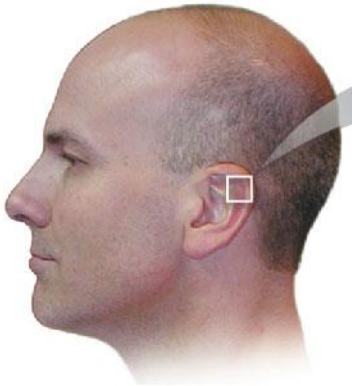

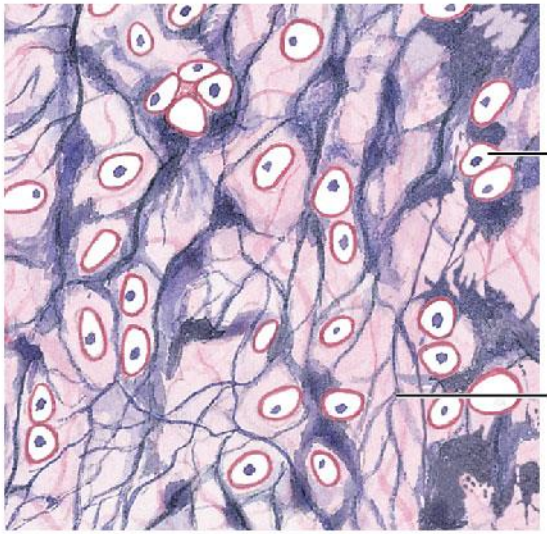

Elastic cartilage from external ear

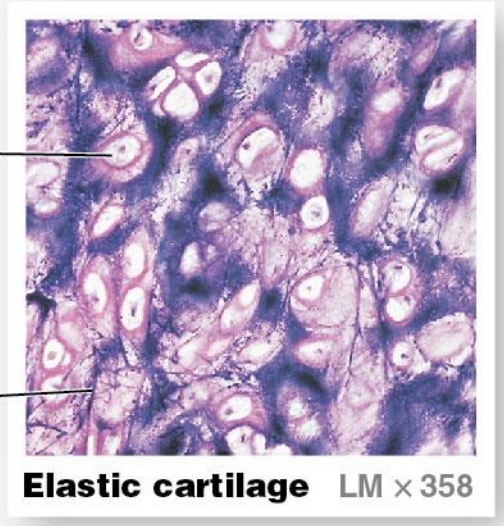

Elastic cartilage LM × 358

Module 4.13: Cartilage

Three types of cartilage (continued)

3. **Fibrocartilage**
   - Found in knee joint, between pubic bones, and in intervertebral discs
   - Durable and tough
   - Resists compression, prevents bone-to-bone contact, and limits relative movement

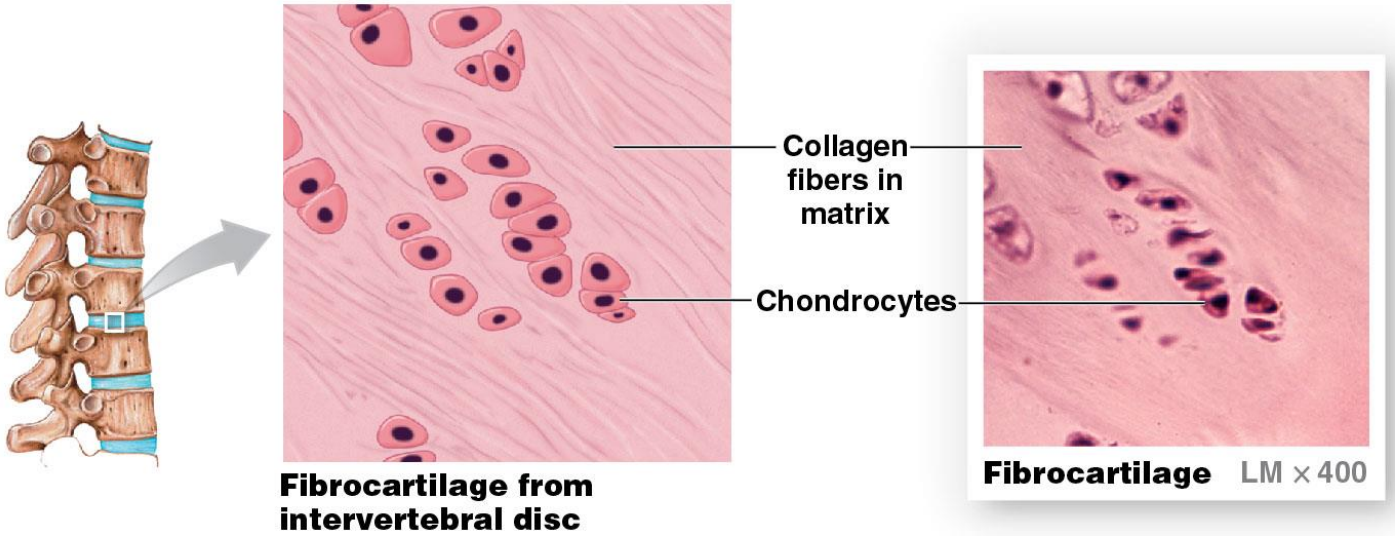

Module 4.13: Cartilage

Cartilage properties

- Set apart from surrounding tissues by **perichondrium** (*peri-*, around)
  - Two layers of perichondrium
    1. Outer layer of dense irregular connective tissue
       - Mechanical support, protection, attachment
    2. Inner cellular layer
       - Where cartilage growth and maintenance occur
  - Blood vessels in perichondrium provide oxygen and nutrients to chondrocytes

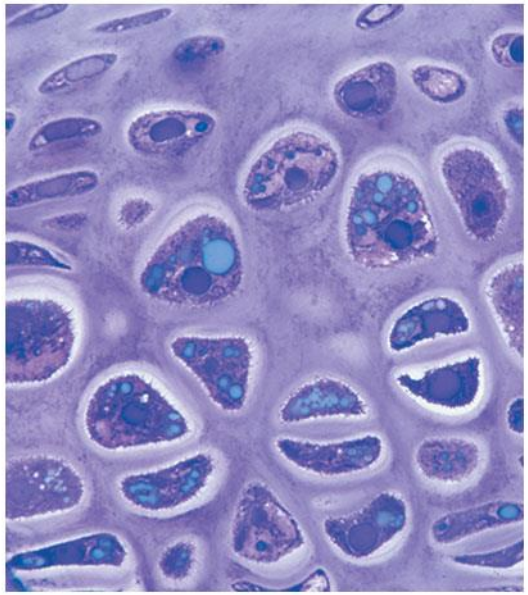

Hyaline cartilage LM × 250

Module 4.13: Cartilage

Two types of cartilage growth

1. **Appositional growth** (at cartilage surface)
   - **Chondroblasts** (immature chondrocytes) divide in cellular layer of perichondrium
   - Chondroblasts secrete new matrix
   - Once surrounded by matrix, chondroblasts mature into chondrocytes

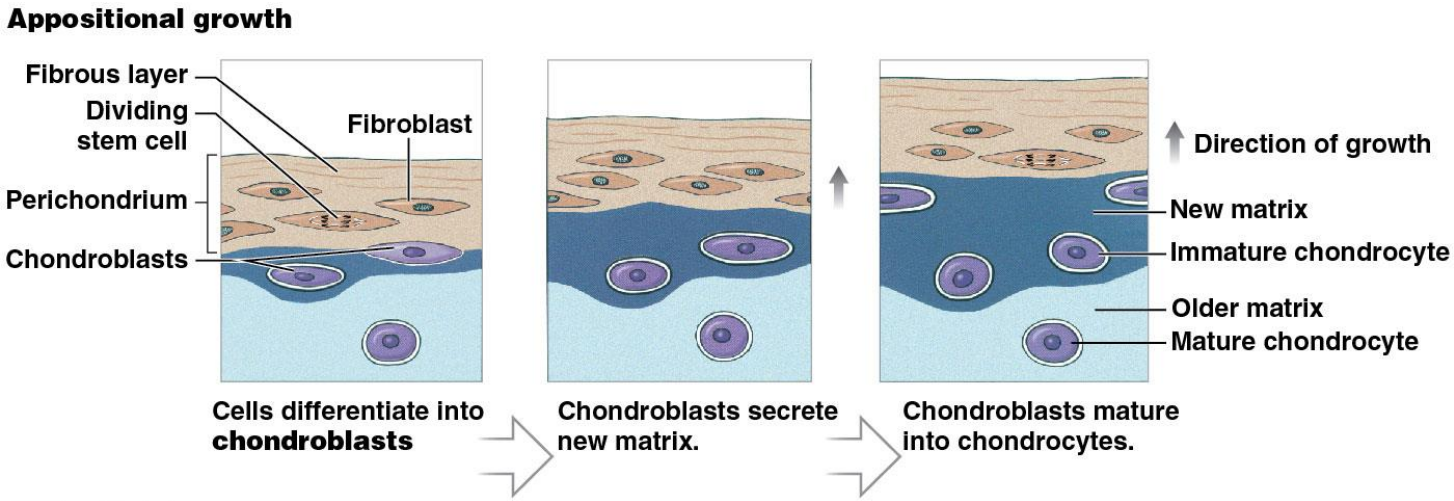

Module 4.13: Cartilage

Two types of cartilage growth (continued)

2. **Interstitial growth (within cartilage)**
   - Chondrocytes divide within a lacuna
   - Daughter cells secrete additional matrix and move apart
   - Both types of cartilage growth occur during development
   - Normally no growth and repair in adults
   - With slight damage or with hormonal stimulation, some appositional growth possible

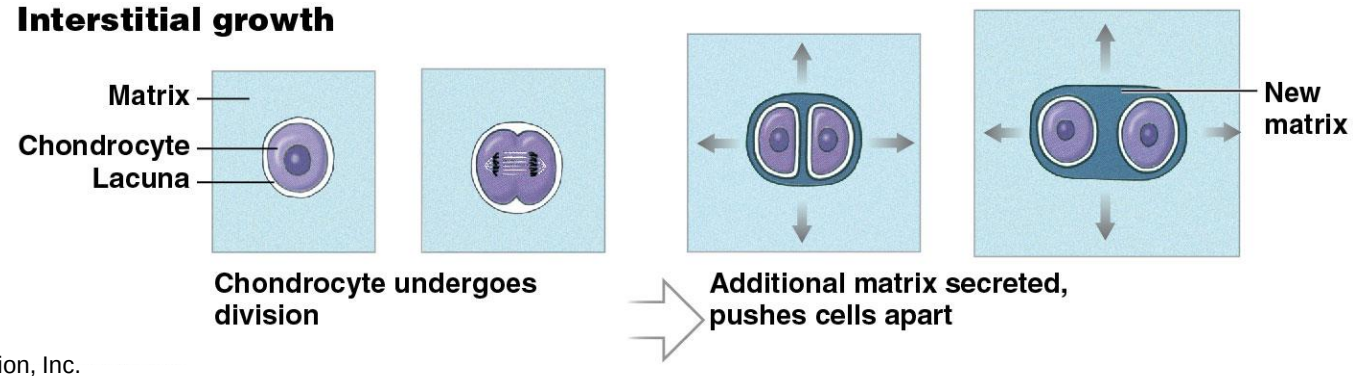

Module 4.13: Review

1. Which connective tissue fiber is characteristic of the cartilage supporting the ear?
2. Describe the two layers making up the perichondrium.
3. Contrast appositional and interstitial growth of cartilage.

Learning Outcome: Describe the structure, function, and locations of cartilage.

Module 4.14: Bone provides a strong framework for the body

Osseous (*os*, bone) **tissue (Bone tissue)**

- Connective tissue with solid, crystalline matrix
  - Small volume of ground substance
  - 2/3 of matrix is calcium salts (provide strength)
    - Mostly calcium phosphate
    - Some calcium carbonate
  - Many collagen fibers (provide flexibility)
- Strong, somewhat flexible, resistant to shattering

Module 4.14: Bone

Typical long bone structure

- Hollow with two types of bone
  1. **Compact bone**
     - Outer layer of bone
  2. **Spongy bone**
     - Lines internal cavity
     - Finer network

Typical long bone structure

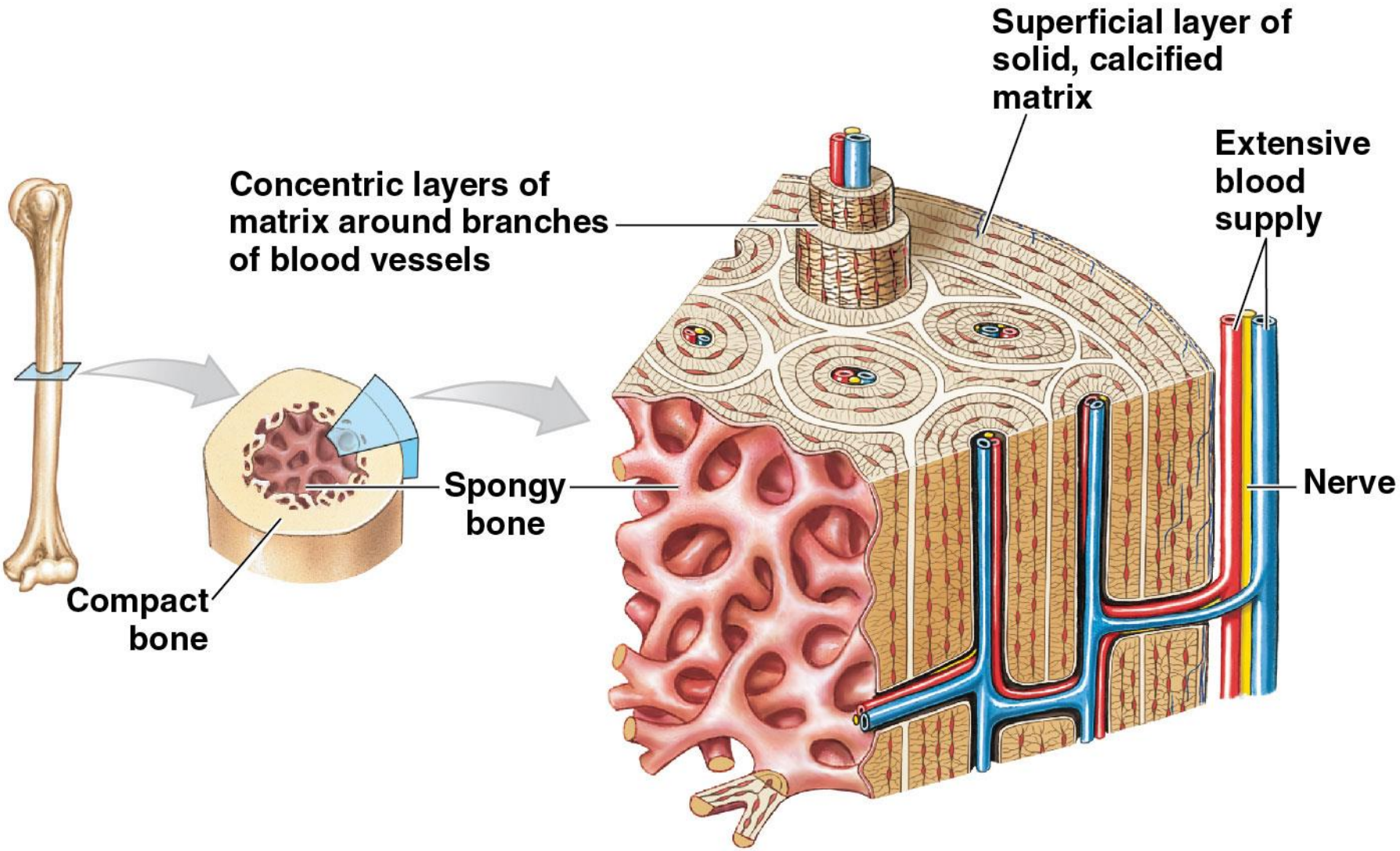

A Comparison of Cartilage and Bone

Characteristic	Cartilage	Bone
Cells	Chondrocytes in lacunae	Osteocytes in lacunae
Ground substance	Chondroitin sulfate (in proteoglycan) and water	A small volume of liquid surrounding insoluble crystals of calcium salts
Fibers	Collagen, elastic, and reticular fibers in varying proportions	Collagen fibers predominate
Vascularity	No internal blood vessels	Extensive blood vessels
Covering	Perichondrium (two layers)	Periosteum (two layers)
Strength	Limited: bends easily, but hard to break	Strong: resists distortion until breaking point

Module 4.14: Bone

Compact bone structure

- Matrix organized in concentric layers
  - Organized into functional units (**osteons**)
    - **Central canal** contains blood vessels in center
  - Cells (**osteocytes**) located between layers
  - **Canaliculi** (little canals) connect osteocytes
- Superficial layer of solid, calcified bone prevents interstitial growth

Module 4.14: Bone

Compact bone structure (continued)

- Surrounded by **periosteum**
  - Two layers
    1. Outer fibrous layer allows attachment of ligaments
    2. Inner cellular layer allows appositional growth and repair

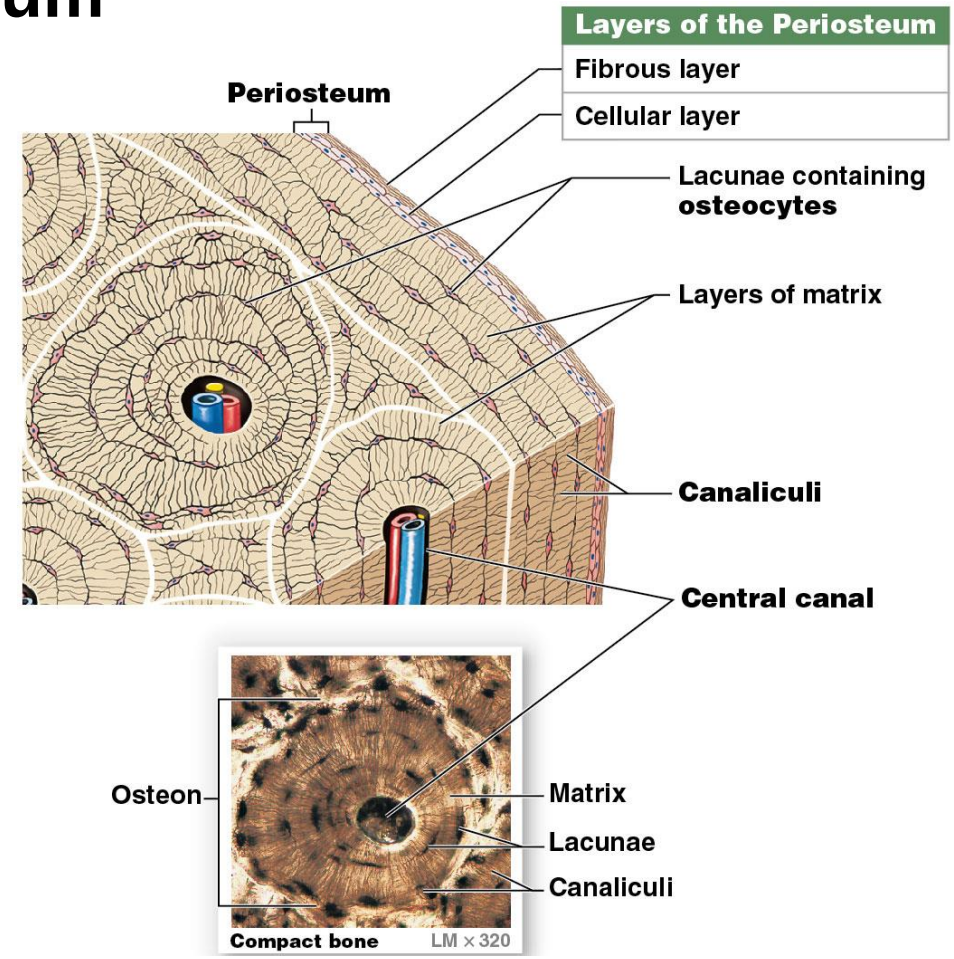

Module 4.14: Review

A. Describe bone matrix.
B. What are mature bone cells in lacunae called?
C. What is the functional unit of compact bone?
D. Distinguish between the two types of supporting connective tissues with respect to their characteristic fibers.

Learning Outcome: Describe the structure and function of bone.

Module 4.15: Tissues membranes are physical barriers, and fasciae support and surround organs

Overview of membranes

- Line or cover body surfaces
- Typically consist of epithelium supported by connective tissue
- Four types in the body
  1. Mucous membranes
  2. Serous membranes
  3. Cutaneous membrane
  4. Synovial membranes

Module 4.15: Membranes and fasciae

Four types of membranes

1. **Mucous membranes**
   - Line passageways open to the exterior of the body
     - Digestive, respiratory, reproductive, urinary tracts
   - Must be kept moist to facilitate movement, absorption, or secretion
   - Lubricated by mucus or bodily fluids
   - Supported by areolar connective tissue (**lamina propria**)

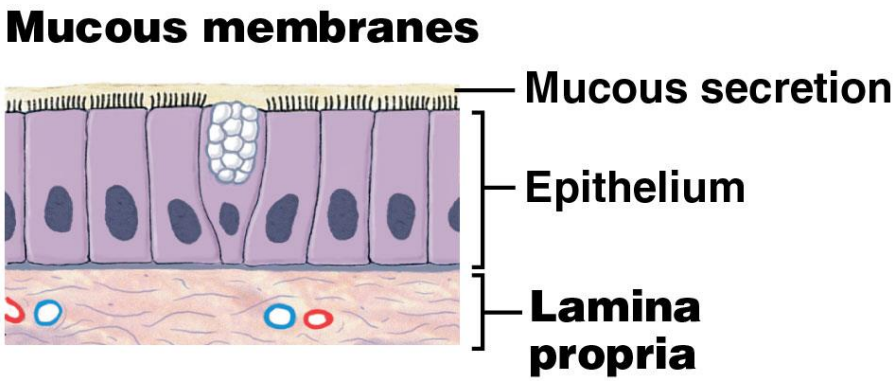

Module 4.15: Membranes and fasciae

Four types of membranes (continued)

2. **Serous membranes (*serosae*)**
   - Composed of mesothelium supported by areolar connective tissue
   - Delicate and never connected to exterior
   - Watery **serous fluid** coats surface
   - Three line subdivisions of ventral body cavity
     - **Pleura** (pleural cavity and lungs)
     - **Pericardium** (pericardial cavity and heart)
     - **Peritoneum** (peritoneal cavity and visceral organs)

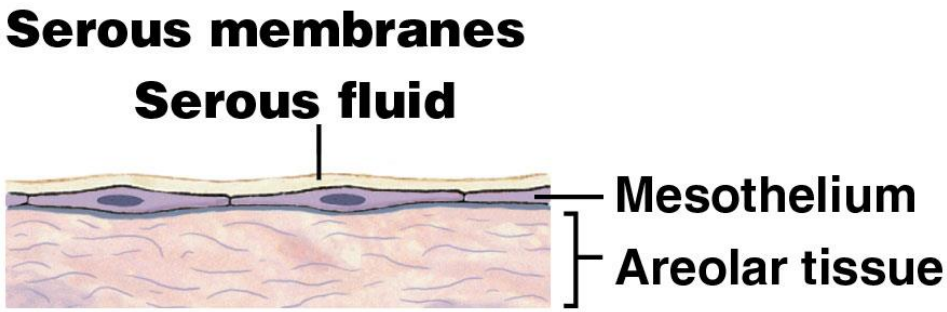

Module 4.15: Membranes and fasciae

Four types of membranes (continued)

3. **Cutaneous membrane**
   - Covers surface of body (skin)
   - Composed of:
     - Stratified squamous epithelium
     - Layer of areolar tissue
     - Underlying dense irregular connective tissue
   - Relatively thick, waterproof, and usually dry

Cutaneous membrane

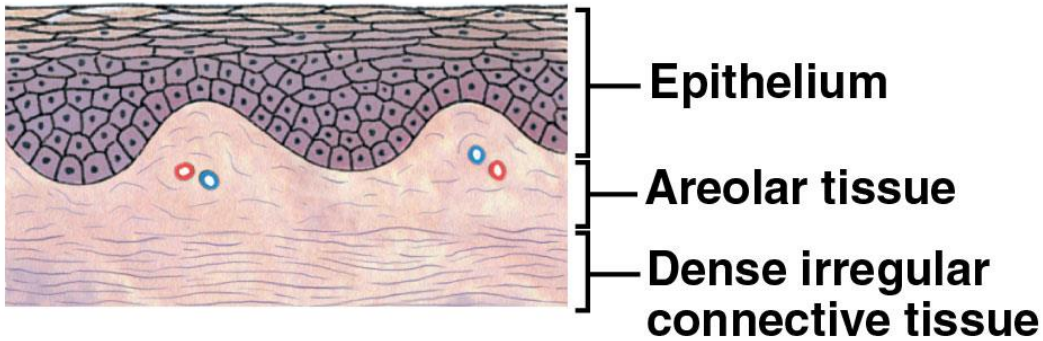

Module 4.15: Membranes and fasciae

Four types of membranes (continued)

4. **Synovial membrane**
   - Lines freely movable joint cavities
   - Lubricates joint cavity with synovial fluid
   - Provides oxygen and nutrients to cartilage cells
   - Not true epithelium
     - Develops within connective tissue
     - Lacks basement membrane
     - Contains gaps between cells (up to 1 mm)
     - **Synovial fluid** and capillaries continuously exchange fluid and solutes

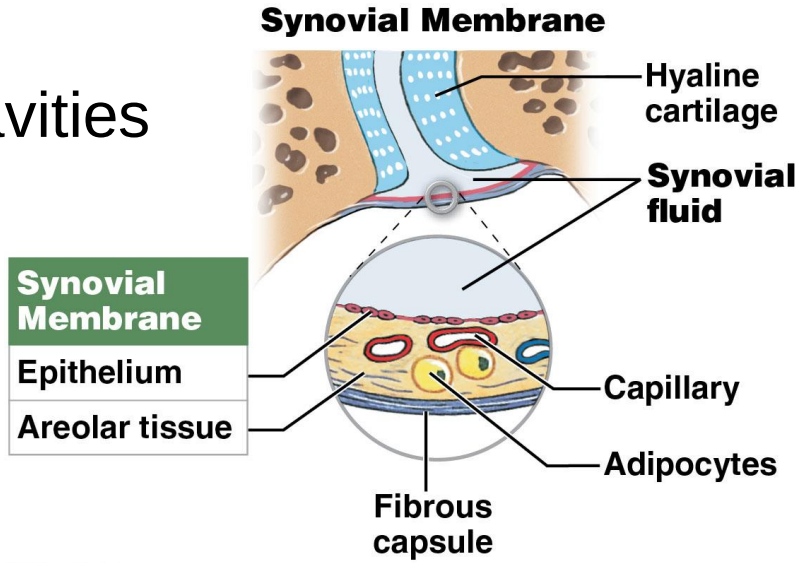

Module 4.15: Membranes and fasciae

Fasciae: Support and surround organs

- Three types of layers
  1. **Superficial fascia**
     - Under skin
     - Consists of areolar and adipose tissue
  2. **Deep fascia**
     - Continuous with capsules, ligaments, and other connective tissue structures
     - Consists of dense irregular connective tissue
     - Forms strong, fibrous internal framework
  3. **Subserous fascia**
     - Between serous membranes and deep fascia
     - Consists entirely of areolar tissue

Connective tissue framework of the body

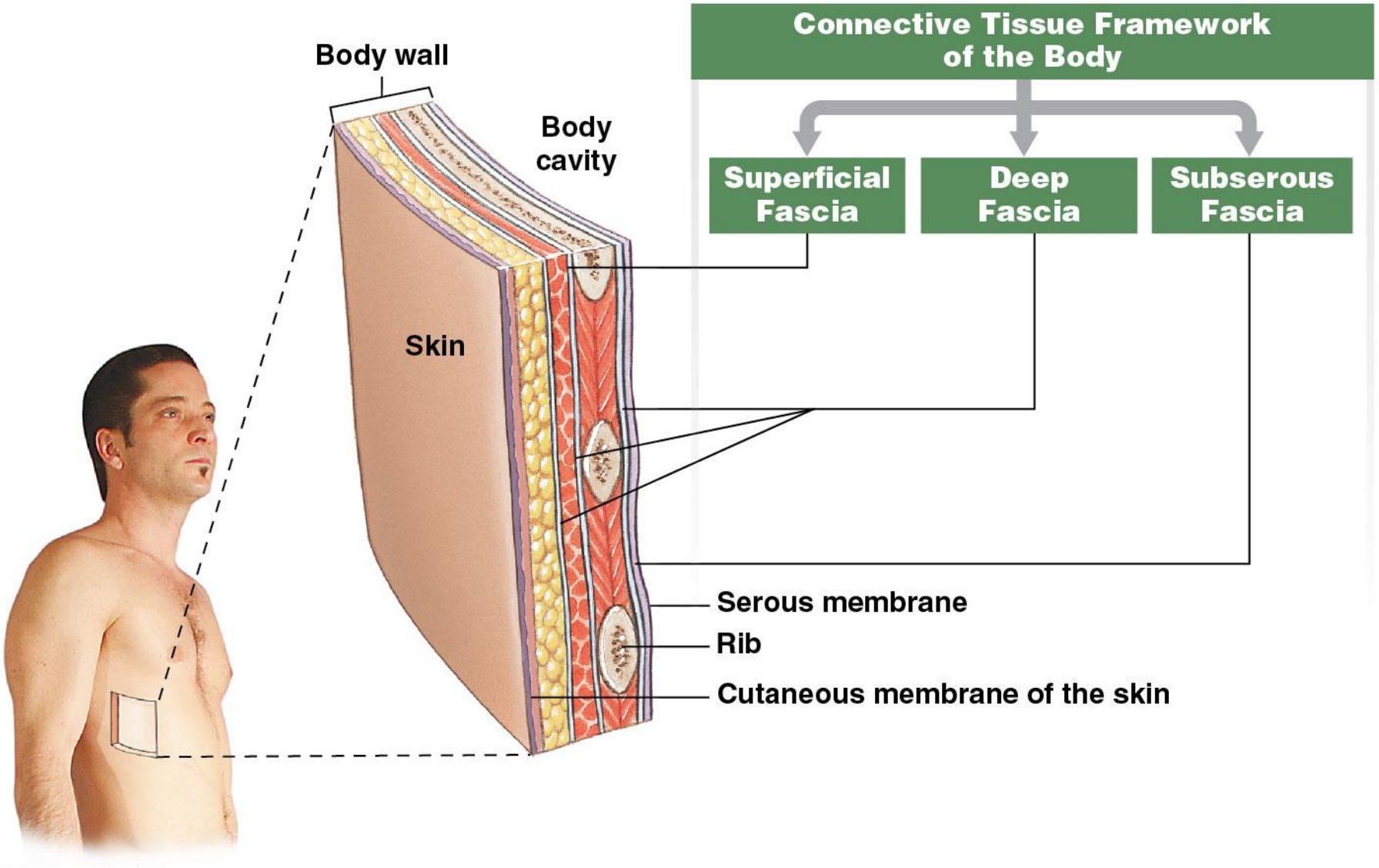

Module 4.15: Review

A. Which cavities in the body are lined by serous membranes?
B. Name the four types of membranes found in the body.
C. Name the three layers of fascia and their types of connective tissue.
D. Which of the four tissue membranes is relatively waterproof and usually dry?

Learning Outcome: Describe the arrangements of epithelial and connective tissues in the four types of tissue membranes, and describe the structures and locations of the three types of fasciae.

Section 3: Muscle Tissue and Nervous Tissue

Learning Outcomes

4.16 Describe the relative proportions of muscle tissue and nervous tissue in the body.

4.17 Specify the functions of muscle tissue and nervous tissue.

4.18 **Clinical Module:** Describe the roles of inflammation and regeneration in response to tissue injury.

Module 4.16: Muscle tissue outweighs nervous tissue by 25:1

Tissue types by weight

- Muscle tissue is 50 percent total body weight
  - The most of any major tissue type
- Nervous tissue is 2 percent total body weight
  - The least of any major tissue type
- Connective tissue (45 percent) and epithelial tissue (3 percent) provide interwoven framework for body

Percentages (by weight) of the four tissue types in the body

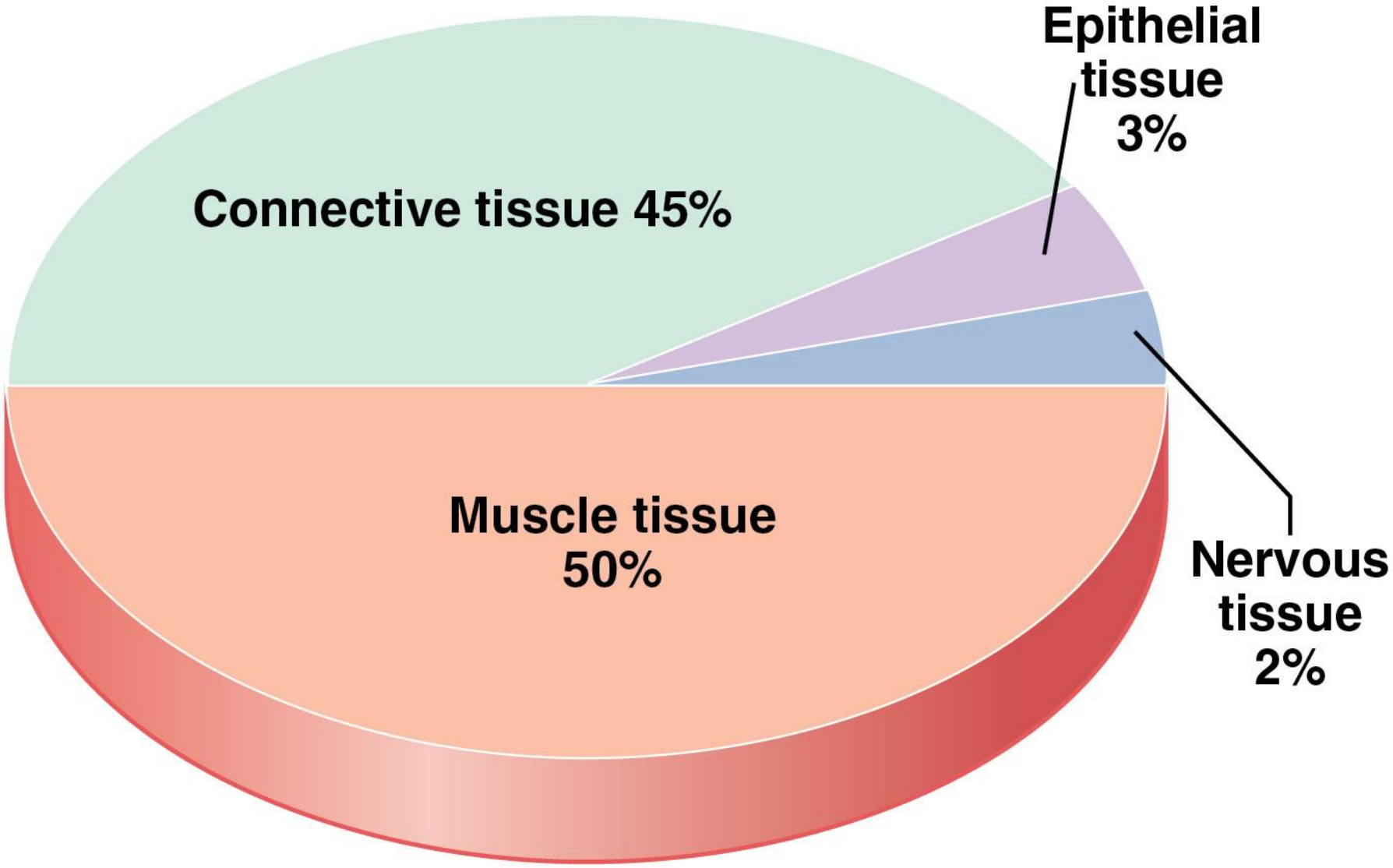

Module 4.16: Muscle tissue and nervous tissue

Types of muscle tissue

- **Skeletal muscle tissue**
  - Moves the body
- **Cardiac muscle tissue**
  - Moves blood within the heart and through blood vessels
- **Smooth muscle tissue**
  - Moves fluids and solids along digestive tract
  - Regulates diameter of small arteries, among other functions

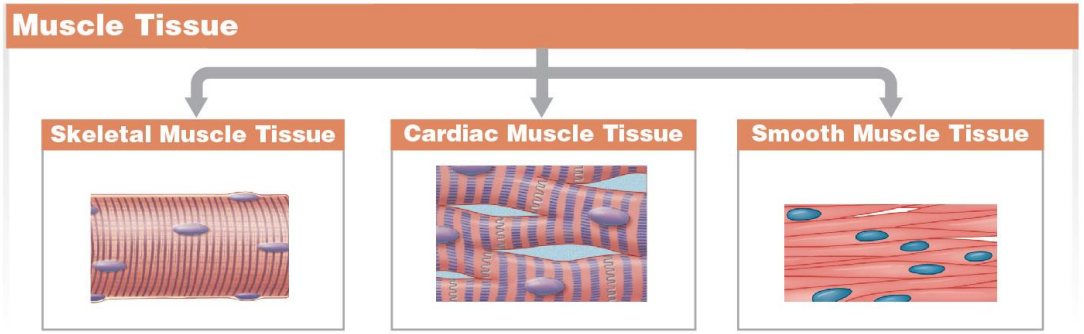

Module 4.16: Review

A. What is the relative percentage of body weight from each of the four tissue types?
B. List the three classifications of muscle tissue, and describe a function for each type.

Learning Outcome: Describe the relative proportions of muscle tissue and nervous tissue in the body.

Module 4.17: Muscle tissue is specialized for contraction …

Muscle tissue

- Specialized for contraction to cause movement
  - Movement of the body
  - Movement of blood around the cardiovascular system
  - Movement of materials along the digestive tract
- Three types of muscles
  1. **Skeletal muscle tissue**
  2. **Cardiac muscle tissue**
  3. **Smooth muscle tissue**

Module 4.17: Functions of muscle tissue

Three types of muscle tissue

1. **Skeletal muscle tissue**
   - Found in skeletal muscle
   - Elongated, cylindrical, banded (**striated**) cells with multiple nuclei (**multinucleate**)
   - Functions
     - Move and stabilizes skeleton
     - Guard entrances and exits to digestive, respiratory, urinary tracts
     - Generate heat
     - Protect internal organs

Skeletal muscle tissue

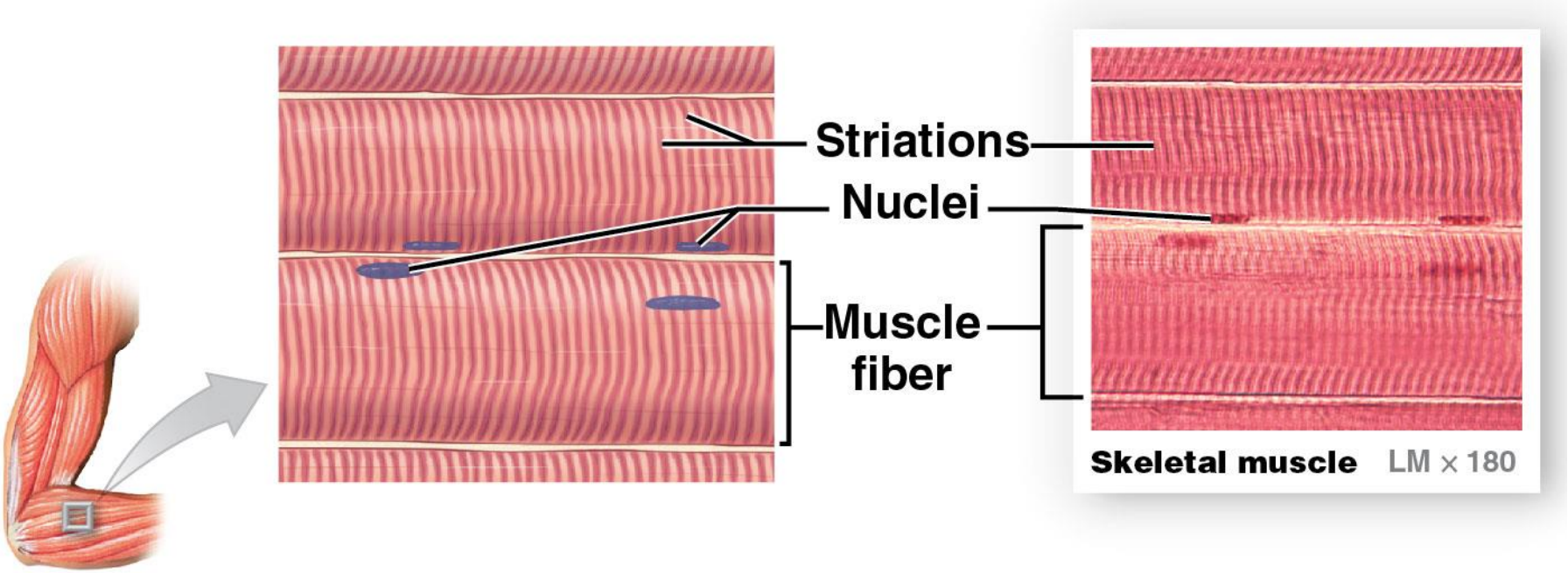

Module 4.17: Functions of muscle tissue

Three types of muscle tissue (continued)

2. **Cardiac muscle tissue**
   - Found only in heart
   - Cells (“cardiocytes”) are short, branched, and usually have a single nucleus
     - Interconnected with special junctions (**intercalated discs**) that help synchronize cardiocyte contractions
   - Functions to move blood and maintain blood pressure

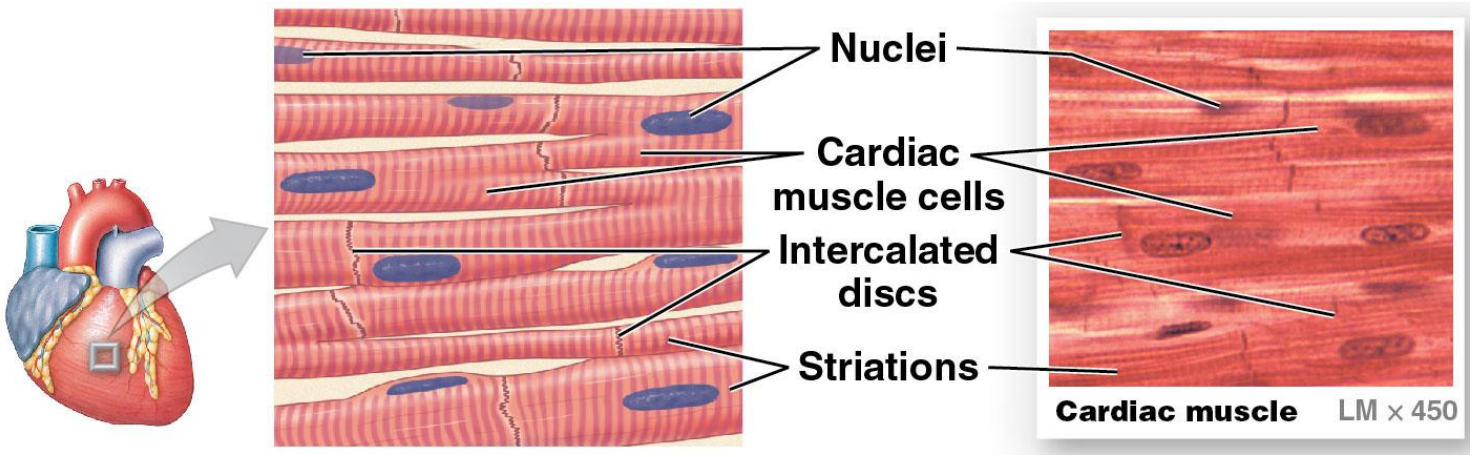

Module 4.17: Functions of muscle tissue

Three types of muscle tissue (continued)

3. **Smooth muscle tissue**
   - Found throughout body (skin, blood vessel walls, many organs of various systems)
   - Cells are short, spindle-shaped, nonstriated, have a single nucleus
   - Functions
     - Move food, urine, and reproductive secretions
     - Control diameter of respiratory passageways and blood vessels

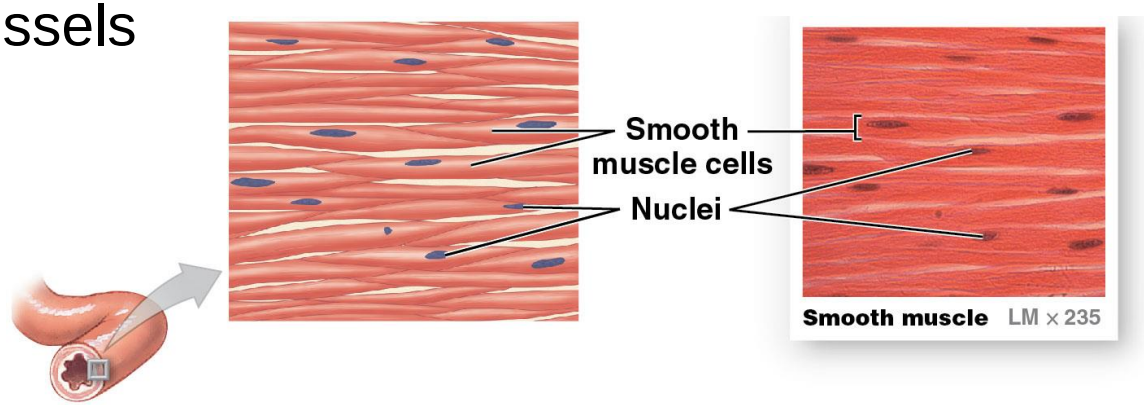

Module 4.17: … and nervous tissue is specialized for communication

Nervous tissue

- Specialized for conduction of electrical impulses
- 98 percent found in brain and spinal cord
- Two basic types of cells
  1. **Neurons** (*neuros*, nerve)
  2. **Neuroglia** or **glial cells** (*glia*, glue)
     - Various supporting cells

Module 4.17: Functions of nervous tissue

Neurons

- Transfer information around body and perform information processing
- Vary in size and shape
  - Longest cells in body are neurons (up to 1 meter)

Module 4.17: Functions of nervous tissue

Neuron structure

- **Dendrites** (*dendron*, tree)
  - Receive information
- **Axon**
  - Conducts information to other cells
  - Also called nerve fibers
- **Cell body**
  - Contains large nucleus and other organelles
  - Cell control center and site of information processing
  - Most lack centrioles and cannot divide

Neuron structure

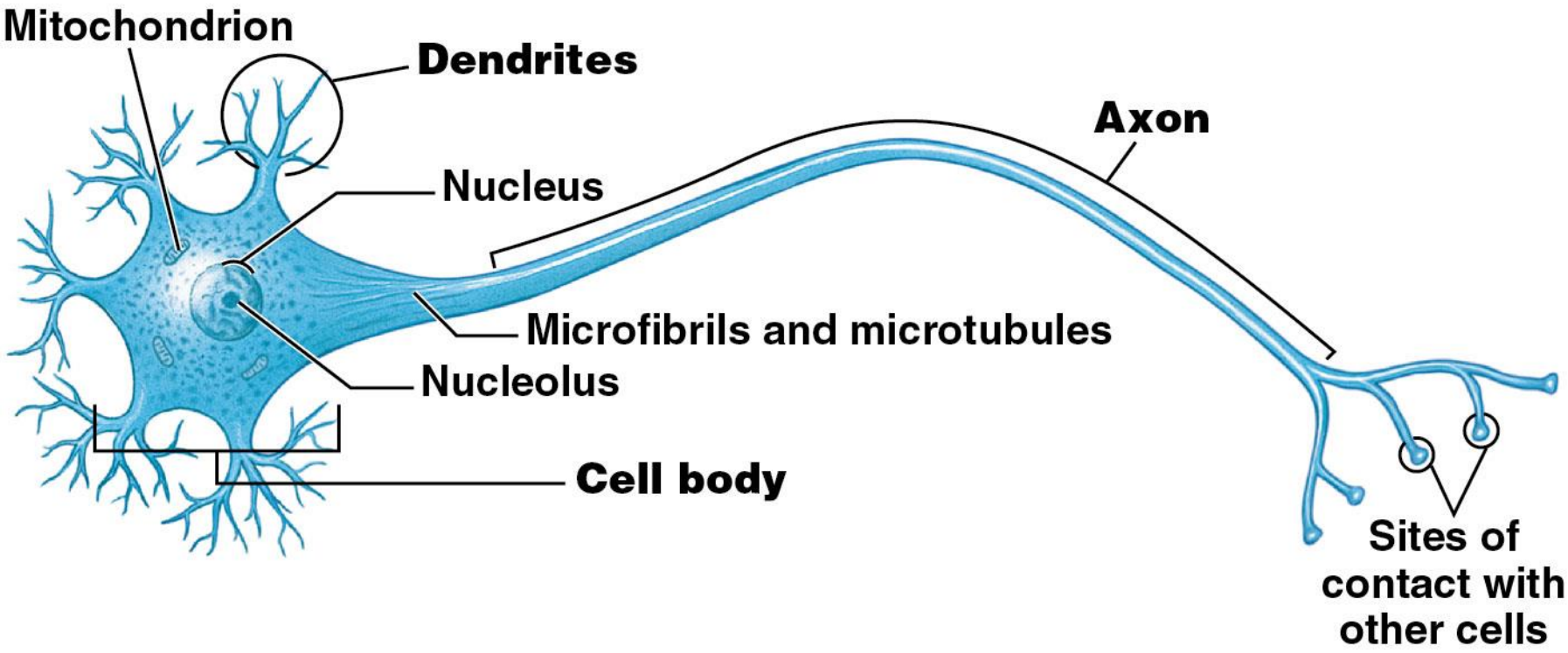

Module 4.17: Functions of nervous tissue

Neuroglia

- Several different structural types with associated functions

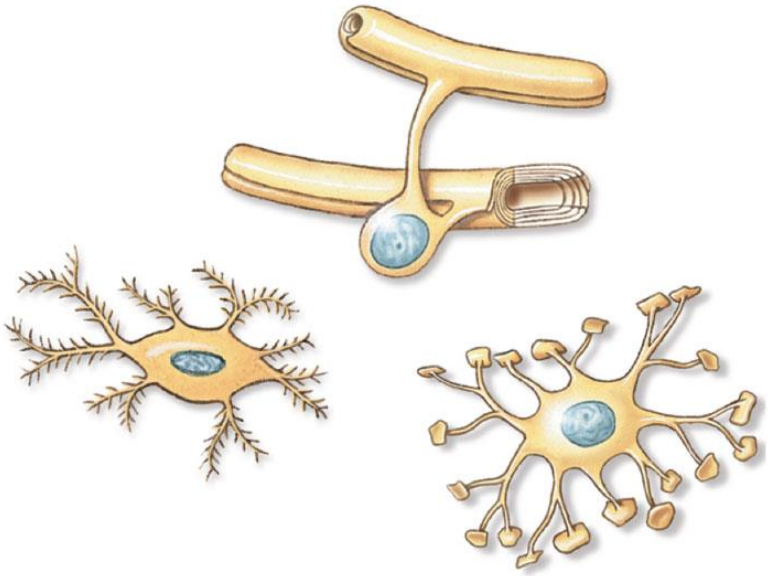

Functions of Neuroglia

- Maintain physical structure of nervous tissue
- Repair nervous tissue framework after injury
- Perform phagocytosis
- Provide nutrients to neurons
- Regulate the composition of the interstitial fluid surrounding neurons

Module 4.17: Review

A. Which type of muscle tissue regulates blood vessel diameter?
B. Distinguish between neurons and neuroglia.
C. Organs are made up of different tissues. What tissues are found in skeletal muscles?

Learning Outcome: Specify the functions of muscle tissue and nervous tissue.

Module 4.18: CLINICAL MODULE: The response to tissue injury involves inflammation and regeneration

Tissues respond in a coordinated way to restore homeostasis

Two restoration processes

- Inflammation
- Regeneration

Module 4.18: CLINICAL MODULE: Responses to tissue injury

Injury occurs

- Body is exposed to pathogens and toxins and chemicals from injured cells
- Body activates defense mechanisms including:
  - **Mast cell activation**
    - Mast cells release histamine and other chemicals
    - Stimulates **inflammation**

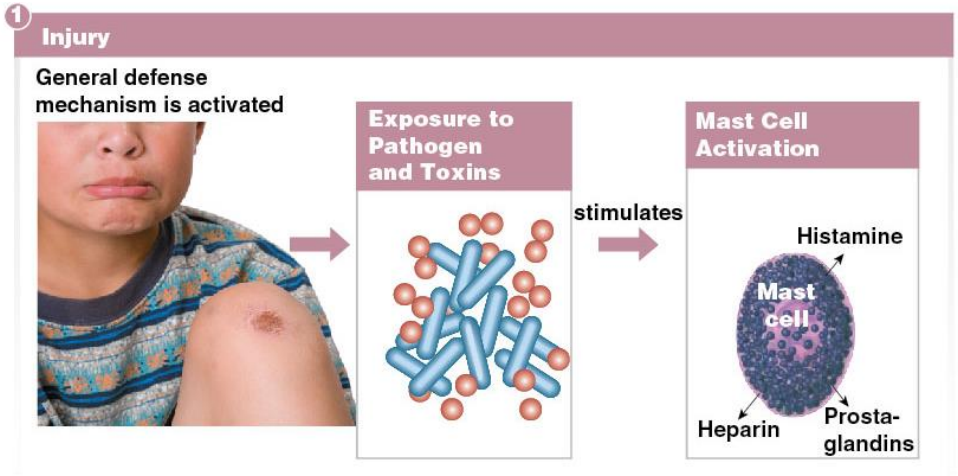

Module 4.18: CLINICAL MODULE: Responses to tissue injury

Inflammation

- Produces indications of injury
  1. Swelling
  2. Redness
  3. Warmth
  4. Pain
- May result from injury or from **infection** (presence of pathogens within the tissue)
- Occurs in connective tissue, so may occur anywhere in the body (as all organs contain connective tissue)

Module 4.18: CLINICAL MODULE: Responses to tissue injury

Inflammation (continued)

- **Dilates** (enlarges) blood vessels
- Increases blood vessel permeability
- Increased blood flow to the area causes:
  - Swelling in the area
  - Increased local temperature
  - Increased delivery of oxygen and nutrients
  - Increased removal of toxins and wastes
- Stimulates increased phagocytosis in tissues
- Sensation of pain from abnormal conditions and chemicals released by mast cells

Inflammation

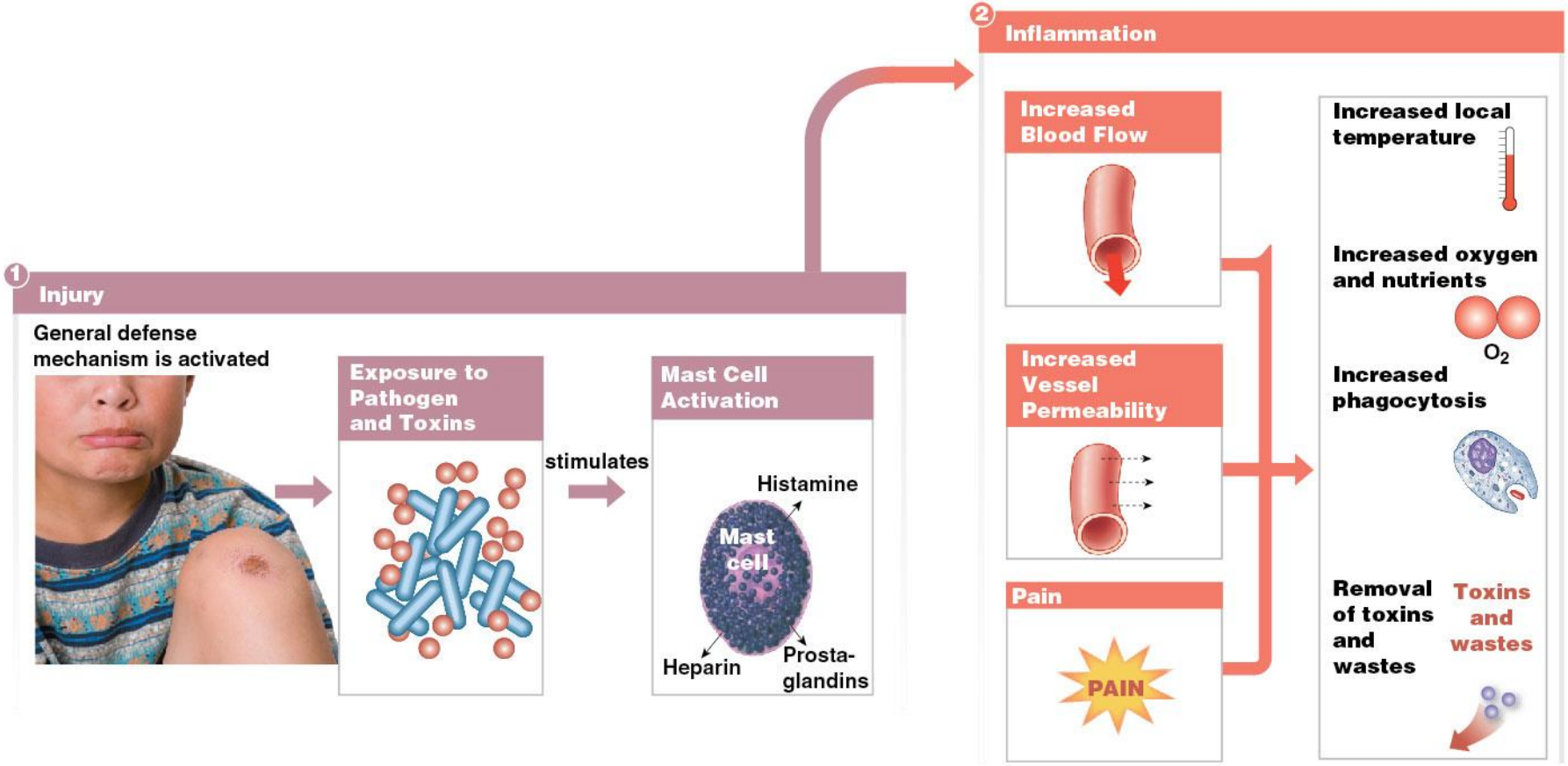

Module 4.18: CLINICAL MODULE: Responses to tissue injury

Cleanup process (removing toxins and wastes) usually eliminates inflammatory stimuli in hours to days

Regeneration

- Occurs after damaged tissue has stabilized
- Fibroblasts produce collagen fibers to stabilize injury site
- Produces dense, collagenous framework called **scar tissue**
- Scar tissue usually remodeled and normal tissue conditions restored

Module 4.18: CLINICAL MODULE: Responses to tissue injury

Each tissue has a different ability to regenerate

- Epithelial, connective (except cartilage), and smooth muscle regenerate well
- Other muscle types and neural tissue regenerate poorly, if at all
- In tissues that regenerate poorly, scar tissue replaces tissues that do not regenerate
  - **Fibrosis** is the permanent replacement of normal tissue by scar tissue

Module 4.18: CLINICAL MODULE: Responses to tissue injury

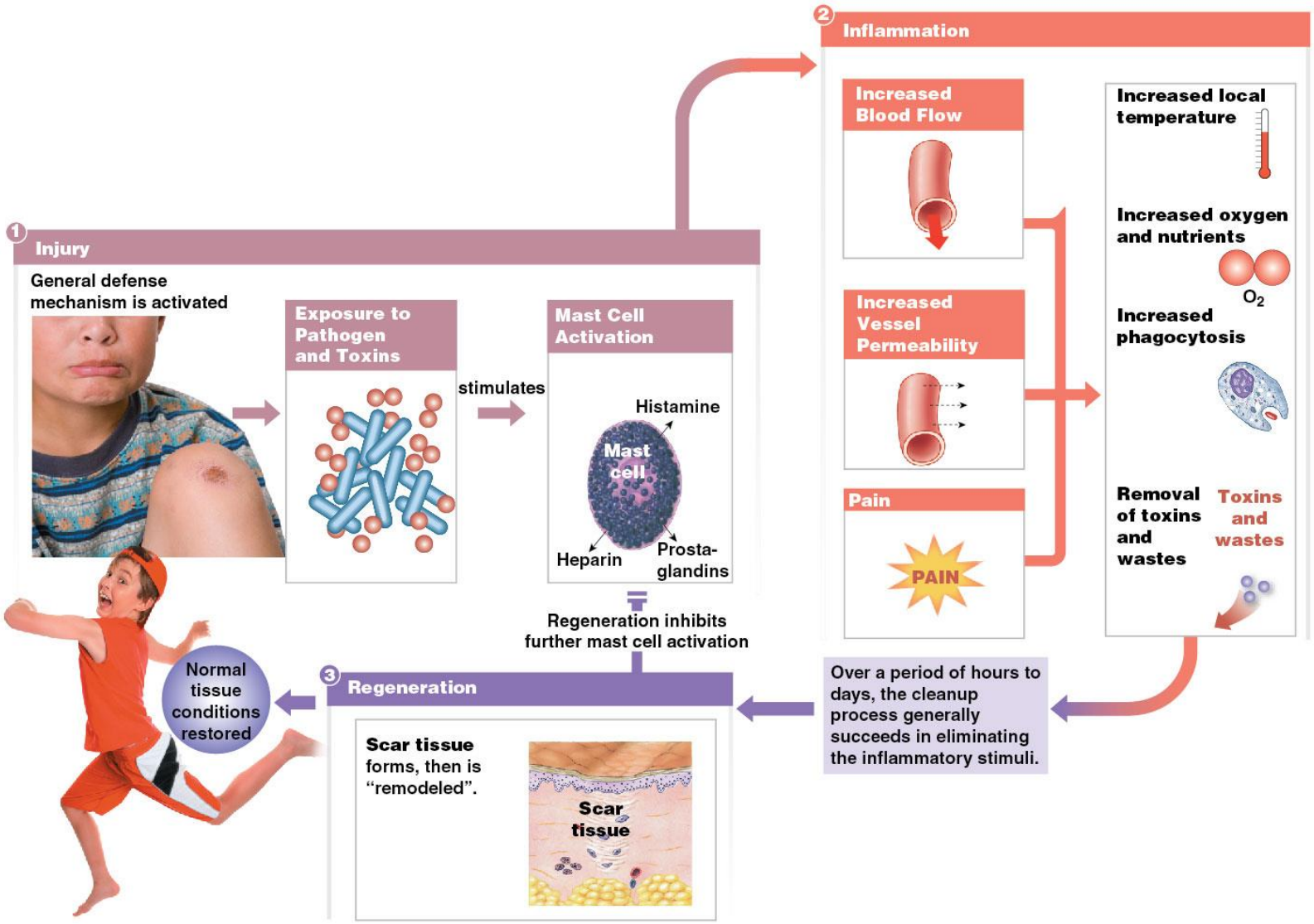

Module 4.18: Review

A. Identify the two processes in the response to tissue injury.
B. What are the four indications of inflammation that occur following an injury?
C. Why can inflammation occur in any organ in the body?

Learning Outcome: Describe the roles of inflammation and regeneration in response to tissue injury.